JSMC Clinical Case Reports

Case Report

When Dermoscopy Corrects the Diagnosis!

Younes Barbach*, Hanane Baybay, Mohammed Chaouche, Abdellah Dah Cherif, Sara Elloudi, and Fatima Zahra Mernissi

Department of Dermatology, University Hospital Hassan II, Morocco

Abstract

Background: The dermoscope is the main tool of any dermatologist, it is a non-invasive method that allows in some cases to evoke or confirm a diagnosis, to orient the skin biopsy and choose the right site. And in other cases, it helps to correct a wrong diagnosis!

Case report : We report a case of a 60 years old patient, referred to our department for the management of a Merkel cell carcinoma, but the diagnosis was rectified thanks to the dermoscopy, which was in favor of cutaneous metastasis of a melanoma and contributed to adequate management.

Discussion : Dermoscopy has become an integral part of the clinical examination of cutaneous tumors. Different dermoscopic patterns can be seen in the case of cutaneous metastasis of a melanoma, especially the polymorphic pattern found in our patient, which allowed us to rediscuss the already pre-established diagnosis and ask for another histological report, which confirmed our suspected diagnosis.

Keywords: Dermoscopy; cutaneous metastasis; melanoma; correct; diagnosis

Introduction

The dermoscope is the main tool of any dermatologist, it is a non-invasive method that allows in some cases to evoke or confirm a diagnosis, to orient the skin biopsy and choose the right site. And in other case, it helps to correct a wrong diagnosis!

Case Report

We report the case of a 60-year-old patient with no significant pathological history, who was referred to our department for the treatment of histologically proven Merkel cell carcinoma with immunohistochemical study. It has been evolving progressively over 1 year. The clinical examination found several pigmented nodules and tumors of various sizes diffused throughout the body (Figure 1,2), as well as in the soft palate in the mucosal cavity, bleeding on contact, slightly infiltrated, mobile, with a halo nevus on the back (Figure 3). The somatic examination revealed the presence of several bony masses on the anterior surface of the 2 legs and the left parietal area, also a cervical lymphadenopathy. Dermoscopy of the skin lesions showed the presence of a blotch, a blue-gray veil, irregular linear vessels, telangiectatic vessels, hemorrhagic ulceration, and a rainbow pattern (Figure 4,5).

According to clinical and dermoscopic data, the diagnosis of cutaneous metastasis of a melanoma was suspect first, also a Kaposi sarcoma, cutaneous metastasis of a hepatic or renal tumor, an angiosarcoma and lastly a Merkel cell carcinoma. The decision was to perform an other biopsy with immunohistochemical study, which confirmed the diagnosis of cutaneous metastasis of a melanoma (Figure 6,7).

Discussion

Dermoscopy has become an integral part of the clinical examination of cutaneous tumors, not only because it significantly establishes early diagnosis of melanocytic and non- melanocytic skin cancers, including basal cell carcinoma and squamous cell carcinoma compared clinical examination, but also finds its interest in the management of these tumors [1].

Merkel cell carcinoma (MCC) is a rare but aggressive cutaneous neuroendocrine tumor [2]. It usually presents with an asymptomatic nodule,with rapid growth. Dermoscopy is likely to be a useful diagnostic tool, but few reports have been published [3]. This tumor has ove lapping features with other skin tumors.

Figure 1,2 Diffuses several pigmented nodules and tumors, with bony masses on the legs.

Submitted: 01 April, 2019 | **Accepted:** 21 April, 2019 | **Published:** 23 April, 2019

***Corresponding author:** Younes Barbach, Department of Dermatology, University Hospital Hassan II, Morocco, Email: dr.younes2011@gmail.com

Citation: Barbach Y, Baybay H, Chaouche M, Dah Cherif A, Elloudi S, et al. (2019) When Dermoscopy Corrects the Diagnosis!. JSMC Clin Case Rep 4: 3.

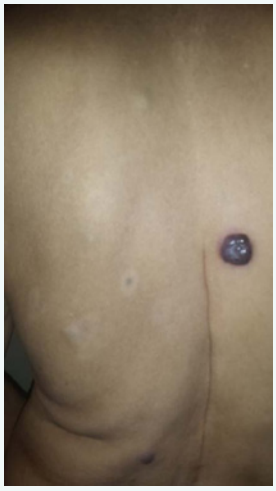

Figure 3 Halo naevus on the back.

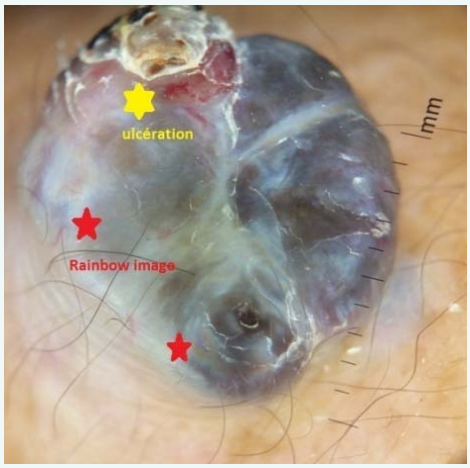

Figure 4 Dermoscopy of skin lesions showing a polymorphic pattern.

The combination of polymorphic vessels and milky red areas suggests achromic melanoma, whereas isolated milky red areas can be observed in the pyogenic granuloma and the arboreal vessels are typical of basal cell carcinoma. The combination of these structures could also suggest cutaneous metastasis. Nevertheless, other more distinctive features, such as linear vessels and bright white areas, have been noted in this tumor [2,4].

Cutaneous melanoma is the most aggressive and metastatic form of skin cancer. Although it constitutes only under 5% of skin cancers, it is responsible for nearly 60% of deaths [5]. About 16.5% of patients with primary melanoma develop in-transit metastasis, regional or distant. The clinical and histological features of primary lesions are not predictive of metastatic models.

Melanoma is the second cancer responsible for the development of cutaneous metastasis after breast cancer [6]. In 2-8% of patients with melanoma, the first clinical manifestation of the disease may be cutaneous metastasis.

The dermatologist's approach to cutaneous metastasis of melanoma is based on the knowledge of the clinical and dermoscopic data of these lesions. Metastatic melanoma can imitate benign lesions, which has an impact on the prognosis and the choice of therapy depending on the staging. Much data is available on the different dermoscopic patterns of skin tumors,

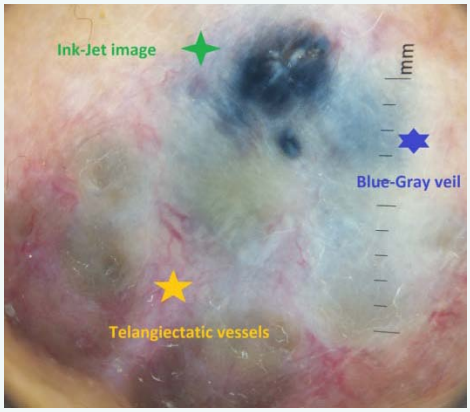

Figure 5 Dermoscopy of skin lesions showing a polymorphic pattern.

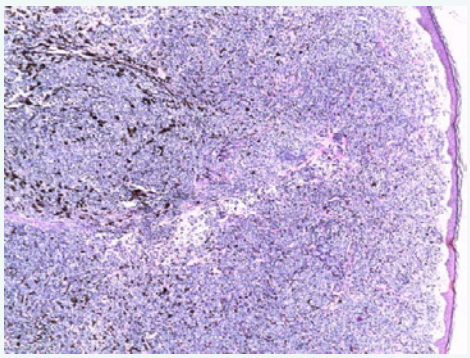

Figure 6 HES G x 50 staining - Diffuse pigmented proliferation of the dermis, normal epidermis.

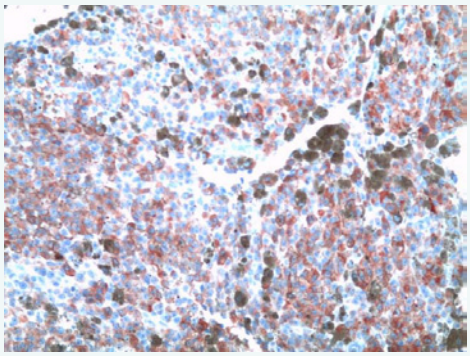

Figure 7 IHC G x 200 - Melan A (+).

but few describe CMM patterns [7-9]. For this reason, an update was established to describe the different dermoscopic patterns of cutaneous metastatic melanoma, including a homogeneous pattern showing the presence of a uniform diffuse pigmentation (red, brown, gray, or greyish black) without no other structures [9], a saccular pattern, resulting from oval junctional nests containing melanocytic cells. The color variations of this model depend on the amount of neovascularization and melanin pigment, mainly bluish red, pale brownish red, brownish or greyish red, and blue-gray [10], a vascular pattern showing features related to the thickness of the tumor, indeed, punctuated vessels predominate in thin lesions and those in corkscrew in thick ones [10], a polymorphic pattern where the distribution of structures and dermoscopic colors within the lesion is heterogeneous [9] different signs can be found such as the blotch image , the rainbow pattern, the veil, the polymorphous vascularization. This last pattern can be confused with several skin tumors, given the wide variety of dermoscopic structures, as observed in our patient. Dermoscopy can establish the diagnosis with certainty in some tumors, in other cases, it can orient it and the histology remains the gold standard.

Conclusion

Thanks to the dermoscopy, it was possible to correct the diagnosis of our patient, and thus contribute to an adequate and targeted management.

References

1. Lallas A, Argenziano G, Zendri E, Moscarella E, Longo C, Grenzi L, et al. Update on non-melanoma skin cancer and the value of dermoscopy in its diagnosis and treatment monitoring. Expert Rev Anticancer Ther. 2013; 13: 541-558.
2. Dalle S, Parmentier L, Moscarella E, Phan A, Argenziano G, Thomas L. Dermoscopy of Merkel cell carcinoma. Dermatol Basel Switz. 2012; 224: 140-144.
3. Scalvenzi M, Palmisano F, Ilardi G, Varricchio S, Costa C. Clinical, dermoscopic and histological features of a Merkel cell carcinoma of the hand. J Dermatol Case Rep. 2013; 7: 15-17.
4. Harting MS, Ludgate MW, Fullen DR, Johnson TM, Bichakjian CK. Dermatoscopic vascular patterns in cutaneous Merkel cell carcinoma. J Am Acad Dermatol. 2012; 66: 923-927.
5. Garbe C, Leiter U. Melanoma epidemiology and trends. Clin Dermatol. 2009; 27: 3-9.
6. Savoia P, Fava P, Nardò T, Osella-Abate S, Quaglino P, Bernengo MG. Skin metastases of malignant melanoma: a clinical and prognostic survey. Melanoma Res. 2009; 19: 321-326.
7. Jaimes N, Halpern JA, Puig S, Malvehy J, Myskowski PL, Braun RP, et al. Dermoscopy: an aid to the detection of amelanotic cutaneous melanoma metastases. Dermatol Surg Off Publ Am Soc Dermatol Surg Al. 2012; 38: 1437-1444.
8. Schulz H. Epiluminescence microscopy features of cutaneous malignant melanoma metastases. Melanoma Res. 2000; 10: 273-280.
9. Bono R, Giampetruzzi AR, Concolino F, Puddu P, Scoppola A, Sera F, et al. Dermoscopic patterns of cutaneous melanoma metastases. Melanoma Res. 2004; 14: 367-373.
10. Rubegni P, Lamberti A, Mandato F, Perotti R, Fimiani M. Dermoscopic patterns of cutaneous melanoma metastases. Int J Dermatol. 2014; 53: 404-412.