

# Decision Making in the Treatment of Anteroinferior Shoulder Instability - Clinical and Radiological Variables

Matthew C Evans<sup>1,2\*</sup>, Adrian K Schneider<sup>3</sup>, Gregory A Hoy<sup>1,2</sup> and David Mc D Taylor<sup>4</sup>

<sup>1</sup>Melbourne Orthopaedic Group, Upper Limb Unit, Australia

<sup>2</sup>Monash University, Department of Surgery, Australia

<sup>3</sup>Kantonsspital, Department of Orthopaedic Surgery and Traumatology, Switzerland

<sup>4</sup>Austin Hospital, Emergency Department, Australia

## Article Information

Received date: Jul 27, 2017

Accepted date: Aug 22, 2017

Published date: Aug 24, 2017

### \*Corresponding author

Matthew C Evans, Melbourne Orthopaedic Group, Upper Limb Unit, Windsor; Monash University, Department of Surgery, Clayton, Australia, Email: mevans@mog.com.au

**Distributed under** Creative Commons CC-BY 4.0

**Keywords** Shoulder; Instability; Anteroinferior Bone Loss; Glenoid Track; Hill-Sachs Defect; Bankart

## Abstract

**Purpose:** To determine the clinical and radiological variables that are associated with the undertaking of the Latarjet procedure, rather than a Bankart procedure, for anteroinferior shoulder instability.

**Methods:** Clinical and radiological (CT scan) data was evaluated retrospectively, on a cohort of 66 patients who had undergone surgery for recurrent anteroinferior, glenohumeral instability.

Odds ratios (95% confidence intervals) were calculated for each variable to determine its association with performance of the Latarjet procedure as opposed to an arthroscopic soft-tissue reconstruction.

**Results:** Linear glenoid bone loss and ipsilateral, previous stabilization surgery were the two variables demonstrated to be associated with a significantly higher likelihood of the patient undergoing a Latarjet procedure.

Age at surgery, treating surgeon, and sports involvement were not associated with an increased likelihood of the patient undergoing a Latarjet procedure.

**Conclusion:** None of the clinical parameters analyzed demonstrated an association with an increased likelihood of undergoing a Latarjet procedure for anteroinferior shoulder instability.

Consistent with the published literature, we identified 19% linear glenoid bone loss as our cut-off for undertaking a Latarjet procedure for anteroinferior shoulder instability.

**Level of evidence:** IV

## Introduction

The aetiology of anteroinferior Instability of the shoulder is multi-factorial. There are patient related factors and structural factors. Young age, generalized ligament laxity, male gender, and participation in contact and overhead sport are considered as risk factors for shoulder instability. A history of instability is also considered predictive of further instability episodes [1,2]. This is thought to be contributed to by the structural damage caused by the first instability episode. Along with damage to the anterior joint capsule and labrum, bipolar bone loss is now well recognized as a cause for recurrent, anteroinferior shoulder instability [3-9].

Following the adoption of arthroscopic soft tissue shoulder reconstruction as the standard of care for antero-inferior instability, it became evident that there was a rate of failure for this operation, with recurrence of instability. Several authors have studied this population group extensively in an effort to identify those patients for whom a soft tissue reconstruction may not be sufficient to confer stability [8,10-12]. Bone loss on the glenoid side has been well described, either as a result of fracture at the time of dislocation, or due to erosion from recurrent instability episodes [12-16]. Bony lesions on the humeral side have proved more difficult to both quantify and to treat [17-22]. Balg and Boileau published the Instability Severity Index Score (ISIS) [1] in an attempt to incorporate both patient and structural factors related to anteroinferior instability, in order to guide treatment.

An elegant description of bipolar bone loss that incorporates changes on both the glenoid and humeral sides, and their interactions with motion, has been proposed by Yamamoto [6]. This 'Glenoid Track' theory is complimentary to Burkhart's 'engaging Hill-Sachs' concept [12], in recognizing the interplay between bone lesions on both sides of the joint as the arm is taken into abduction and external rotation. A new treatment paradigm has been published by Di Giacomo, Itoi and Burkhart [3], based solely upon measurements incorporating glenoid bone loss and the relationship of the humeral lesion to the 'glenoid track', utilizing CT scans with 3D reconstructions.

Surgical treatment options for anteroinferior instability include both soft tissue and bony procedures, either alone or in combination. An arthroscopic Bankart procedure is utilized to address the soft tissue deficit anteriorly, whilst a Latarjet (or similar) procedure is designed to address glenoid or combined bone loss. For the Hill-Sachs defect, a variety of options is available, with soft tissue remplissage [21] or bone grafting [23] most commonly reported. The question remains as to which variables are most important in the treatment decision making process [24,25].

The hypothesis underpinning this study was that decision making in the treatment of anteroinferior instability requires consideration not only of bone loss parameters, but also of clinical or patient related factors. It was our presumption that for a population of young, athletic patients, participating in overhead and contact sports, the threshold to perform a Latarjet procedure combined with Bankart repair would be lower than those using bone parameters alone.

The aim of this study was to determine the clinical and radiological variables that are associated with the undertaking of the Latarjet procedure, rather than a Bankart procedure, for anteroinferior shoulder Instability.

**Methods (This was a retrospective cohort study)**

Patients were included in the study if they had anteroinferior glenohumeral Instability and had undergone either an arthroscopic Bankart reconstruction or an open Latarjet reconstruction (combined

with capsular repair) by one of 2 surgeons at the Melbourne Orthopaedic Group (ME or GH). All patients had undergone a preoperative CT scan with 3D reconstruction at Victoria House Medical Imaging from January 2012 to October 2015.

Patients were excluded if they had multidirectional instability, bilateral traumatic instability or previous surgery other than an arthroscopic Bankart repair.

Data including patient age at the time of surgery, treating surgeon, and procedure performed were extracted from the patient file. Sporting parameters including; level of sport (recreational=0, amateur competitive=1, professional=2); nature of the sport (non-contact=0, contact=1); and upper limb involvement (below head = 0, overhead) were recorded. The point system utilized by Balg and Boileau [1] was applied to these parameters, to facilitate statistical analysis. An overall sport score was derived from the summation of points from each of the 3 sporting parameters (possible score 0-4), and then stratified into low (score of 0), medium (score 1-2) and high (score 3-4) for statistical evaluation. Additionally, the incidence and nature of any previous surgery to the ipsilateral shoulder was recorded. Patients with previous soft-tissue surgery (Bankart procedure) were included in the study to determine this as a predictor of future treatment.

Radiological evaluation was undertaken by the treating surgeon utilizing CT scans with 3D reconstructions of both shoulders. Measurements of linear glenoid bone loss were recorded, along with an evaluation of the glenoid-track and its relation to the Hill-Sachs defect, according to the method described by Di Giacomo [3] and

**Table 1:** Measurement parameters and their Odds Ratios.

Metric	Scale	Arthroscopic (n=31)	Latarjet (n=35)	Odds Ratio (CI)	P value
Age at Surgery (years)	16-20	10	8	1*	-
	21-25	9	9	1.25 (0.34, 4.64)	0.74
	26-30	6	10	2.08 (0.53, 8.23)	0.29
	31+	6	8	1.67 (0.41, 6.82)	0.48
Treating Surgeon	ME	14	8	1*	-
	GH	17	27	2.78 (0.96, 8.02)	0.06
Level of sport	recreational	19	16	1*	-
	amateur	10	17	2.02 (0.72, 5.63)	0.18
	professional	2	2	1.19 (0.15, 9.41)	0.87
Contact sport played	no	21	20	1*	-
	yes	10	15	1.58 (0.58, 4.31)	0.38
Overhead sport played	no	21	16	1*	-
	yes	10	19	2.49 (0.91, 6.81)	0.07
Sport Score (0-4)	0	15	10	1*	-
	1-2	11	13	1.77 (0.57, 5.51)	0.32
	3-4	5	12	3.60 (0.97, 13.4)	0.05
Surgery	primary	27	17	1*	-
	revision	4	18	7.15 (2.06, 24.74)	<0.001
Glenoid bone loss (%)	0-9	22	10	1*	-
	10-14	5	7	3.08 (0.78, 12.12)	0.1
	15-19	2	4	4.40 (0.69, 28.12)	0.1
	20-24	1	7	15.40 (1.66, 142.46)	<0.01
	25+	1	7	15.40 (1.66, 142.46)	<0.01

\*reference group against which other groups are compared.

colleagues. This analysis was undertaken in concert with an evaluation of the intra- and Inter-observer reliability of these measurements as a separate study [26].

Odds ratios (95% confidence intervals) were calculated for each variable to determine its association with performance of the Latarjet procedure as opposed to an arthroscopic soft-tissue reconstruction. EpiCalc (Version 1.02; 2000. Brixton Books, UK) was employed for all analyses. The level of significance was 0.05.

Ethical approval for this study was obtained from our institutions' Human Research Ethics Committee (project 189).

## Results

A total of 66 patients were identified to have undergone CT scanning with 3D reconstructions (using a standardized CT protocol) as part of their pre-operative assessment for anteroinferior shoulder instability.

31 patients underwent an arthroscopic Bankart reconstruction, whilst 35 underwent an open Latarjet procedure combined with capsular repair Bankart reconstruction. Hill-Sachs remplissage was performed on two patients in the arthroscopic Bankart group.

The associations between the variables under investigation and the performance of the Latarjet procedure are described in the (Table 1), with Odds Ratios and P-values listed. Most patients were young and were involved in recreational or amateur sport.

Linear glenoid bone loss >19% as measured by CT was associated with a significantly higher likelihood of the patient undergoing a Latarjet procedure (Figure 1). Patients who had had previous ipsilateral stabilization surgery were 7.2 times more likely to undergo a Latarjet procedure (OR 7.2 95% CI 2.1, 24.7,  $p < 0.001$ ).

Age at surgery, treating surgeon, and sports involvement were not associated with an increased likelihood of the patient undergoing a Latarjet procedure. Although stratification of the sports score demonstrated that for patients in the high level group (score 3-4), the OR of 3.60 approached significance with  $p = 0.051$ , there was no difference in the treatment regardless of level of sport, whether the sport involved contact/collision activity, or whether the sport involved predominantly overhead activity. Most patients were young and were involved in recreational or amateur sport.

Glenoid Track and Hill-Sachs measurements were taken but on inter- and intra- observer reliability testing, evaluation of whether the

Hill-Sachs lesion was 'on-track' or 'off-track' demonstrated a high level of variability (CoV 19.2), and was deemed unreliable [26]. For this reason, humeral bone lesions were not evaluated with reference to the decision making process.

## Discussion

Inconsistent with our hypothesis, we have demonstrated that previous ipsilateral shoulder surgery was the only clinical parameter that statistically influenced our decision making. Although high level sports involvement approached significance this association could not be demonstrated in our cohort. With regard to the CT based evaluation of bone loss, our threshold for undertaking a Latarjet procedure combined with Bankart repair fell within the generally accepted figure of 20% linear bone loss [10,12,19,27].

Bone loss and its contribution to the failure of soft-tissue stabilization surgery for anteroinferior shoulder instability had been the subject of much research and literature over the past decade. Glenoid bone loss is well accepted as a contributor to recurrent instability, although measurement techniques and levels of significance with regard to the amount of bone loss vary. Linear glenoid bone loss measured arthroscopically [27] was initially considered the gold standard, but CT scanning with 3D reconstruction now appears both reliable and reproducible in accurately determining this metric [4,28-30]. Some authors prefer surface area measurements, and again CT is the preferred investigation from which to make these measurements [31-33]. The point at which glenoid bone loss becomes relevant in decision making regarding management varies amongst different authors, but a range from 15-25% is described [10,12,19,27,34,35].

The Hill-Sachs defect has been much harder to quantify, and its significance has been difficult to assess [17,18,20, 24,36]. Yamamoto's Glenoid-track theory [6] and Burkhart's engaging Hill-Sachs concept have recently been combined and a treatment algorithm derived, based solely on radiological measurements [3].

This study has a number of important limitations. The number of patients included was determined by the availability of standardized CT scans for each patient, and this precluded multivariate regression analysis. In addition to the parameters analyzed, we would have liked to assess for generalized ligament laxity and for plain X-ray appearances as described by Balg and Boileau as part of the ISIS score. Unfortunately, these data were not available for all patients and were therefore not assessed.

It is implied in this study that the treatment decision made by the treating surgeons was appropriate. Although there have been no reports of recurrent instability in this cohort, the length of follow-up is currently insufficient to be conclusive as to the outcome. It is our intention to monitor and report the clinical outcomes of this patient cohort at minimum 5 years follow-up. This study represents the treatments applied by 2 surgeons, and therefore may lack external validity. We hope that this pilot study may be repeated with a larger patient cohort and a larger number of treating surgeons to make it more generalisable.

## Conclusions

The results of study indicate that previous ipsilateral shoulder surgery and linear glenoid bone loss were the two independent variables associated with the decision to perform a Latarjet procedure.

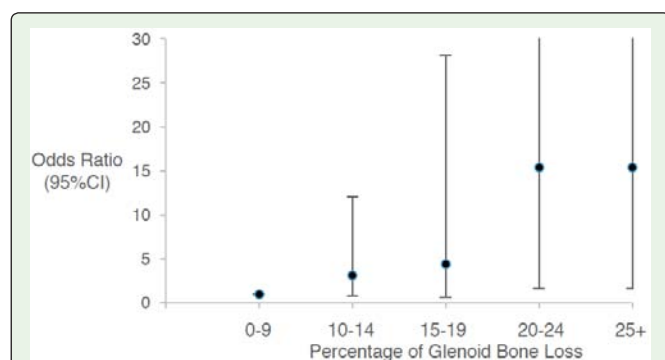


Figure 1: Odds Ratio for Latarjet procedure as a function of the percentage of glenoid bone loss.

Other variables, including age and various sporting parameters, were not associated with the performance of a Latarjet procedure.

Consistent with the published literature, we identified 19% as our cut-off for undertaking a Latarjet procedure in addition to the Bankart repair.

## References

- Balg F, Boileau P. The instability severity index score: A simple pre-operative score to select patients for arthroscopic or open shoulder stabilisation. *J Bone Jt Surg Br.* 2007; 89: 1470-1477.
- Milano G, Grasso A, Russo A, Magarelli N, Santagada D, Deriu L, et al. Analysis of risk factors for glenoid bone defect in anterior shoulder instability. *Am J Sports Med.* 2011; 39: 1870-1876.
- Di Giacomo G, Itoi E, Burkhart SS. Evolving Concept of Bipolar Bone Loss and the Hill-Sachs Lesion: From "Engaging/Non-Engaging" Lesion to "On-Track/Off-Track" Lesion. *Arthrosc J Arthrosc Relat Surg.* 2014; 30: 90-98.
- Trivedi S, Pomerantz ML, Gross D, Golijanan P, Provencher MT. Shoulder Instability in the Setting of Bipolar (Glenoid and Humeral Head) Bone Loss: The Glenoid Track Concept. *Clin Orthop Relat Res.* 2014; 472: 2352-2362.
- Metzger PD, Barlow B, Leonardelli D, Peace W, Solomon DJ, Provencher MT. Clinical Application of the "Glenoid Track" Concept for Defining Humeral Head Engagement in Anterior Shoulder Instability: A Preliminary Report. *Orthop J Sport Med* 2013; 1.
- Yamamoto N, Itoi E, Abe H, Minagawa H, Seki N, Shimada Y, et al. Contact between the glenoid and the humeral head in abduction, external rotation, and horizontal extension: A new concept of glenoid track. *J Shoulder Elb Surg* 2007; 16: 649-656.
- Di Giacomo G, De Vita A, Costantini A, de Gasperis N, Scarso P. Management of humeral head deficiencies and glenoid track. *Curr Rev Musculoskelet Med.* 2014; 7: 6-11.
- Arciero R, Parrino A, Bernhardson AS, Diaz-Doran V, Obopilwe E, Cote MP, et al. The Effect of a Combined Glenoid and Hill-Sachs Defect on Glenohumeral Stability: A Biomechanical Cadaveric Study Using 3-Dimensional Modeling of 142 Patients. *Am J Sports Med.* 2015.
- Omori Y, Yamamoto N, Koishi H, Futai K, Goto A, Sugamoto K, et al. Measurement of the Glenoid Track In Vivo as Investigated by 3-Dimensional Motion Analysis Using Open MRI. *Am J Sports Med.* 2014; 42: 1290-1295.
- Lo IKY, Parten PM, Burkhart SS. The Inverted Pear Glenoid: An Indicator of Significant Glenoid Bone Loss. *Arthrosc - J Arthrosc Relat Surg.* 2004; 20: 169-174.
- Tauber M, Resch H, Forstner R, Raffl M, Schauer J. Reasons for failure after surgical repair of anterior shoulder instability. *J Shoulder Elb Surg.* 2004; 13: 279-285.
- Burkhart SS, De Beer JF. Traumatic glenohumeral bone defects and their relationship to failure of arthroscopic Bankart repairs. *Arthrosc J Arthrosc Relat Surg.* 2000; 16: 677-694.
- Sugaya H, Moriishi J, Dohi M, Kon Y, Tsuchiya A. Glenoid rim morphology in recurrent anterior glenohumeral instability. *J Bone Joint Surg Am.* 2003; 85-A: 878-884.
- Sugaya H. Techniques to evaluate glenoid bone loss. *Curr Rev Musculoskelet Med.* 2014; 7: 1-5.
- Moroder P, Ernstbrunner L, Pomwenger W, Oberhauser F, Hitzl W, Tauber M, et al. Anterior Shoulder Instability Is Associated With an Underlying Deficiency of the Bony Glenoid Concavity. *Arthrosc J Arthrosc Relat Surg* 2015; 31: 1223-1231.
- Saito H, Itoi E, Sugaya H, Minagawa H, Yamamoto N, Tuoheti Y. Location of the Glenoid Defect in Shoulders With Recurrent Anterior Dislocation. *Am J Sports Med.* 2005; 33: 889-893.
- Saliken DJ, Bornes TD, Bouliane MJ, Sheps DM, Beaupre L. Imaging methods for quantifying glenoid and Hill-Sachs bone loss in traumatic instability of the shoulder: a scoping review. *BMC Musculoskelet Disord.* 2015; 16: 164.
- Kurokawa D, Yamamoto N, Nagamoto H, Omori Y, Tanaka M, Sano H, et al. The prevalence of a large Hill-Sachs lesion that needs to be treated. *J Shoulder Elb Surg.* 2013; 22: 1285-1289.
- Itoi E, Yamamoto N, Kurokawa D, Sano H. Bone loss in anterior instability. *Curr Rev Musculoskelet Med.* 2013; 6: 88-94.
- Skendzel JG, Sekiya JK. Diagnosis and management of humeral head bone loss in shoulder instability. *Am J Sports Med.* 2012; 40: 2633-2644.
- Purchase RJ, Wolf EM, Hobgood ER, Pollock ME, Smalley CC. Hill-Sachs "Remplissage": An Arthroscopic Solution for the Engaging Hill-Sachs Lesion. *Arthrosc - J Arthrosc Relat Surg.* 2008; 24: 723-726.
- Buza John A III, Iyengar JJ, Anakwenze OA, Ahmad CS, Levine WN. Arthroscopic Hill-Sachs Remplissage. *J Bone Jt Surg.* 2014; 96: 549-555.
- Miniaci A, Gish MW. Management of anterior glenohumeral instability associated with large Hill-Sachs defects. *Tech Shoulder Elb Surg.* 2004; 5: 170-175.
- Lynch JR, Clinton JM, Dewing CB, Warne WJ, Matsen F. Treatment of osseous defects associated with anterior shoulder instability. *J Shoulder Elb Surg.* 2009; 18: 317-328.
- Provencher MT, Frank RM, LeClere LE, Metzger PD, Ryu JJ, Bernhardson, et al. The Hill-Sachs Lesion: Diagnosis, Classification, and Management. *J Am Acad Orthop Surg.* 2012; 20: 242-252.
- Schneider AK, Hoy GA, Ek ET, Rotstein AH, Tate J, Taylor DM, et al. Interobserver and intraobserver variability of glenoid track measurements. *J Shoulder Elb Surg.* 2017; 573-579.
- Burkhart SS, DeBeer JF, Tehrany AM, Parten PM. Quantifying glenoid bone loss arthroscopically in shoulder instability. *Arthroscopy.* 2002; 18: 488-491.
- Bakshi NK, Patel I, Jacobson JA, Debski RE, Sekiya JK. Comparison of 3-Dimensional Computed Tomography-Based Measurement of Glenoid Bone Loss with Arthroscopic Defect Size Estimation in Patients with Anterior Shoulder Instability. *Arthrosc J Arthrosc Relat Surg.* 2015; 31: 1880-1885.
- Bishop JY, Jones GL, Rerko M, Donaldson C. 3-D CT is the most reliable imaging modality when quantifying glenoid bone loss shoulder. *Clin Orthop Relat Res.* 2013; 471: 1251-1256.
- Nofsinger C, Browning B, Burkhart SS, Pedowitz R. Objective Preoperative Measurement of Anterior Glenoid Bone Loss: A Pilot Study of a Computer-Based Method Using Unilateral 3-Dimensional Computed Tomography. *Arthrosc J Arthrosc Relat Surg.* 2011; 27: 322-329.
- Barchilon VS, Kotz E, Barchilon Ben-Av M, Glazer E, Nyska M. A simple method for quantitative evaluation of the missing area of the anterior glenoid in anterior instability of the glenohumeral joint. *Skeletal Radiol.* 2008; 37: 731-736.
- Provencher CDRMT, Bhatia S, Ghodadra NS, Grumet RC, Bach BR, Dewing LCB, et al. Recurrent Shoulder Instability: Current Concepts for Evaluation and Management of Glenoid Bone Loss. *J Bone Jt Surg Am.* 2010; 92: 133-151.
- Baudi P, Righi P, Bolognesi D, Rivetta S, Rossi Urtoler E, Guicciardi N, et al. How to identify and calculate glenoid bone deficit. *Chir Organi Mov.* 2005; 90: 145-152.
- Bigliani LU, Newton PM, Steinmann SP, Connor PM, McIlveen SJ. Glenoid rim lesions associated with recurrent anterior dislocation of the shoulder. *Am J Sports Med.* 1998; 26: 41-45.
- Itoi E, Lee SB, Berglund LJ, Berge LL, Nan KN. The Effect of a Glenoid Defect on Anterior Inferior Stability of the Shoulder after Bankart Repair: A Cadaveric Study. *J Bone Jt Surg Am.* 2000; 82: 35-46.
- Garcia GH, Joseph NL, David MD, Joshua SD. Effect of bone loss in anterior shoulder instability. *World J Orthop.* 2015; 6: 421.