

Rapid Palatal Expansion: Does it affect  
the Appearance of the Face?

Maria Chatzoudi\*

Orthodontist at private practice, Greece

## Article Information

Received date: Jul 21, 2015  
Accepted date: Sep 20, 2015  
Published date: Oct 08, 2015

## \*Corresponding author

Maria Chatzoudi, Private orthodontic practice (Kalamria's Orthodontic Practice), Greece, Tel: +302310029405 ; Email: maria@orthodontist-kalamaria.gr

Distributed under Creative Commons  
CC-BY 4.0

**Keywords** Lateral subtalar joint;  
Dislocation; Tibialis posterior tendon,  
Rupture

## Abstract

Rapid Palatal Expansion (RPE) is a traditional orthodontic/orthopedic procedure for the skeletal widening of the maxilla according to which the two maxillary bones tear apart and the gap between them is filled in with hemorrhagic tissue which is gradually replaced by new bone formation. Indications for RPE are severe absolute or relative skeletal discrepancies with the maxilla being narrower than normal. This procedure seems to be accompanied by concomitant skeletal changes.

A prospective control clinical trial was designed in an effort to verify these alterations. A treated sample and a control sample consisted of 23 individuals each. The age of the examined patients was 14-16 years. The patients of the treated sample underwent RPE whereas in the control sample they received no treatment at all. Measurements were made before treatment (T<sub>0</sub>), after RPE and 3 months retention with the appliance still in place (T<sub>1</sub>) and at the end of the orthodontic treatment (T<sub>2</sub>). Equivalent measurements were made in the control group as well. The variables measured were the lips length, the width of the base of the nose and the Soft Tissue Lower Anterior Face Height (SLAFH).

According to the results of this study, no statistically significant alteration found in the length of the lips due to the RPE procedure. On the contrary, the base of the nose presented statistically significant increase. The SALFH also increased with statistical significance due to RPE. These concomitant changes of the lower part of the face need to be taken into account and to be integrated in a patients' treatment plan according to his facial type (dolichofacial or brachyfacial).

Further investigation with bigger sample sizes and more long term results can give more insight into this subject.

## Introduction

Maxillary widening is very often needed in orthodontics to accommodate the permanent teeth and to allow anteroposterior movement of the jaws with relative stability and functional occlusion [1-3]. There are many ways of maxillary expansion according to each individual problem. When severe absolute or relative skeletal discrepancies exist, then usually Rapid Palatal Expansion is indicated [4,5]. Absolute skeletal discrepancy is the condition according to which the maxilla is undersized relatively to the rest of the facial dimensions [4]. Relative skeletal discrepancy is the condition where the maxilla has normal size when compared with the rest facial dimensions but is occluding with an oversized mandible [4].

Rapid Palatal Expansion (RPE) is the orthodontic/orthopedic procedure which involves the fracture of the midpalatal suture and a quick widening of the maxilla. The gap is filled in initially with hemorrhagic tissue which is gradually replaced with bone apposition [1]. Figure 1 presents a typical RPE appliance. The protocol of the widening usually varies from 0.25 to 0.5 mm per day [1,2]. In the majority of the cases this is performed in the early stages of the permanent dentition, the 13<sup>th</sup> to 16<sup>th</sup> year of age [1]. In older patients, due to the stronger interdigitation of the maxillary bones in the midpalatal suture, the same procedure may require the former performance of a surgical procedure (Surgical Rapid Palatal Expansion or SARPE) to achieve acceptable results [1,2].

The separation of the two halves of the maxilla during the widening procedure is accompanied by simultaneous dental and skeletal effects [4-7]. Therefore, a gap between the two upper central incisors (Figures 2 and 3) becomes evident from the first month [1,2,4,7]. This gap gradually closes by the tension of the maxillary mucosa and the force of transseptal fibers once the widening stops and the healing and bone apposition in the hemorrhagic area between the two maxillary bones begins [1,2,4,7].

Since the palate extends upwards to the nasal bones, one may confront the question: does RPE affect the width and, consequently, the shape of the nose significantly?

Another concomitant occurrence during the widening of the maxilla is the increase in the buccal inclination of the posterior maxillary teeth. Despite the rigidity of the appliance (usually Hyrax or

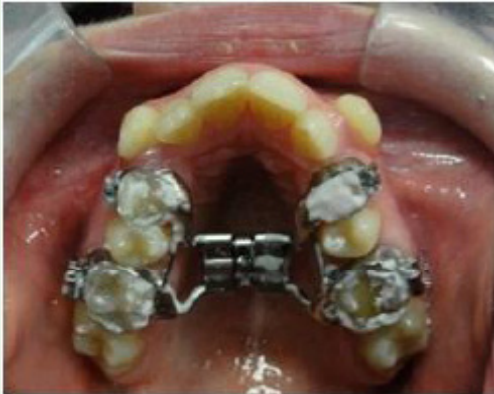

Figure 1: Appliance for RPE (Hyrax appliance) just placed in mouth.

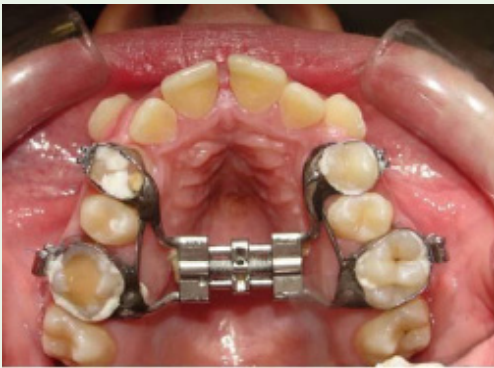

Figure 2: Effect of RPE in the widening of the maxilla.

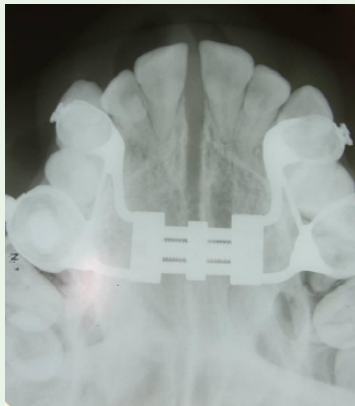


Figure 3: Effect of RPE in the maxilla as shown in x-ray.

Haaz) usually an increase in the buccal inclination of the maxillary posterior teeth is observed [1-7]. This, in turn, increases the vertical dimension of the lower third of the face and forces the mandible to a clockwise movement [8-10]. This can be an indication in deep bite patients but a contra-indication in open bite patients [6,11]. So the next question to be answered is: Does RPE increases significantly the Lower Anterior Face Height (LAFH)?

The removal of the appliance marks the beginning of the resorption phase and all these concomitant changes in the transverse and the vertical dimension of the maxilla start to relapse [2,4,7]. It is

believed that the permanent gain in bone in the transverse dimension after RPE is just half of the one measured at the end of the activation of the appliance [2,4,7]. The rest of the activation is transferred to the teeth and expressed as change in their axial inclination relative to the maxilla [1-4,7].

Therefore, the PICO question this study aims to answer is: Do orthodontic patients exposed to RPE, as compared to non-treated orthodontic patients, present significant changes in the face in short and long term evaluation both in the transverse and in the vertical dimensions?

### Materials and Methods

A prospective control clinical trial was designed in order to give some light to these questions. A total sample of 23 patients of age 13-16 years whose treatment plan included RPE was collected during 2013 from a private orthodontic practice\*. Both patients and parents gave informed consent for their participation in this study provided this would not affect the treatment plan, the duration and the cost of their treatment. The protocol of RPE followed in 5 of the treated patients was two turns per day for approximately 2.5 weeks (i.e. 0.50 mm per day). The rest 18 patients followed a protocol of one turn per day (i.e. 0.25 mm per day) for approximately 1.5 month. In both two different protocols a stabilization period of 3 months followed the activation period.

The control sample consisted of 23 individuals of the same age who, according to the authors' opinion, needed RPE but their parents refused orthodontic treatment due to financial reasons. They were

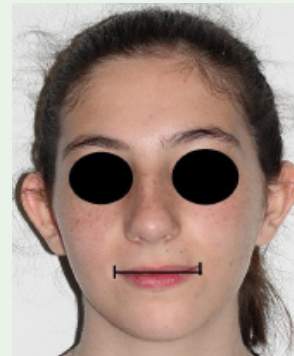


Figure 4: Measurement of the length of the lips.

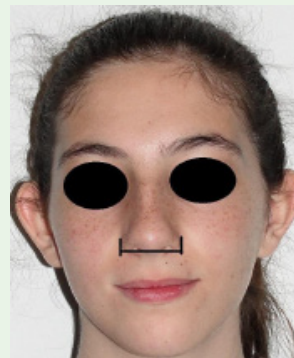


Figure 5: Measurement of the width of the base of the nose.

asked to continue to attend the practice free of charge. Patients and parents of the control group were also informed about their participation in this study and gave informed consent.

Three soft tissue cephalometric variables were examined with the aim to answer to the PICO question expressed above:

1. The length of the lips (between the two commissures) in the transverse plane exactly in the area of expansion (Figure 4).
2. The width of the base of the nose (between the two most projected points of the nostrils) in the transverse plane just

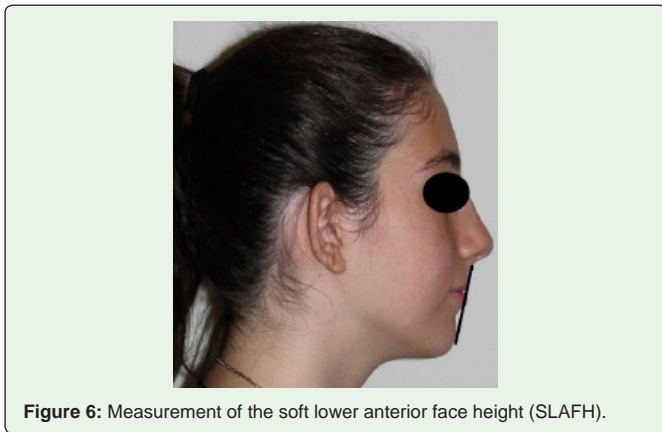


Figure 6: Measurement of the soft lower anterior face height (SLAFH).

above the area of the actual expansion (Figure 5).

3. The Soft Tissue Lower Anterior Face Height (SLAFH) (between soft subnasale and soft pogonion) in the vertical plane (Figure 6).

All measurements were performed on the actual faces of the patients. No x-rays were used for these measurements. The measurements in the treated sample were performed (a) before treatment -To (b) after RPE and the 3 months stabilization period with the appliance in place -T1 and (c) after completion of the whole orthodontic treatment -T2. In the control sample the corresponding measurements were performed (a) in their first visit -To, (b) after 4 months time -T1 and (c) in two years (24 months) time from their first visit -T2.

**Results**

The statistical elaboration of the primary data was performed with the paired t-test. Statistical significance was set at  $p < 0.05$  with 95% Confidence Intervals. The Shapiro-Wilk test was previously performed to confirm the normal distribution of the measurements in the compared groups of the primary data.

Table 1 presents the results of the comparisons.

Regarding the length of the lips it doesn't seem to be affected by RPE and their changes are not accompanied by any statistical significance (Table 1).

The width of the base of the nose, however, seems to be significantly affected by RPE. The control group doesn't seem to present any serious alteration to the nose whereas the treated group both in the short and in the long term presents some widening of its base. This result is reinforced with statistical significance (Table 1).

The SLAFH increases in both the treated and the control group.

Table 1: Data comparisons and results.

Data comparison	Mean	95% Confidence Intervals	Paired t-value	p-value	Statistical significance
Lip length in control group between To-T1	-0.0130	-0.0367 to 0.0107	-1.14	0.266	no
Lip length in control group between To-T2	-0.0304	-0.0800 to 0.0191	-1.27	0.216	no
Lip length in treated group between To-T1	-0.0522	-0.1258 to 0.0214	-1.47	0.156	no
Lip length in treated group between To-T2	-0.0348	-0.0954 to 0.0258	-1.19	0.247	no
Nose width in control group between To-T1	0.000000	0.000000 to 0.000000	All values in column are identical	All values in column are identical	no
Nose width in control group between To-T2	0.005	-0.309 to 0.318	0.03	0.976	no
Nose width in treated group between To-T1	-0.3136	-0.3554 to -0.2719	-15.63	0.000	yes
Nose width in treated group between To-T2	-0.1636	-0.2012 to -0.1261	-9.05	0.000	yes
SLAFH in control group between To-T1	-0.500	-0.798 to -0.202	-3.49	0.002	yes
SLAFH in control group between To-T2	-1.545	-2.471 to -0.620	-3.47	0.002	yes
SLAFH in treated group between To-T1	-2.818	-3.425 to -2.212	-9.67	0.000	yes
SLAFH in treated group between To-T2	-1.955	-2.475 to -1.434	-7.81	0.000	yes

Yet, the treated group presents quantitatively much higher an increase than the control. In the treated group the increase in the short term is greater than in the long term, whereas in the control group it seems to be almost constant. The vertical increase is accompanied by statistical significance for both the treated and the control group (Table 1).

**Discussion**

The present study based on primary clinical data made evaluations of possible changes in facial morphology following RPE treatment as part of a full orthodontic treatment. The evaluations were made both in the short term (measurements after RPE plus 3 months stabilization with the appliance still in mouth) as well as in the long term (measurements at the end of the orthodontic treatment). A control sample was used to make parallel comparisons and to give validity to the results. Measurements were made in the transverse and in the vertical dimension.

Absence of increase in lip length during the ages 14-16 years and regardless of the performance of RPE is the first finding. The great flexibility and adaptation of the perioral muscles possibly accommodates the maxillary skeletal changes without permitting any change to the shape and specifically to the length of the lips. Other studies in the literature also support this finding [12].

On the other hand, the width of the base of the nose seems to increase following RPE and this alteration is verified by statistical significance. The long term widening (t-value=-9.05) is somewhat smaller than the short term one (t-value=-15.63) in absolute numbers. This is probably because, despite the bone apposition during RPE, bone resorption is very intense in the following period up to the point that occlusion, soft tissues and hard tissues come to a balance [13]. Usually, only 50% of the initial appliance activation remains in the form of stable transverse orthopedic expansion [1]. These findings are also supported by multiple studies in the literature [7,8,12-16]. In the control sample, i.e. in the absence of any treatment, the width of the nose does not present any significant change.

Regarding the vertical dimension measured by means of the variable SLAFH, this presents statistically significant increase both in the treated and in the control group. This may be explained by the fact that patients in need of RPE, like the ones collected in this study, are in their majority mouth breathers and present the “long and narrow face” syndrome [17-19]. Due to the upper position of the tongue and to the lack of tonicity to the masseter muscles, these patients have their face length increased during the years anyway [17-19]. What happens with RPE is that despite the maxillary expansion and the increased nasal air volume the tonicity of the muscles and the position of the tongue cannot be altered. Instead, the buccal inclination of the posterior teeth is more dominant. Perhaps the age of these patients (13-16 years) also prohibits radical bioprogressive alterations towards normal [17-19]. Therefore, the maxilla forces the mandible to a posterior and inferior rotation and the overall lower anterior face height is increased even more [20,21]. In the long term though, masticatory forces reduce the buccal inclination of the posterior maxillary teeth and the mandible tends to resume back to a more upward position [20,21]. The final result is a lesser increase in SLAFH in the long term compared with the short term in patients undergone RPE which is still greater than the one presented in the control group. Therefore, RPE seems to be more beneficial for Class III patients (i.e. patients whose mandible is more prominent than the maxilla) than for Class II patients (i.e. patients whose maxilla is more prominent than the mandible) [22-24]. The literature also supports these findings with various studies [7-12,16,17,22-24].

## Conclusion

Rapid palatal expansion is a traditional orthodontic/orthopedic mean to expand the maxilla in order to accommodate the teeth properly and to achieve better occlusion. Yet, its skeletal consequences are evident in the face both in the transverse and in the vertical plane. The base of the nose in the area of the nostrils presents some small but permanent widening. The SLAFH seems to present a variable increase depending on the type of the face, the pattern of breathing and the time passed from RPE. More detailed studies in the future based in bigger samples and designed for longer periods are considered necessary in order to acquire more valid results.

## References

1. Profit WR, Fields HW. Contemporary Orthodontics. US: CV Mosby. 2000.

2. De Coster T. [Orthopedic expansion of the maxilla]. *Orthod Fr.* 2006; 77: 253-264.
3. Langlade M. *Diagnostic orthodontique*. Paris, Maloine. 1981; 704-728.
4. DR Buddee. Some comparison of slow and rapid maxillary expansion. Treatise, Department of preventive dentistry, University of Sydney, New South Wales, Australia. 1984.
5. Angle EH. *Orthodontia*. Dent Cosmos11. 1920.
6. Moyers RE. Skeletal contributions to occlusal development. McNamara JA, editor. In: *The biology of occlusal development*. Ann Arbor, University of Michigan. 1977; 122-135.
7. Chung CH, Font B. Skeletal and dental changes in the sagittal, vertical, and transverse dimensions after rapid palatal expansion. *Am J Orthod Dentofacial Orthop.* 2004; 126: 569-575.
8. Berger JL, Pangrazio-Kulbersh V, Thomas BW, Kaczynski R. Photographic analysis of facial changes associated with maxillary expansion. *Am J Orthod Dentofacial Orthop.* 1999; 116: 563-571.
9. Schuster G, Borel-Scherf I, Schopf PM. Frequency of and complications in the use of RPE appliances--results of a survey in the Federal State of Hesse, Germany. *J Orofac Orthop.* 2005; 66: 148-161.
10. Cerruto C, Di Vece L, Doldo T, Giovannetti A, Polimeni A, Goracci C. A computerized photographic method to evaluate changes in head posture and scapular position following rapid palatal expansion: a pilot study. *J Clin Pediatr Dent.* 2012; 37: 213-218.
11. Delaire J. [Manufacture of the “orthopedic mask”]. *Rev Stomatol Chir Maxillofac.* 1971; 72: 579-582.
12. Habeeb M, Boucher N, Chung CH. Effects of rapid palatal expansion on the sagittal and vertical dimensions of the maxilla: a study on cephalograms derived from cone-beam computed tomography. *Am J Orthod Dentofacial Orthop.* 2013; 144: 398-403.
13. Altorkat Y, Khambay BS, McDonald JP, Cross DL, Brocklebank LM, Ju X. Immediate effects of rapid maxillary expansion on the naso-maxillary facial soft tissue using 3D stereophotogrammetry. *Surgeon.* 2014.
14. Fränkel R. Decrowding during eruption under the screening influence of vestibular shields. *Am J Orthod.* 1974; 65: 372-406.
15. Fränkel R, Fränkel C. *Orofacial orthopedics with the function regulator*. Munich. S Karger. 1989.
16. Tausche E, Deeb W, Hansen L, Hietschold V, Harzer W, Schneider M. CT analysis of nasal volume changes after surgically-assisted rapid maxillary expansion. *J Orofac Orthop.* 2009; 70: 306-317.
17. Linder-Aronson S. Adenoids. Their effect on mode of breathing and nasal airflow and their relationship to characteristics of the facial skeleton and the dentition. A biometric, rhino-manometric and cephalometro-radiographic study on children with and without adenoids. *Acta Otolaryngol Suppl.* 1970; 265: 1-132.
18. Bakor SF, Enlow DH, Pontes P, De Biase NG. Craniofacial growth variations in nasal-breathing, oral-breathing, and tracheotomized children. *Am J Orthod Dentofacial Orthop.* 2011; 140: 486-492.
19. Shapiro GG. The role of nasal airway obstruction in sinus disease and facial development. *J Allergy Clin Immunol.* 1988; 82: 935-940.
20. Eichenberger M, Baumgartner S. The impact of rapid palatal expansion on children's general health: a literature review. *Eur J Paediatr Dent.* 2014; 15: 67-71.
21. Pearson LE. Vertical control in treatment of patients having backward-rotational growth tendencies. *Angle Orthod.* 1978; 48: 132-140.
22. Baccetti T, Franchi L, Schulz SO, McNamara JA. Treatment timing for an orthopedic approach to patients with increased vertical dimension. *Am J Orthod Dentofacial Orthop.* 2008; 133: 58-64.

23. Altuğ Z, Erdem D, Rübendüz M. [Investigation of the functional treatment effects of the skeletal and dental Class III anomalies on the skeletal region]. Ankara Univ Hekim Fak Derg. 1989; 16: 447-452.
24. Arman A, Toygar TU, Abuhijleh E. Profile changes associated with different orthopedic treatment approaches in Class III malocclusions. Angle Orthod. 2004; 74: 733-740.