

Indications for Supramalleolar Osteotomy Based on Arthroscopic Findings for Varus Type Ankle Osteoarthritis

Naohiro Hio^{1*}, Atsushi Hasegawa², Satoshi Monden³, Hideo Noguchi⁴, Masanori Taki⁵ and Kenji Takagishi¹

¹Department of Orthopaedic Surgery, Gunma University Graduate School of Medicine, Japan

²Agatsumahigashi Orthopaedic Clinic, Japan

³Kiryu Orthopaedic Hospital, Japan

⁴Ishii Clinic, Japan

⁵Seirei Hamamatsu General Hospital, Japan

Article Information

Received date: Dec 24, 2015

Accepted date: Jan 23, 2016

Published date: Jan 28, 2016

*Corresponding author

Naohiro Hio, Department of Orthopaedic Surgery, Gunma University Graduate School of Medicine, Japan, Tel: +81 27 268 5777; Fax: +81 27 268 5778; Email: premiernepuissecondnedaig-travaux@yahoo.co.jp

Distributed under Creative Commons CC-BY 4.0

Abstract

Background: Preoperative arthroscopic examinations were carried out in patients with varus deformity among those with osteoarthritis of the ankle caused by malalignment, and to assess the severity of the disease on the basis of the arthroscopic findings, and the associations of these findings with X-ray findings and the indications for supramalleolar osteotomy were evaluated.

Methods: A total of 57 joints in 56 patients were investigated, and the mean follow-up period was 4 years. The proportion of the surface area of the ankle that had become hardened into an eburnation was classified according to a five-grade scale on the basis of preoperative arthroscopy: Grade 1 indicated fibrillation of the articular cartilage alone with no evident eburnation; Grade 2, eburnation was limited to the medial malleolar articular surface; Grade 3, eburnation extended across the medial shoulder of the talus, but covered <25% of the talocrural joint; Grade 4, eburnation covered ≥25% but <50% of the talocrural joint; and Grade 5, eburnation covered ≥50% of the talocrural joint. The surgical procedure used was lateral closing wedge osteotomy, and assessments were carried out using Takakura, et al.'s clinical score and Tanaka, et al.'s radiographic grading system.

Results: Initially, 3 joints were Grade 1, 19 were Grade 2, 15 were Grade 3, 16 were Grade 4, and 4 were Grade 5. Postoperatively, 30 joints were Grade 1, 14 were Grade 2, 7 were Grade 3, 4 were Grade 4, and 2 were Grade 5. Clinical scores showed an improvement from 63.9±11.2 points preoperatively to 81.9±13.2 points postoperatively.

Conclusion: Patients who were classed as Grade 3 or below by preoperative arthroscopy showed improved clinical outcomes and radiographic grades. To assess the proportion of cartilage, that may affect postoperative outcomes, preoperative arthroscopy should be done prior to the supramalleolar osteotomy.

Introduction

Osteoarthritis of the ankle that is caused by malalignment of the leg is classified as either varus type or valgus type according to the inclination of the talus, with the varus type accounting for the majority of cases. Mild to moderate varus-type osteoarthritis of the ankle is treated surgically with supramalleolar osteotomy, the indication criteria for which are generally determined by plain X-ray evaluation. Takakura's four-grade classification [1] is conventionally used, and Tanaka, et al. have further subdivided Stage 3 into Stage 3a, in which the joint space in the ankle joint has been lost, and Stage 3b, in which narrowing of the joint space extends to the medial side of the talocrural joint, with surgery indicated up to Stage 3a [2]. Although Takakura, et al. found that arthroscopy after low tibial osteotomy showed that areas of the joint surface that had been ulcerated preoperatively were covered in fibrous tissue postoperatively, with biopsy demonstrating the presence of fibrous tissue and fibrocartilage within this granulation tissue [1], few studies have yet addressed preoperative arthroscopy of this joint. In this study, preoperative arthroscopy was performed to ascertain the condition inside the joint and to assess the severity of the disease on the basis of the arthroscopic findings, and the associations of these findings with X-ray findings and the indications for supramalleolar osteotomy were evaluated.

Material and Methods

Fifty seven ankles of 56 patients who underwent supramalleolar osteotomy to treat varus-type osteoarthritis of the ankle caused by malalignment between June 1993 and February 2013 were evaluated in this study. There were 11 joints in men and 46 in women. The patients' mean age at

Table 1: Preoperative and postoperative arthroscopic assessment.

Preoperative arthroscopic grade	Postoperative arthroscopic grade					Total cases	Percentage of Grade 1 and 2
	Grade 1	Grade 2	Grade 3	Grade 4	Grade 5		
Grade 1	3	0	0	0	0	3	100
Grade 2	12	6	1	0	0	19	95
Grade 3	8	5	1	0	1	15	87
Grade 4	5	3	4	3	1	16	50
Grade 5	2	0	1	1	0	4	50
Total cases	30	14	7	4	2		

Table 2: Association between preoperative arthroscopic classification and radiographic staging.

Preoperative arthroscopic grade	Preoperative X-ray classification				
	Stage 1	Stage 2	Stage 3a	Stage 3b	Stage 4
Grade 1		3			
Grade 2	1	14	2	2	
Grade 3	1	1	11	2	
Grade 4			1	15	
Grade 5				4	

the time of surgery was 58.3 years (range 36-76 years), and the mean postoperative follow-up period was 4 years (range 1 year to 15 years 1 month).

All subjects underwent preoperative arthroscopy with a 2.7mm diameter 30° oblique arthroscope, which was repeated 1 year postoperatively when the internal fixation device was removed. The surgical procedure consisted of a lateral closing wedge supramalleolar osteotomy of both the tibia and fibula at a height of 5 cm proximal to the ankle joint, with the osteotomy angle being the angle formed by the sole of the foot and the articular surface of the talar trochlea on weight-bearing frontal X-ray images taken while standing on one leg on the affected leg, and both bones fixed with plates. Postoperatively, after three weeks of casting, the patients were instructed to walk wearing a patellar tendon-bearing orthosis, and Range of Motion (ROM) exercises of the ankle were performed. After 12 weeks, the orthosis was removed, and the patients were instructed to walk with full weight-bearing.

Since arthroscopy reveals eburation from the malleolar articular surface to the talocrural joint surface, it has been suggested that the eburation rate may indicate severity; therefore, the disease state was classified into the following five categories: Grade 1, fibrillation of the malleolar articular surface alone with no evident eburation; Grade 2, eburation limited to the malleolar articular surface; Grade 3, eburation that extended across the medial shoulder of the talus but covered <25% of the articular surface of the talocrural joint; Grade 4, eburation that covered ≥25% but <50% of the articular surface of the talocrural joint; and Grade 5, eburation covering ≥50% of the articular surface of the talocrural joint. A probe with a scale was used to measure the proportions of healthy and eburnated cartilage, and the severity was assessed by multiple doctors.

Preoperative and postoperative clinical assessments were carried out following the assessment method of Takakura, et al. [3], and Tanaka, et al.'s grading system was used for radiographic assessment.

Statistical analysis was performed using Wilcoxon's signed rank test to test for differences between preoperative and postoperative clinical outcomes. P value of < 0.05 was considered statistically significant.

Results

In terms of preoperative arthroscopic classification, 3 joints were Grade 1, 19 were Grade 2, 15 were Grade 3, 16 were Grade 4, and 4 were Grade 5. Postoperatively, 30 joints were Grade 1, 14 were Grade 2, 7 were Grade 3, 4 were Grade 4, and 2 were Grade 5. The postoperative arthroscopic classification grade was worse than the preoperative grade for 3 joints (Table 1). The mean clinical assessment score improved significantly from 63.9 ± 11.2 points (range 38-93 points) preoperatively to 81.9 ± 13.2 points (range 43-100 points) 1 year postoperatively and 82.1 ± 12.3 points (range 48-100 points) at final follow-up. The difference between the preoperative and postoperative scores was significant (p < 0.01). The difference between the preoperative and final follow-up scores was also significant (p < 0.01). In terms of the association between the preoperative arthroscopic assessment and the clinical assessment score, joints that were Grade 4 or above tended to have worse clinical scores (Figure 1). On radiographic assessment preoperatively, 2 joints were Stage 1, 18 were Stage 2, 14 were Stage 3a, and 23 were Stage 3b, while postoperatively, 17 joints were Stage 1, 24 were Stage 2, 11 were Stage 3a, 3 were Stage 3b, and 2 were Stage 4. With respect to the association between preoperative arthroscopic classification and radiographic staging, the modal value for each grade corresponded to the radiographic stage, with Grade 2 of the arthroscopic classification corresponding to radiographic Stage 2, Grade 3 to Stage 3a, and Grade 4 to stage 3b. Stage 3b, however, also included many joints of grades

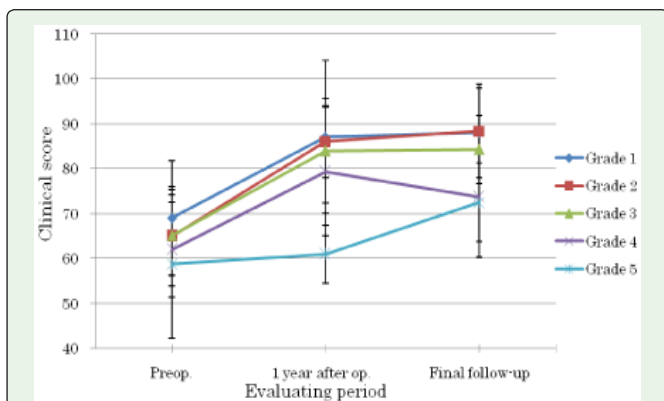


Figure 1: Association between the preoperative arthroscopic grades and the clinical assessment score.

Table 3: Association between the preoperative arthroscopic assessment and the postoperative radiographic assessment.

Preoperative arthroscopic grade	Postoperative X-ray classification					Percentage of Stage 1 and 2
	Stage 1	Stage 2	Stage 3a	Stage 3b	Stage 4	
Grade 1	1	2				100
Grade 2	8	9	2			89
Grade 3	6	5	3		1	73
Grade 4	2	6	5	2	1	50
Grade 5		2	1	1		50

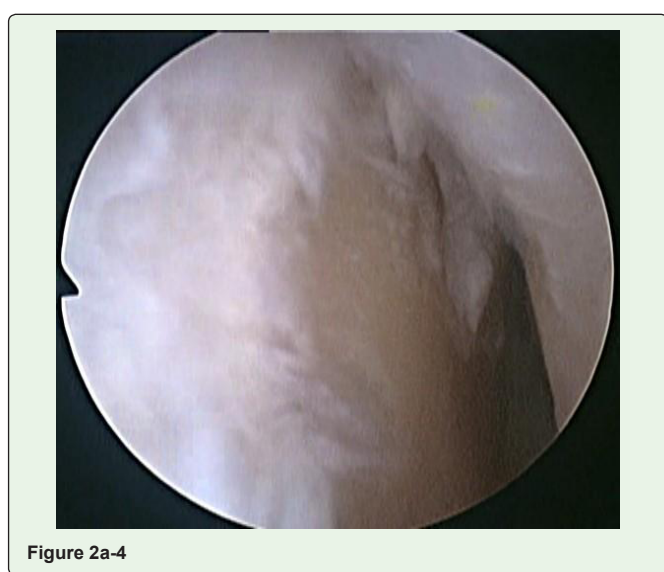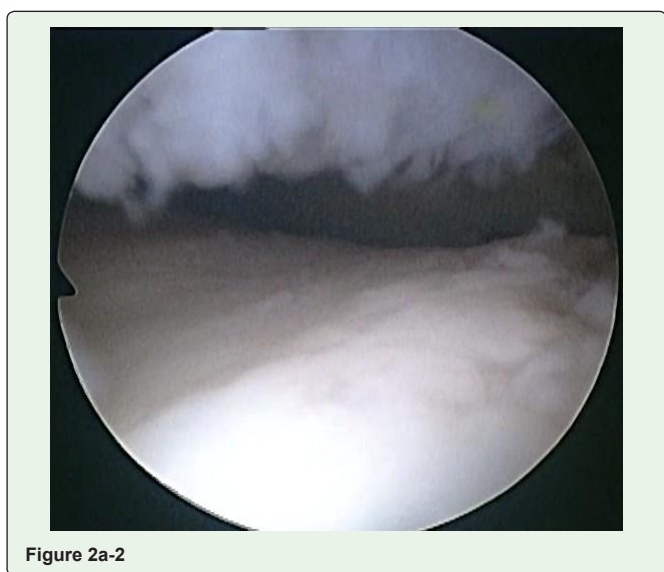

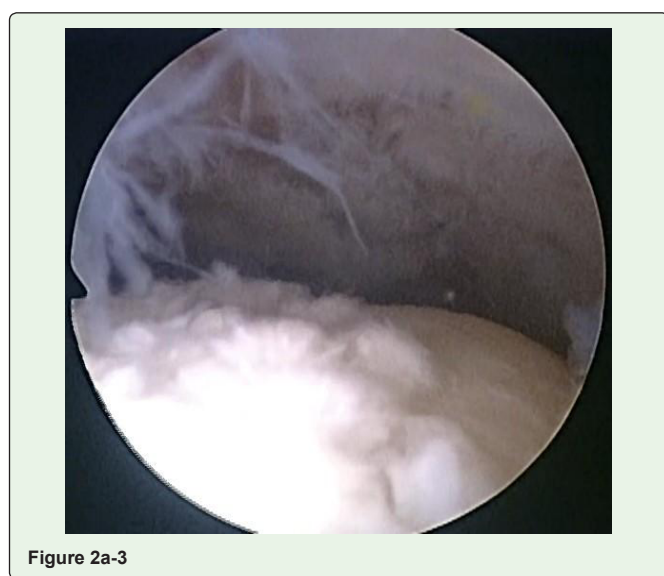
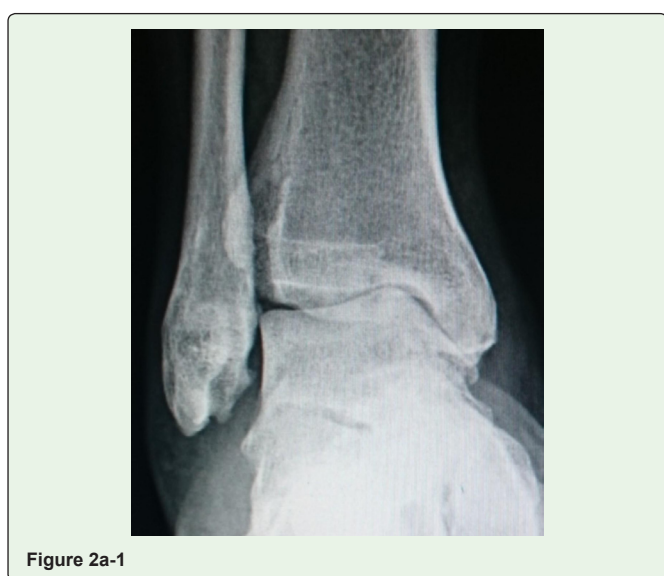Figure 2a: A 61-year-old man with varus-type ankle osteoarthritis. 2a: Preoperative findings. 1) X-ray classification was Stage 3b. 2)-4) arthroscopic grade was 3.

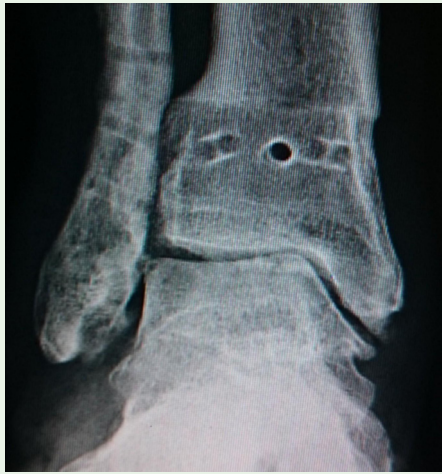

Figure 2b-1

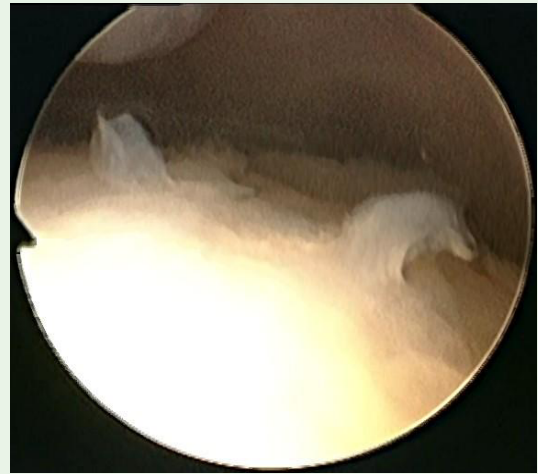

Figure 2b-3

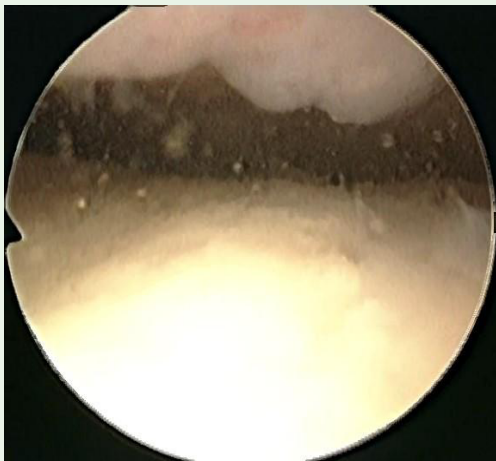


Figure 2b-2

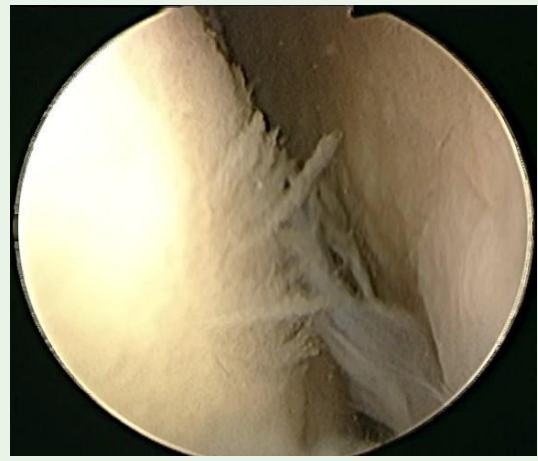

Figure 2b-4

Figure 2b: Postoperative findings. 1) X-ray classification was Stage 2. 2)-4) arthroscopic grade was 1. The clinical score improved from 73 points preoperatively to 88 points 1 year postoperatively.

other than Grade 4 (Table 2). In terms of the association between the preoperative arthroscopic assessment and the postoperative radiographic assessment, joints that were Grade 3 or below tended to show much improvement in radiographic stage (Table 3, Figure 2).

Two patients, both of whom were Grade 4 on preoperative arthroscopic classification, underwent additional surgery for ankle joint fixation due to the progression of postoperative osteoarthritic change.

Discussion

Varus-type osteoarthritis of the ankle is believed to be caused by distal tibial malalignment, such as tilting of the tibial plafond, or other conditions, such as lateral ankle ligament insufficiency [4]. In a biomechanical study on cadavers, it was reported that distal tibial deformities showed changes in the contact area, the contact shape, and the contact location [5]. The type of treatment depends on the stage of the disease, and supramalleolar osteotomy generally indicated when it is of mild to moderate severity [1,2,6-8], but studies of the indication criteria for supramalleolar osteotomy are controversial.

According to Tanaka, et al., supramalleolar osteotomy is indicated in cases that are Stage 2 or Stage 3a on plain X-ray [2]. Barg, et al. and Easley, et al. stated that the indications for supramalleolar osteotomy comprise asymmetric ankle OA with concomitant valgus or varus deformities and a partially (at least 50%) preserved tibiotalar joint surface [9,10]. Lee, et al. reported that it is indicated for patients with minimal talar tilt and neutral or varus heel alignment [11]. According to Colin, et al., the surgery is indicated if the ‘sidewalk sign’ (pain relief on a sloped surface tilted in the opposite direction of the deformity) is positive [12]. Haraguchi, et al. found that, in ankles in which the preoperative mechanical ankle joint axis point is more medial than the tibial plafond, the point was insufficiently moved to the lateral side, and the clinical outcomes were less satisfactory [13].

There are reports in the literature on arthroscopic assessment before and after supramalleolar osteotomy. Cheng, et al. reported improvement in Outer bridge grade [14] from grade 3-4 preoperatively to grade 1-2 postoperatively [15], while Takakura, et al. performed arthroscopy following low tibial osteotomy and found that joint surfaces that had been ulcerated preoperatively were covered in fibrous tissue postoperatively, with biopsy demonstrating the

presence of fibrous tissue and fibrocartilage within this granulation tissue [1]. According to Kim, et al., persistent pain experienced after supramalleolar osteotomy was found to be associated with adhesions, synovitis, and soft tissue impingement in the medial and lateral gutters of the ankle, but they did not address the issue of articular cartilage [16]. To the best of our knowledge, the present study is the first to have addressed the association between the assessment of the state of articular cartilage on the basis of arthroscopic findings on one hand and clinical outcomes and imaging findings on the other.

The results of the present study led us to the conclusion that postoperative outcomes were better if there was some healthy remaining articular cartilage, and that arthroscopic classification of Grade 3 or below was a good indication for supramalleolar osteotomy. This suggested that, if this study's arthroscopic classification is used, many of the cases evaluated as Stage 3b on plain X-ray and, therefore, regarded as not suitable for supramalleolar osteotomy, could be classified as Grade 3 or below if a large amount of healthy articular cartilage remains, and this procedure would therefore be indicated.

Since the stage of the preoperative X-ray classification corresponds to the modal value of each grade of the arthroscopic classification, it is possible, to some extent, to predict the status of the articular cartilage from preoperative X-rays. Preoperative MRI also helps to predict the prognosis. In addition to these imaging findings, by accurately identifying articular cartilage preoperatively using such arthroscopic classification, it is therefore possible to more accurately determine the indications and predict the postoperative results of supramalleolar osteotomy.

Postoperative clinical outcomes and imaging assessments tended to be less satisfactory for joints classed as Grade 4 or above according to our arthroscopic classification. This may have been because, although the surface of the ankle mortise underwent valgus correction as a result of supramalleolar osteotomy, the talus was not corrected to the same extent as the articular surface of the tibial plafond, meaning that the talocrural joint space did not become parallel.

Barg, et al. stated that, in patients with a cartilage Outerbridge grade IV lesion, cartilage debridement and microfracturing should be performed [17], but the arthroscopic findings in the present study indicated that, even without carrying out microfracturing or other treatment for preoperative eburnated areas, in many cases after surgery, these areas were covered with fibrocartilaginous tissue, suggesting that microfracturing may not always be necessary. However fibrocartilaginous tissue is not normal hyaline articular cartilage, even though coverage with fibrocartilaginous tissue may result in the distribution of load stress. Arguably, osteochondral or chondral grafting may be necessary to achieve functional hyaline articular cartilage in the future.

In summary, the arthroscopic classification of osteoarthritis of the ankle proposed in the present study enables the accurate assessment of the condition inside the ankle, permitting the indications for supramalleolar osteotomy to be determined with greater precision. At this point, the preoperative assessment of patients of Grade 3 and below is satisfactory, and good postoperative outcomes can be expected even in cases that are Stage 3b according to plain X-ray evaluation if the preoperative arthroscopic classification is Grade 3 or below.

References

1. Takakura Y, Takaoka T, Tanaka Y, Yajima H, Tamai S. Results of opening-wedge osteotomy for the treatment of a post-traumatic varus deformity of the ankle. *J Bone Joint Surg Am.* 1998; 80: 213-218.
2. Tanaka Y, Takakura Y, Hayashi K, Taniguchi A, Kumai T, Sugimoto K. Low tibial osteotomy for varus-type osteoarthritis of the ankle. *J Bone Joint Surg Br.* 2006; 88: 909-913.
3. Takakura Y, Tanaka Y, Sugimoto K, Tamai S, Masuhara K. Ankle arthroplasty. A comparative study of cemented metal and uncemented ceramic prostheses. *Clin Orthop.* 1990; 252: 209-216.
4. Harrington KD. Degenerative arthritis of the ankle secondary to long-standing lateral ligament instability. *J Bone Joint Surg Am.* 1979; 61: 354-361.
5. Tarr RR, Resnick CT, Wagner KS, Sarmiento A. Changes in tibiotalar joint contact areas following experimentally induced tibial angular deformities. *Clin Orthop Relat Res.* 1985; 199: 72-80.
6. Knupp M, Hintermann B. Treatment of asymmetric arthritis of the ankle joint with supramalleolar osteotomies. *Foot Ankle Int.* 2012; 33: 250-252.
7. Harstall R, Lehmann O, Krause F, Weber M. Supramalleolar lateral closing wedge osteotomy for the treatment of varus ankle arthrosis. *Foot Ankle Int.* 2007; 28: 542-548.
8. Pagenstert GI, Hintermann B, Barg A, Leumann A, Valderrabano V. Realignment surgery as alternative treatment of varus and valgus ankle osteoarthritis. *Clin Orthop Relat Res.* 2007; 462: 156-168.
9. Barg A, Pagenstert GI, Leumann AG, Müller AM, Henninger HB, Valderrabano V. Treatment of the arthritic valgus ankle. *Foot Ankle Clin.* 2012; 17: 647-663.
10. Easley ME. Surgical treatment of the arthritic varus ankle. *Foot Ankle Clin.* 2012; 17: 665-686.
11. Lee WC, Moon JS, Lee K, Byun WJ, Lee SH. *J Bone Joint Surg Am.* 2011; 93: 1243-1248.
12. Colin F, Gaudot F, Odri G, Judet T. Supramalleolar osteotomy: Techniques, indications and outcomes in a series of 83 cases. *Orthop Traumatol Surg Res.* 2014; 100: 413-418.
13. Haraguchi N, Ota K, Tsunoda N, Seike K, Kanetake Y, Tsutaya A. Weight-bearing-line analysis in supramalleolar osteotomy for varus-type osteoarthritis of the ankle. *J Bone Joint Surg Am.* 2015; 97: 333-339.
14. Outerbridge RE. The etiology of chondromalacia patellae. *J Bone Joint Surg Br.* 1961; 43: 752-757.
15. Cheng YM, Huang PJ, Hong SH, Lin SY, Liao CC, Chiang HC, et al. Low tibial osteotomy for moderate ankle arthritis. *Arch Orthop Trauma Surg.* 2001; 121: 355-358.
16. Kim YS, Youn HK, Kim BS, Choi YJ, Koh YG. Arthroscopic evaluation of persistent pain following supramalleolar osteotomy for varus ankle osteoarthritis. *Knee Surg Sports Traumatol Arthrosc.* 2014.
17. Barg A, Pagenstert GI, Horisberger M, Paul J, Gloyer M, Henninger HB, et al. Supramalleolar osteotomies for degenerative joint disease of the ankle joint: indication, technique and results. *Int Orthop.* 2013; 37: 1683-1695.