

Treatment of Madelung Deformity: A  
Case Report and Literature ReviewArsan Hussien Salih Salih<sup>1</sup>, Okan Aslantürk<sup>2\*</sup> and Kadir Ertem<sup>1</sup><sup>1</sup>Department of Orthopedics and Traumatology, Turgut Ozal Medical Center, Inonu University Medical School, Turkey<sup>2</sup>Department of Orthopedics and Traumatology, Bingöl State Hospital, Turkey

## Article Information

Received date: Jun 01, 2017

Accepted date: Jun 23, 2017

Published date: Jun 27, 2017

## \*Corresponding author

Okan ASLANTÜRK, Department of  
Orthopedics and Traumatology, Bingöl  
State Hospital, Bingöl, Turkey,  
Tel: (0426) 2131043;  
Email: okaslanturk@hotmail.com

Distributed under Creative Commons  
CC-BY 4.0

Keywords Madelung Deformity; Wrist  
Pain; Corrective Dome Osteotomy

## Abstract

Madelung deformity can be defined as developmental and progressive deformity of the distal radio-ulnar and radiocarpal joints. Although that the exact etiology of the disease is still unknown, the main reasons are considered to be due to delayed growth rate of the medial side of the growth plate of the distal radius causing relatively shortening of the medial side of the radius. In this paper, we present a 22 years old female patient with left side Madelung's deformity presented with a gradually increasing pain over the years on the dorsal and ulnar side of her left wrist especially during sports activities accompanied by abnormal appearance of the wrist. The deformity was corrected by corrective dome osteotomy. After surgery; pain relieved and range of motion of wrist increased. Distal radius deformities associated with Madelung deformity, can be treated successfully with surgery especially in the presence of pain and cosmetic discomfort.

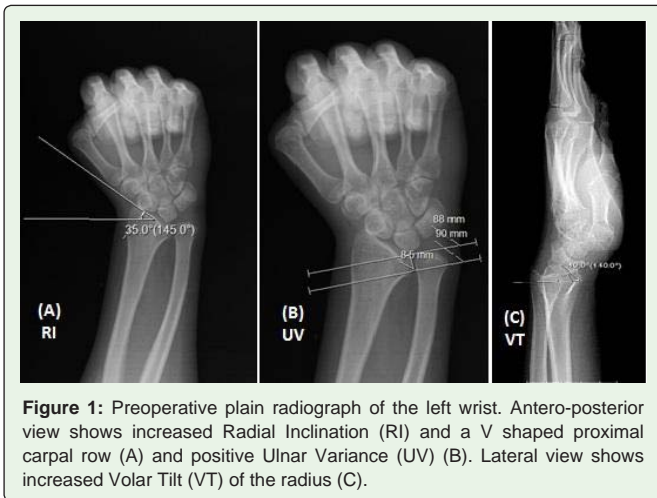
## Introduction

Madelung deformity is a rare congenital anomaly of the wrist caused by asymmetric growth at the distal radius physis secondary to a partial ulnar sided arrest. It's first described in 1855 by Malgaigne and 1878 by Madelung [1-4]. The deformity is more common in females and is often associated with Leri Weill dyschondrosteosis; a developmental skeletal dysplasia characterized by mesomelia (i.e., short forearm), short stature and Madelung deformity [5-8]. Patients usually present in late adolescence with characteristic wrist deformity, decreased wrist motion and wrist pain [9].

The typical Madelung deformity is associated with a Vickers ligament that creates a tether across the volar-ulnar radial physis that restricts growth across this segment. The distal radius deforms in the coronal (increasing radial inclination) and the sagittal (increasing volar tilt) planes. There is lunate subsidence and the proximal carpal row adapts to the deformity by forming an upside-down pyramid shape or triangle. Treatment depends on the age at presentation, degree of deformity and magnitude of symptoms. Mild asymptomatic deformity warrants a period of nonsurgical management with serial x-ray examinations because the natural history is unpredictable. Many patients never require surgical intervention. Progressive deformity in the young child with considerable growth potential remaining requires release of Vickers ligament and radial physiolysis to prevent ongoing deterioration. Advanced asymptomatic deformity in older children with an unacceptable-appearing wrist or symptomatic deformity are indications for surgery. A dome osteotomy of the radius allows 3-Dimensional correction of the deformity [10]. Many reports on procedures for the treatment of this deformity have described corrective osteotomies. Our procedure directed toward removing the deforming force on the volar ulnar distal aspect of the radius and correction of deformity with a dome osteotomy. In this case report, we presented surgical treatment and short term result of this rare condition.

## Case Report

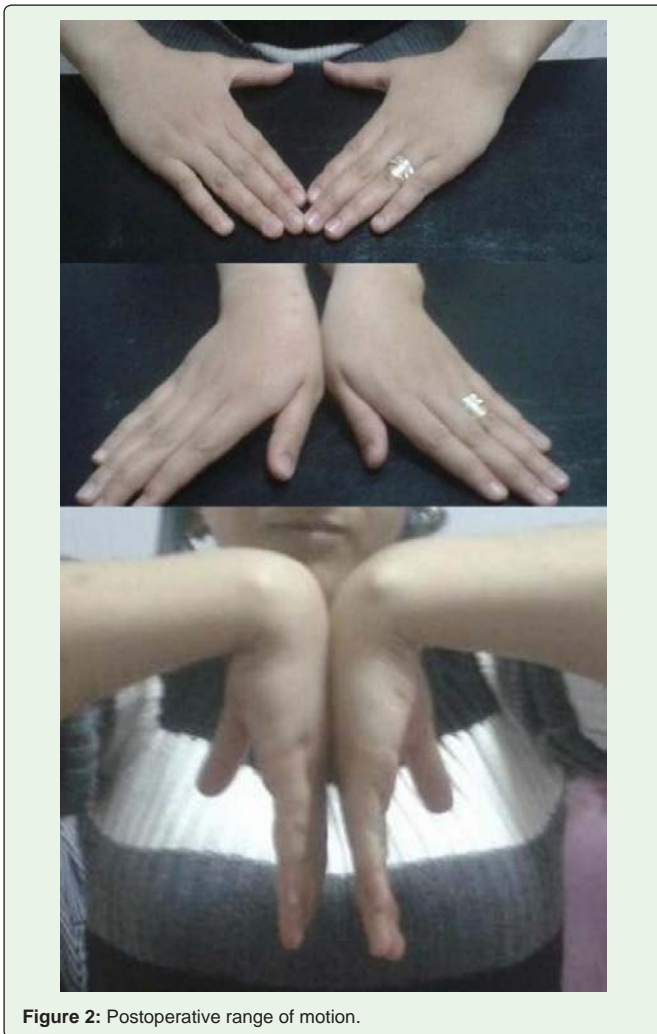A 22 years old female patient presented with a gradually increasing pain over the course of several years on the dorsal and ulnar side of her left wrist especially during sports activities accompanied by abnormal appearance of the wrist. The patient was unable to fully extend her left wrist because of the pain. Physical examination revealed palmar subluxation with associated prominence of the left radial and ulnar styloid processes, marked pain with passive pronation, and manual subluxation of the distal ulnar volarly. Left wrist extension and flexion were -600 and 700, respectively, and forearm pronation and supination were -550 and 450, respectively. Grip strength was 9kg on the left and 19kg on the right side. Ulnar grind test was positive and scaphoid shift test was negative in the left side. Patient rated evaluation scores were as follows; MAYO score was 35 (out of 100), Quick DASH score was 52. The antero-posterior plain radiographic imaging revealed exaggerated radial inclination and a V-shaped proximal carpal row. Radial Inclination (RI), Volar Tilt (VT), and ulnar variance were 350, 400, and 8.5 mm, respectively. Dorsal dislocation of the ulnar head and palmar shift of the carpus were also observed in the lateral radiograph (Figure 1). Distal radial



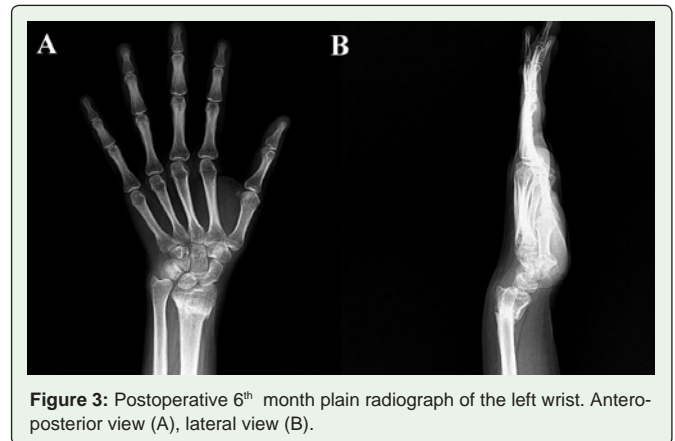
**Figure 1:** Preoperative plain radiograph of the left wrist. Antero-posterior view shows increased Radial Inclination (RI) and a V shaped proximal carpal row (A) and positive Ulnar Variance (UV) (B). Lateral view shows increased Volar Tilt (VT) of the radius (C).

dome osteotomy surgery was planned to correct patients deformity. A written informed consent was obtained from the patient

Under general anesthesia. A volar 7cm incision beginning 2cm distal to Lister’s tubercle and extending proximally in the forearm



**Figure 2:** Postoperative range of motion.



**Figure 3:** Postoperative 6<sup>th</sup> month plain radiograph of the left wrist. Antero-posterior view (A), lateral view (B).

provided an adequate exposure to the distal radial articular surface. Hypertrophic fibrotic radio-ulnar volar ligaments at the medial aspect of the distal radius had been cut. Two parallel K-wires (KT) were placed in the frontal and axial plane of the joint surface under the guidance of C-arm radiographic fluoroscope. Another two K-wires were placed in the axial and frontal plane of the diaphysis proximal to the osteotomy line.

The osteotomy site was marked with an osteotome. Using a 2.7mm drill bit, 3 drill holes were done at the site of osteotomy taking the shape of a dome with the convexity directed toward the wrist joint.

The osteotomy was done by connecting the 3 drill holes with an osteotome taking care to avoid a complete osteotomy of the volar cortex. The osteotomy was then opened dorsally and radially by manipulating the wrist into flexion, as well as applying spreader clamps into the osteotomy site. A 1.6 or 2.0 mm Kirschner wire was inserted obliquely from the radial styloid across the graft into the proximal radius. A second Kirschner wire was introduced through the Lister’s tubercle in an oblique dorso-palmar direction. Before the closure, the flexor tendons were relocated to their original site and flexor retinaculum was closed. This was followed by closure of the subcutaneous tissue and the skin. A below elbow plaster splint was applied. A postoperative roentgenogram was taken in two views to assure good correction. After two weeks, stitches were removed and the splint was changed.

When the period of immobilization was completed (6 weeks post-operatively), the splint and K-wire were removed. The patient was encouraged to do active exercises of the wrist.

At the 6<sup>th</sup> months follow-up, the patient reported very mild pain which responded well to physical therapy; both of wrist extension and flexion were 90° and forearm pronation and supination were 80° and 70°, radial and ulnar deviation was 30° and 20° respectively (Figure 2). The grip strength of the left hand improved to 18 kg. Postoperative scores were improved compared with preoperative scores; MAYO score was 85 (out of 100), QuickDASH score was 8.25. Postoperative values of Radial Inclination (RI), Volar Tilt (VT) and ulnar variance were improved from 35°, 40° and 8.5 mm to 24°, 13°, and 2.5 mm respectively (Figure 3).

**Discussion**

Madelung deformity can be defined as progressive deformity

of the distal radio-ulnar and radiocarpal joints [11]. It's present in less than 2% of the general population, female-male ratio is 3-5: 1 being more common in females [12]. Typically, it occurs bilaterally and rarely occurs before the age of 7 [12]. Some authors claim that the presence of deformity in mid or late adolescent period might be expected to be linked with the adolescent growth spurt [11].

Although that the exact etiology of the disease is still unknown, all the evidence suggests that the disorder is related to an abnormal growth of the epiphyseal plate in the distal and volar parts of the radioulnar joint [13]. Madelung deformity is generally divided into 4 groups according to the etiological factors of the disorder; post traumatic, dysplastic, genetic and idiopathic causes [11-13]. Although the genetic type of Madelung deformity is clinically associated with Turner syndrome, it may be associated with other genetic disorders as well [14].

Post-traumatic deformity develops over a long period of time due to excessive and/or abuse of the wrist joint [15]. Dysplastic Madelung deformity is a mesomelic form of dwarfism and usually accompanied by short forearms and legs [12]. Idiopathic type include patients who are not comply with the genetics, traumatic and dysplastic types.

Our case is a 22 year old female patient. She complains started to increase in the last two years. She is considered to be in the idiopathic category of the disorder due to negative family history and absence of evidence of trauma and shortness in both forearms and the lower limbs. We planned to treat her surgically because of progressive pain intensity, problems in meeting the simple daily needs, being a female patient and being cosmetically uncomfortable due to unacceptable appearance of the wrist.

Radiologic findings in Madelung deformity are diagnostic. It can be summarized as abnormalities in the distal radius, distal ulna and carpal bones. The deformity characterized by increased radial inclination, increased volar tilt in the distal radius and short radius bone due to unequal growth in the distal radial epiphysis with early closure of the medial half of the epiphysis. Dorsal subluxation of the distal ulna can also be seen. These changes are accompanied by wedging between the radial, ulnar and carpal bones and may be associated with triangular configuration [16].

Madelung deformity is usually treated conservatively or surgically depending on the severity of the symptoms [17]. Surgical treatment is preferred in adolescents and young adults complaining from severe pain and cosmetic discomfort [11,17]. Although a wide variety of surgical techniques are available, it can generally be divided into 3 groups. The first group includes epiphysiodesis applied to the radius alone, corrective osteotomy and physiolysis techniques [13]. The second group includes epiphysiodesis, distal ulnar excision or shortening osteotomy [18]. The third group comprises a combination of these techniques.

In the majority of cases, surgeons have performed radial closing or opening wedge osteotomies [19-21]. Potenza et al. reported satisfactory clinical results after closing wedge osteotomy of the radius with ulnar shortening or resection of the ulnar head in a series of 8 wrists with a mean follow-up of 34 years [19]. All patients were pain free and satisfied with the cosmetic results. However, closing wedge osteotomy is likely to worsen the radial shortening caused by the disease, and forearm shortening can subsequently result, which

is a shortcoming. In addition, dual osteotomy of the radius and ulna is invasive, and dorsal scarring is less acceptable. de Paula et al. reported radial opening wedge osteotomy using 2 planes with no ulna intervention for 4 wrists with a mean followup period of 2 years. They showed improvement in the range of motion and disappearance of pain. However, a disadvantage was that iliac bone grafting was required [21].

Harley et al. reported performing a radial dome osteotomy in which they hemispherically cut the distal radius and corrected the deformity 3-Dimensionally in a series of 26 wrists [22]. Four wrists received ulnar epiphysiodesis or shortening concurrently at radial correction, and 1 of the 4 had a Darrach resection performed later for recurrent pain. Four more wrists underwent ulnar shortening in the follow-up period (range, 7-49 mo). In total, approximately 30% required ulnar-side operations. All patients reported relief of pain and improved appearance at final follow-up.

Our corrective dome osteotomy result reported greater improvement in wrist motion, particularly in the degree of extension and forearm pronation that increased to 90 in each. Forearm pronation and supination were 800 and 700, respectively. The grip strength improved to 18kg. The Patient Related Wrist Evaluation score indicated complete relief of pain. The postoperative values of RI of 240 and VT of 130 were similar to the targeted correction values, which demonstrated the accuracy of the procedure. Radiologic, functional and cosmetic improvement were reported at the 6<sup>th</sup> months following the intervention. A disadvantage of this dome osteotomy is the difficulty of preoperative planning and surgical technique using 2-dimensional data, which requires skill and experience. Another disadvantage is that this method is not applicable to the abnormal physis of the radius.

## Conclusion

Distal radius deformities associated with Madelung deformity, can be treated with surgery especially in the presence of pain and cosmetic discomfort. We believe that, in dome osteotomy, by manipulating the remaining part of distal radius beyond the osteotomy line in any axis, the ideal desired correction can be achieved.

## References

1. Beals RK, Lovrien EW. Dyschondrosteosis and Madelung's deformity. Report of three kindreds and review of the literature. *Clin Orthop Relat Res.* 1976; 116: 24-28.
2. Dobyn J. *Madelung's Deformity.* New York: Churchill- Livingstone. 1993.
3. Madelung O. Die spontane Subluxation der Hand nach vorne, verh. *Dtschges Chir.* 1878;7: 259-276.
4. Nielsen JB. Madelung's deformity. A follow-up study of 26 cases and a review of the literature. *Acta Orthop Scand.* 1977; 48: 379-384.
5. Dawe C, Wynne-Davies R, Fulford GE. Clinical variation in dyschondrosteosis. A report on 13 individuals. *Bone & Joint Journal.* 1982; 64: 377-381.
6. Herdman RC, Langer LO, Good RA. Dyschondrosteosis. The most common cause of Madelung's deformity. *J Pediatr.* 1966; 68: 432-441.
7. Langer LO Jr. Dyschondrosteosis, a hereditary bone dysplasia with characteristic roentgenographic features. *Am J Roentgenol Radium TherNucl Med.* 1965; 95: 178-188.
8. LeriAa WJ. Une affection congenitale et symetrique du development osseus: la dyschondrosteose. *Bull Et MemSocMed D Hop De Paris.* 1929 ; 53: 1491-1494.

9. Vickers D, Nielsen G. Madelung deformity: surgical prophylaxis (physiolysis) during the late growth period by resection of the dyschondrosteosis lesion. *J Hand Surg Br.* 1992; 17: 401-407.
10. Kozin SH, Zlotolow DA. Madelung deformity. *The Journal of hand surgery.* 2015; 40: 2090-2098.
11. Vender MI, Watson HK. Acquired Madelung-like deformity in a gymnast. *J Hand Surg Am.* 1988; 13: 19-21.
12. Casford B. Madelung's deformity.
13. Brashear HR, Raney RB. *Handbook of Orthopaedic Surgery.* 10th ed. St Louis, MO: CV Mosby Co. 1986; 496-497.
14. UW Radiology Main Online Teaching File. Roentgenographic abnormalities in Madelung's deformity.
15. Watson HK, Ryu JY, Burgess RC. Matched distal ulnar resection. *J Hand Surg Am.* 1986; 11: 812-817.
16. Resnick D. Additional Congenital or Heritable Anomalies and Syndromes. In: Resnick D, editor. *Bone and Joint Imaging.* Philadelphia, W.B. Saunders Company; 1996; 1167-1187.
17. Lamb D. Madelung deformity. *J Hand Surg Br.* 1988; 13: 3-4.
18. Brooks TJ. Madelung Deformity in a Collegiate Gymnast: A Case Report. *J Athl Train.* 2001; 36: 170-173.
19. Potenza V, Farsetti P, Caterini R, Tudisco C, Nicoletti S, Ippolito E. Isolated Madelung's deformity: long-term follow-up study of five patients treated surgically. *J PediatrOrthop B.* 2007;16: 331-335.
20. Laffosse JM, Abid A, Accadbled F, Knör G, de Gauzy JS, Cahuzac JP. Surgical correction of Madelung's deformity by combined corrective radioulnar osteotomy: 14 cases with four-year minimum follow-up. *IntOrthop.* 2009; 33: 1655-1661.
21. de Paula EJ, Cho AB, Junior RM, Zumiotti AV. Madelung's deformity: treatment with radial osteotomy and insertion of a trapezoidal wedge. *J Hand Surg Am.* 2006; 31: 1206-1213.
22. Harley BJ, Brown C, Cummings K, Carter PR, Ezaki M. Volar ligament release and distal radius dome osteotomy for correction of Madelung's deformity. *J Hand Surg Am.* 2006; 31: 1499-1506.