JSM Orthopedics and Rheumatology

Case Series

Open Versus Closed Wedge Proximal Tibia Osteotomy In Children with Genu Varum

Tarek Aly*

Department of Orthopedics, Egypt

Abstract

Introduction: During the early years of childhood, genu varum are common concern for parents. These problems represent normal physiologic variations in most children. However, a few children will experience pathologic lower extremity malalignment leading to cosmetic and functional deficits. Proximal tibial osteotomy and hemi epiphysiodesis is the most acceptable procedure in treatment of pathologic genu varum. Variety of techniques have been advocated, the most famous two techniques are closing wedge and bilateral opening wedge high tibial osteotomies.

Patients andMethods: This study included 20 cases with pathologic genu varum treated in the period from January 2015 to May 2016 at Tanta university hospital. Twenty four cases were treated by open wedge high tibial osteotomy technique and 16 cases with closed wedge high tibial osteotomy technique.

Results: In open wedge osteotomy, 16 legs [67%] had good results, 4 legs [16.5%] had fair results and 4 legs [16.5%] had poor results. In closed wedge osteotomy, 12 legs [75%] had good results, 4 legs [25%] had fair results and there were no poor results.

Conclusion: Closed wedge osteotomy was more helpful than open wedge in correction of deformity, and the only benefit of open wedge rather than closed wedge was tibial lengthening after operation.

Keywords: Open; Closed; Wedge; Tibia; Osteotomy

Introduction

Genu varum or bow leg is a common pediatric complaint which is a cause of concern for parents. It is a physical deformity marked by [outward] bowing of the lower leg in relation to the thigh, giving the appearance of an archer's bow [1].

For the one-year to three-years-old child, the differential diagnosis of genu varum includes physiological and pathological genu varum [infantial tibia vara, rickets, trauma, infection and metaphyseal chondroplasia [2].

Physiological genu varum resolves spontaneously with normal growth and development. For persistent genu varum surgical correction in the form of osteotomy of proximal tibial valgus is recommended [3].

Several surgical procedures have been described for the treatment of pathologic genu varum, including proximal tibial osteotomy, hemi epiphysiodesis, asymmetric physeal distraction, and elevation of medial tibial plateau.

There are many types of high tibial osteotomy such as dome, oblique and transverse osteotomy . Most popular two methods are open [medial] wedge and closed [lateral] wedge high tibial osteotomy. High tibial osteotomy with medial opening wedge has gained in popularity over recent years as a viable alternative to traditional lateral closed wedge osteotomy because of short operation time, no risk for neurovascular damage and tibial lengthening. It can be made in patients with open growth plate. It has greater range of correction, leaving longer proximal segment of proximal tibia making it easier for fixation, and more easily performed. The patellar tendon is not affected as the osteotomy is made below its insertion level. Open wedge osteotomy distal to the tibial tuberosity has also some disadvantage as slower bone healing owing to the cortical nature of the bone in this area of the tibia with higher rate of delayed union and its need for fibular osteotomy to get rid of its tethering effect. In closed wedge osteotomy the posterior tibial slope angle is more satisfactory than open wedge osteotomy; also intra operative fixation is more stable with shorter time for bone healing after operation [4].

Advantages and disadvantages in two operation techniques are still controversial.

The aim of this study is to evaluate results, advantages and disadvantages of open wedge compared to closed wedge high tibial osteotomy.

Patients & Methods

This was a prospective randomized control study had been approved by the institution and had therefore been performed in accordance with the ethical standards laid down in the 1964 Declaration of Helsinki. All patients gardians gave their informed consent prior to their inclusion in the study.

Twenty patients with bilateral genu varum, were examined and followed up in the out-patient clinic. The legs were subjected

Submitted: 16 May 2019 | **Accepted:** 22 June 2019 | **Published:** 24 June 2019

***Corresponding author:** Tarek Aly, Department of Orthopedics, Turkey, Tel: 201229754540; Email: elphara3on@gmail.com

Citation: Aly T (2019) Open Versus Closed Wedge Proximal Tibia Osteotomy In Children with Genu Varum. JSM Orthoped Rheumatol 5: 7.

to operative treatment and then followed up for an average duration of 24 months.

Careful history taking and Physical examination were performed to all patients. Laboratory investigation included; serum calcium, phosphorus, alkaline phosphatase, and serum creatinine. Full length standing antero-posterior and lateral radiograph [hip to ankle] were obtained with the knee pointing straight forward.

Inclusion criteria for patients included in this study were: age between 2 years and 4 years with pathological genu varum including; Blount disease, all types of Rickets but after medical treatment for active form of nutritional rickets, no infection or recent trauma, and tibiofemoral angle [Deformity angle] is above 15 degrees.

Twenty four legs were treated by open wedge osteotomy technique and sixteen legs were treated by closed wedge osteotomy. All legs were fixed with two crossing k-wires and above knee cast.

Post-operative care

Dressings changed first time after removal of stitches and then every week, routine x-rays [AP and lateral views] every two weeks, with measuring of deformity angles, no weight bearing in the first 4 weeks and until good bone healing appears in x-rays, after 4 weeks if there is good bone healing, remove k-wires, change the cast for another two weeks and the patient begins to weight bearing, complete bone healing should be achieved within 8 weeks, removal of cast and the patient should have normal gait and the patients were Followed up for at least six months after operation.

All patients were evaluated clinically and radiologically.

Clinical evaluation included:

Tibial length [measured from mid-point in lower border of knee joint to mid-point in upper border of ankle joint], Infection [pin tract infection or superficial wound infection]. Should change dressings every 3 days and look for any infection until stitches and pin removed, and pain [in operative site and knee joint] which was graded as mild, moderate or severe [Mild pain: the patient was aware of the pain but it is very easy to ignore, Moderate pain: uncomfortable but tolerable level of pain in the leg that is noticeable but easy to forget or ignore over time, Severe Pain: excruciating pain that is so intense that the patient are unable to tolerate the level of pain and are seeking stronger medications].

Radiological evaluation included:

Tibio-femoral angle, Metaphyseal diaphyseal angle, Medial proximal tibial angle, and Tibial slope, Bone healing [within 8 weeks post-operative].

Schoenecker's criteria for assessment [5]:

1: good: no pain, <5° difference in deformity angles from the normal value.

2: fair: the same radiographic criteria with occasional pain.

3: poor: pain, restriction of activity and radiological residual deformity.

The results of this study were statistically analyzed using the SPSS 2016 software [IPM]. Arithmetic mean, standard deviation, [T] test, one way analysis of variance [ANOVA], chi-square test, odds ratio, binary logistic regression, and survival analysis were used in analysis. [P-value > 0.05 statistically insignificant].

Results

In this study, Forty legs with pathologic genu varum were treated by high tibial osteotomy operation. Twenty four Legs were treated by open wedge osteotomy technique and sixteen legs were treated by closed wedge osteotomy technique. The patients were followed for minimum 2 years postoperatively.

The age was range from [24 - 48] months old. There was no significant correlation between the age at operation time and the final end result in two operations technique [P=1.00]. In open wedge osteotomy group, male to female ratio was [1:2], and in closed wedge was [3:1]. There was no significant correlation between the sex and the final end result in two operations technique [P=0.17].

In open wedge there are 8 legs with post rickets [67%] and 4 legs with Blount's disease [33%]. In closed wedge all legs were post rickets [100%].P-value was 0.117.

Clinical evaluation

All legs in two types of operation have no pain preoperatively. In open wedge osteotomy group, 6 legs had immediate postoperative mild pain in operation site, disappeared within the first week. In closed wedge osteotomy group, 2 legs had immediate postoperative mild pain in operation site, disappeared within the first week. All legs in the two groups had mild pain after removal of cast and walking but disappeared after 3 days.

In open wedge osteotomy group, the mean tibial length before operation was [18.58 + 1.66 cm] and just after removal of cast was [19.017 + 1.62 cm]. There was increase in tibia length by average [4.5 mm].The tibial length after six months was [19.45 + 1.69 cm] Increased by average 10 mm. and this was found to be statistically significant. [P <0.001]. In closed wedge osteotomy group, the mean tibial length before operation was [18.93 + 1.87 cm] and just after removal of cast was [18.75 + 1.22 cm] .There was decrease in tibia length by average [1.7 mm] .The tibial length after six months was [19.23 + 1.23] .Increased by average [3 mm] and this was statistically significant [P <0.001]. The tibial length was increased after six months due to normal growth of tibia (Table 1).

The final results in tibial length at the end of follow up period in open wedge technique increased by mean of [10 mm] with p-value 0.002, and increased in closed wedge by mean of [3 mm] with p-value 0.01.

Radiological results

All legs in two groups had complete bone healing after 5

Table 1: Tibial length pre, just after removal of cast and after 6 months of operation in open wedge osteotomy group.

	Tibial length	Pre-operative	Post-operative	After six months	Friedman Test [X2]	P- value
Open wedge	Mean ± SD	18.58 ± 1.66	19.017 ± 1.62	19.45 ± 1.69	24	<0.001*
	Wilcoxon Signed Ranks Test [Z]	Pre, post-operative			3.71	0.002*
		Post-operative and after six months			3.089	0.002*

Figure 1a Pre-operative AP view of the leg with genu varum.

Figure 1b Post-operative AP view X-ray after one month show good bone healing of open wedge high tibial osteotomy technique.

weeks (Figures 1,2). Comparison of the mean Pre-operative angles of deformity in two groups [Figure 3]: P-value in comparison between two means of pre-operative tibio-femoral angles in two groups was [0.28, statistically insignificant]. P-value in comparison between two means of pre-operative medial proximal tibial angles in two groups was [0.316, statistically insignificant]. P-value in comparison between two means of pre-operative metaphyseal-diaphyseal angles in two groups was [0.75, statistically insignificant]. P-value in comparison between two means of pre-operative tibial slope angles in two groups was [0.969, statistically insignificant].

1- Tibio femoral angle

Four legs in open wedge osteotomy group had tibio-femoral angles below normal that mean over correction. And 4 legs with residual deformity without any significant difference from pre-operative. All legs in closed wedge osteotomy had post-operative tibio-femoral angles within normal values [Table 2,3].

2- Medial Proximal Tibial angle

All legs with closed wedge osteotomy had medial proximal tibial angles just below normal value [87^0] at the end of follow up period with no residual deformity. Four legs in open wedge osteotomy operation had angles above normal that mean over correction, and 4 legs with residual deformity without any significant difference in angles measures from before operation [Table 2,3].

Figure 1c AP X-ray after 6 months showing complete bone healing.

Figure 2a AP view X-ray Pre-operative with rackitic right genu varum.

Figure 2b AP and lateral X rays after 4 weeks of operation showing good bone healing.

Figure 2c AP X-ray after six months of operation showing complete bone healing.

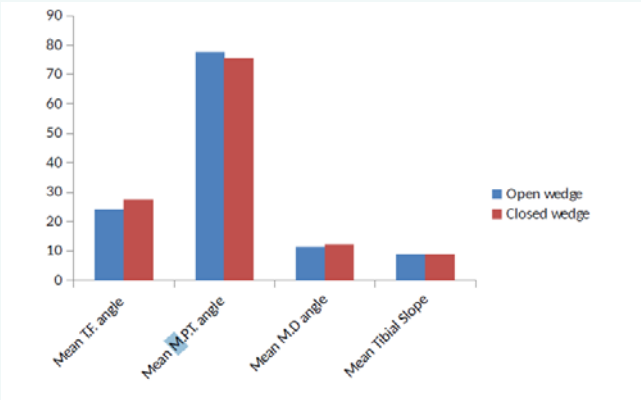

Figure 3 Mean pre-operative angles in two groups.

3- Metaphyseal diaphyseal angle

The normal Metaphyseal diaphyseal angle is [≤ 10^0]. All legs in two groups pre-operative were above [10^0], and post-operative within normal values [Table 2,3].

4- Tibial Slope

The normal tibial slope in children above 2 years is [7^0]. Mean tibial slope increased after open wedge by [2.3 ^{0}], and decreased after closed wedge by [2.6^0] [Table 2,3].

Comparison of the mean Post-operative angles of deformity in two groups [Table 4]: P-value in comparison between two means of post-operative tibio-femoral angles in two groups was 0.33 and this was considered as statistically insignificant]. P-value in comparison between two means of post-operative medial proximal tibial angles in two groups was 0.46 [statistically insignificant]. P-value in comparison between two means of post-operative metaphyseal-diaphyseal angles in two groups was 0.64 [statistically insignificant]. P-value in comparison between two means of post-operative tibial slope angles in two groups was <0.001 [P-value ≤ 0.001 highly statistically significant].

Overall final results of the studied patients using Schoenecker's criteria for assessment:

The clinical results in open wedge osteotomy group were graded as good in 8 legs [67%], fair in 2 legs [16.5%], and poor in 2 legs [16.5%].

The legs in closed wedge osteotomy group were graded as good in 6legs [75%], fair in 2 legs [25%][P = 0.62, statistically insignificant].

Complications

Complications were found in 4 legs [33%] in open wedge osteotomy technique [two legs with residual deformity and 2legs with over correction deformity] and in 2 legs [25%] in closed wedge osteotomy technique [superficial wound infection treated successfully with antibiotics] [P= 1.00, statistically insignificant].

Discussion

Genu varum or bow leg is a common pediatric complaint which is a cause of concern for parents. There are still no generally accepted criteria for initiation of treatment of genu varum. Bracing has often been recommended in children with Langenskiöld stage I or II tibia vara. The effectiveness of the brace is thought to be related to the relief of weight bearing stresses on the medial physeal region of the proximal tibia. as the initial treatment. Older children are best treated with a proximal tibial valgus osteotomy. The goal of the osteotomy is to restore the mechanical axis of the lower extremity. The osteotomy is performed below the tibial tubercle apophysis and is combined with a fibular osteotomy. Efforts to improve the results of tibial osteotomy as treatment of infantile tibia vara in children older than 4 years include physeal-bar resection and lateral proximal tibial hemiepiphysiodesis [6-8].

The literature is replete with techniques for the performance of the tibial osteotomy in severe forms of genu vrum, including

Table 2: Tibial length pre, just after removal of cast and after 6 months of operation in closed wedge osteotomy group.

	Tibial length	Pre-operative	Post-operative	After six months	Friedman Test [X2]	P- value
Closed wedge	Mean ± SD	18.93 ± 1.87	18.75 ± 1.22	19.23 ± 1.23	16	<0.001*
	Wilcoxon Signed Ranks Test [Z]	Pre, post-operative			2.565	0.01*
		Post-operative and after six months			2.565	0.01*

Table 3: pre and post operative radiological measurements of angles in the two groups.

Angles of deformity in cases with open wedge osteotomy	Pre-operative Mean ± SD	Post-operative Mean ± SD	Wilcoxon Signed Ranks test [Z]	P- Value
T.F. angle	24.1± 4.93	8.33 ± 2.91	3.61	0.002*
M.P.T. angle	77.54 ± 1.91	85.667 ± 3.35	3.059	0.002*
M.D angle	11.23 ± 0.9	10.55 ± 3.13	2.121	0.034*
Tibial Slope	8.76 ± 0.56	11.033 ± 0.63	3.064	0.002*
Angles of deformity in cases with closed wedge osteotomy				
T.F. angle	27.23 + 5.97	7.89 + 0.69	2.521	0.012*
M.P.T. angle	75.64 + 3.68	85.71 + 0.74	2.521	0.012*
M.D angle	12.04 + 0.97	9.9 + 0.3	2.521	0.012*
Tibial Slope	8.88 + 0.81	6.39 + 0.74	2.527	0.012*
Statistically significant.				

Table 4: showing Post-operative angles of deformity correction in the two groups.

Post operative angles of deformity	Open wedge [No = 12]		Closed wedge [No = 8]		Mann-Whitney test [Z]	P - value
	Mean ± SD	Range	Mean ± SD	Range		
T.F. angle	8.33 ± 2.91	3.2 – 13.2	7.89 ± 0.69	7 – 8.9	0.968	0.33
M.P.T. angle	85.667 ± 3.35	80.3 – 91.6	85.71 ± 0.74	84.5 – 86.4	0.735	0.46
M.D angle	10.55 ± 3.13	7.7 – 20	9.9 ± 0.3	9.3 – 10.2	0.465	0.64
Tibial Slope	11.033 ± 0.63	10.3 – 12	6.39 ± 0.74	5.4 – 7.3	3.713	<0.001*

various types of internal and external fixation. Regardless of the method of fixation chosen, the goals of surgery are unchanged: correction of the mechanical axis and leveling of the knee joints [9,10].

Many Several surgical procedures have been described for the treatment of pathologic genu varum, including proximal tibial osteotomy, hemi epiphysiodesis, asymmetric physeal distraction, and elevation of medial tibial plateau [11-13].

Acute correction of angular and rotational deformity in Bow leg can be accomplished with a proximal tibial metaphyseal osteotomy. A variety of techniques have been advocated, including closing wedge or opening wedge osteotomies [14].

This study included 20 legs with pathologic genu varum. Twelve legs were treated by open wedge high tibial osteotomy technique and [eight legs] with closed wedge high tibial osteotomy technique. All legs were fixed with k-wires and cast.

The results of the two operative techniques were evaluated clinically and radiologically. In open wedge osteotomy, eight legs [67%] had good results, 2 legs had fair results and 2 legs had poor results. In closed wedge osteotomy, six legs [75%] had good results, 2 legs [25%] had fair results and there were no poor results.

In open wedge osteotomy group, two legs had residual deformity, and two legs had over correction deformity. In closed wedge osteotomy group all legs had good results, there were no change in angles after correction. This means that closed wedge osteotomy is more stable than open wedge. This was against the study done by Luites et al [15] who reported that open wedge osteotomy was more advantageous than the closed technique due to strong stability, shorter recovery time, and higher patient satisfaction.

A prophylactic anterior compartment fasciotomy should be strongly considered for patients who are undergoing acute deformity correction. However, despite the use of such measures, up to one-third of patients can have transient or permanent neurologic injury, which typically presents as weakness of the extensor hallucis longus [16]. Song et al [17], reported the rate of injury to the peroneal nerve during closing-wedge osteotomy was 6.7% but with medial opening-wedge high tibial osteotomy this complication was avoided and no compartment syndrome. All legs in this study in both groups undergo fasciotomy and there

were no any compartment syndrome or neurologic injury [18].

In both groups, all cases had immediate postoperative mild pain in operation site, disappeared within the first week, and had mild pain after removal of cast and walking disappeared after 3 days. According to Schoenecker's criteria for assessment of pain [5] it was good results for all cases.

In this study, mean tibial length was increased by [4.5 mm] just after removal of cast in open wedge and decreased by [1.7] mm just after removal of cast in closed wedge osteotomy.

This was in the line with Bae et al [19] who reported that there was change in tibia length just after opening and closed-wedge high tibial osteotomy. The change for open wedge was considerable while the tibial length change in closed wedge was negligible. The tibia length increased [6.9 mm] just after removal of cast in the opening wedge and was reduced by [0.5 mm] just after removal of cast in closed wedge surgery. The greater the correction in axis was the greater the change in the tibia length.

Several studies discuss the complications associated with high tibial osteotomy. Infections are among the most frequent complications after high tibial osteotomy, ranging [0 to 10%] [17]. In this study, two legs [25%] of closed wedge osteotomy had superficial wound infection. treated with [cephalosporin 3rd generation] antibiotics. There is no infection complication in open wedge osteotomy.

In this study, eight legs in open wedge were males [33%] and sixteen legs were females [67%] with male to female ratio [1:2]. there were eight legs had complications in deformity angles, four for males and four for females. In closed wedge there were twelve males [75%] and four females [25%] with male to female ratio [3:1], four legs for males had superficial wound complication. In both groups there was no relation between sex and complication. This was in the line with Jackson et al [20] that reported no role of patient sex in complication after high tibial osteotomy.

All legs in both groups had tibiofemoral angle pre-operative above [15^0].Four legs in open wedge osteotomy operation had tibiofemoral angles below normal that mean over correction and four legs with residual deformity without any significant difference from pre-operative measures. All legs in closed wedge osteotomy had post-operative tibio femoral angles within normal values. According to Schoenecker's criteria for assessment of tibio-femoral angle [5] four legs in open wedge osteotomy had poor result, four had fair result and sixteen had good result. In closed wedge osteotomy all legs had good result.

All legs in two groups had pre-operative medial proximal tibial angle under [80^0]. All legs with closed wedge osteotomy had medial proximal tibial angles just below normal value t the end of follow up period with no residual deformity. Four legs in open wedge osteotomy operation had angles above normal that mean over correction and four legs with residual deformity without any significant difference in angles measures from before operation. According to Schoenecker's criteria for assessment of medial proximal tibial angle [5], four legs in open wedge osteotomy had poor result, four had fair result and sixteen had good result. In closed wedge osteotomy all legs had good result.

All legs in two groups had pre-operative metaphyseal diaphyseal angles above [10^0], and post-operative within normal values. According to Schoenecker's criteria for assessment of metaphyseal daiphyseal angle [21], all legs in both groups had good results.

All legs in two groups had complete bone healing after 5 weeks. This was in the line with Warden et al [16], who reported normally bone healing completed within 8 weeks.

The mean tibial slope increased by [2.3^0] after open wedge osteotomy operation, and decreased by [2.6^0] after closed wedge osteotomy technique. According to El-Azab et al [22], the posterior tibial slope decreases after closed-wedge and increases after open-wedge high tibial osteotomy. The changes in slope after both methods are stable over time. The degree of correction in the frontal plane does not correlate with the change in slope. A possible explanation for the reduction in the slope after closed-wedge osteotomy is the geometry of the proximal tibia, which is triangular with the apex directed anteriorly. As the wedge is not excised strictly laterally and perpendicular to the anatomical axis, a wedge from the anterolateral part of the proximal tibia results in more bone being removed anteriorly, leading to a reduction in the slope. The explanation for an increase in slope after open-wedge high tibial osteotomy is also anatomical; the anteromedial cortex of the proximal tibia is angulated 45° to the posterior cortex, whereas the lateral cortex is nearly perpendicular to the posterior margin of the tibia. Therefore, a medial opening-wedge osteotomy with equal anterior tibial and posteromedial gaps will increase the tibial slope [22].

In conclusion, Closed wedge and open wedge osteotomy techniques are equally good in correction of deformity. Open wedge high tibial osteotomy does not allow for precise correction of deformation and the only benefit of open wedge rather than closed wedge osteotomy is tibial lengthening after operation while the main benefit of closed wedge osteotomy is increased stability of the osteotomy site.

References

1. Hanson L, Zayer M. Physiological genu varum. Acta orthop scand. 1975; *46:* 221-29.
2. Bateson E. Non-rachitic Bow Leg and Knock-Knee Deformities in Young Jamaican Children. Br. J. Radiol. 1966; 39: 92-101.
3. Young S, Park H, park k. New classification for idiopathic genu varum. Yonesi Med J. 2007; 48: 822-38.
4. Lee D, Byun S. High Tibial Osteotomy. Knee Surg Relat Res. 2012; 24:61-69.
5. Moyad T, Minas T. Opening Wedge High Tibial Osteotomy. J Knee Surg. 2008; 21: 80-84.
6. Schoenecker PL, Meade WC, Pierron RL. Blount's disease: Aretrospective review and recommendations for treatment. *J Pediatr Orthop.* 1985; 5: 181-186.
7. Greene WB: Infantile tibia vara. J Bone Joint Surg Am. 1993; 75: 130-143.

8. Ferriter P, Shapiro F. Infantile tibia vara: Factors affecting outcome following proximal tibial osteotomy. *J Pediatr Orthop.* 1987; 7: 1-7.

9. Beck CL, Burke SW, Roberts JM. Physeal bridge resection in infantile Blount disease. J Pediatr Orthop. 1987; 7: 161-163.

10. Siffert RS. Intraepiphyseal osteotomy for progressive tibia vara: Case report and rationale of management. J Pediatr Orthop. 1982; 2: 81-85.

11. Sung K, Yong M. Medial opening wedge high-tibial osteotomy using a kinematic navigation system versus a conventional method. Knee Surg Sports Trauma Arthrosc. 2009; 17: 128-134.

12. Feldman MD, Schoenecker PL. Use of the metaphyseal-diaphyseal angle in the evaluation of bowed legs. J Bone Joint Surg Am 1993; 75: 1602-1609. 8-Brooks W, Gross R. Genu Varum in Children: Diagnosis and Treatment. *J.*Am Acad Orthop Surg. 1995; 3: 326-335.

13. Hagstedt B, Norman O, Olsson T. Technical Accuracy in High Tibial Osteotomy for Gonarthrosis; Acta orthop Scand. 1980; 51: 963-970.

14. Luttis JW, Brinkman JM. Fixation stability of opening- *versus* closing wedge high tibial osteotomy. J. Bone Joint Surg. 2009; 91: 1459-1465.

15. Flierl S, Sabo D, Hornig K, Perlick L. Open wedge high tibial osteotomy using fractioned drill osteotomy: Surgical modification that lowers the complication rate. Knee Surg Sports Traumatol Arthrosc. 1996; 4: 149-153.

16. Song E, Seon J, Park S, Jeong M. The complications of high tibial osteotomy: closing- versus opening-wedge methods. J Bone Joint Surg Br. 2010; 92: 1245-1252.

17. Matsen F, Staheli L. Neurovascular complications following tibial osteotomy in children. A case report. Clin Orthop. 1975; 110: 34-45.

18. Bae DK, Song SJ, Kim HJ, Seo JW. Change in limb length after high tibial osteotomy using computer-assisted surgery: a comparative study of closed- and open-wedge osteotomies. Knee Surg Sports Traumatol Arthrosc 2013; 21: 120-126.

19. Jackson J, Waugh W. The technique and complications of upper tibial osteotomy. J Bone Joint Surg. 1974; 56: 236-245.

20. Warden SJ, Morris HG, Crossley KM. Delayed- and non-union following opening wedge high tibial osteotomy: Surgeons results from 182 completed cases. Knee Surg Sports Traumatol Arthrosc. 2005; 13:34-37.

21. El-Azab H, Halawa A, Anetzberger H, Imhoff A, Hinterwimmer S. The effect of closed and open-wedge high tibial osteotomy on tibial slope: a retrospective radiological review of 120 cases. J Bone Joint Surg. 2008; 90-B: 1193-1197.