

Deep-Seated Lipomas of the Upper  
Extremity in Tunisia - A Case Series and  
Literature ReviewImene Miniaoui<sup>1</sup>, Zeineb Alaya<sup>2\*</sup>, Mehdi Jedidi<sup>3</sup>, Lassad Hassini<sup>3</sup>, Meriem Braiki<sup>4</sup>,  
Elyès Bouajina<sup>2</sup> and Walid Osman<sup>3</sup><sup>1</sup>Department of Internal Medicine, University College Hospital Farhat Hached, Tunisia<sup>2</sup>Department of Rheumatology, University College Hospital Farhat Hached, Tunisia<sup>3</sup>Department of Orthopedic Surgery, University College Hospital Sahloul, Tunisia<sup>4</sup>Department of Pediatric Surgery, Fattouma Bourguiba Hospital, Tunisia

## Article Information

Received date: Aug 17, 2017

Accepted date: Aug 31, 2017

Published date: Sep 05, 2017

## \*Corresponding author

Zeineb Alaya, Department of  
Rheumatology, Farhat Hached Hospital,  
Faculty of medicine of Sousse, Ibn el  
Jazzar Street, 4000 Sousse, Tunisia,  
Tel: +21698375975;  
Email: zeineb\_a@hotmail.fr

Distributed under Creative Commons  
CC-BY 4.0

**Keywords** Deep-seated lipomas; Upper  
limb; MRI; Surgery; Complications

**Article DOI** 10.36876/smjar.1002

## Abstract

**Background:** Lipomas are the most common soft-tissue tumors and may appear at any site. The usual presentation is as a solitary, slow-growing and painless subcutaneous tumor. Deep-seated, intra- and extra-muscular lipomas are less common and are larger than subcutaneous lipomas. Our objectives were to study the clinical and radiological characteristics and treatment of Tunisian Deep-seated lipomas of the upper extremity patients and review the literature.

**Methods:** A retrospective study of all patients with deep-seated lipomas of the upper extremity, treated surgically between 1990 and 2011, was carried out. Clinical and radiological characteristics, treatment, and evolution profile of these patients were also evaluated. Patients were followed for 5 years.

**Results:** Twenty three patients were identified. There were 17 women and 6 men. The mean age of patients was 45 years (range 25 to 80 years). Eight of these lipomas were in the arm, eight in the shoulder, three in the hand, three in the forearm and one in the elbow. Standard radiography, ultrasonography, Computer Tomography (CT) or Magnetic Resonance Imaging (MRI) suggested the lipomatous nature and benign characteristics of these deep lipomas. Lipoma marginal excision was performed and histopathological examination demonstrated features of benignity. There were two intramuscular lipomas, two angioliipomas and nineteen lipomas. There was no recurrence after the surgery.

**Conclusion:** All deep-seated lipomas are found to have infiltrative property, but variations may arise concerning their growing patterns and direction. It may wrap around nerves thus a careful dissection is needed in order to avoid severe damage.

Level of evidence: IV.

## Introduction

Lipomas are the most common soft tissue tumor [1]. Lipomas can occur in many locations, most commonly in the subcutaneous tissues; this kind of benign tumor creates no problem as it can easily be removed [1]. In contrast to the common superficial lipomas that occur in the subcutaneous tissues, deep-seated lipomas are those that occur deep to the investing fascia. They may vary in size and some cases reported are giant, defined as greater than 5 cm diameter [2]. These types of lipomas are considered uncommon and those involving the fingers are very rare, with reported incidence of 1% [3]. The large size increases the possibility of encasement of neurovascular bundle and nerve compression. Extra care is therefore needed during the operating process in order to prevent damaging nerves.

## Patients and Methods

A retrospective study of all patients with deep-seated lipomas of the upper extremity, treated surgically between 1990 and 2011, was carried out. Clinical and radiological characteristics, treatment, and evolution profile of these patients were also evaluated. Patients were followed for 5 years. We have obtained IRB approval and we have formal consent from patients for this study and for publishing their photos.

## Results

Twenty three patients were identified. The mean age of patients was 45 years (range 25 to 80 years). There were 17 women and 6 men. The most common sites were the arm and the shoulder (eight lipomas), followed by the forearm and the hand (three lipomas) and the elbow (one lipoma). Patients are generally elderly, fat, and the risk of malignancy of deep-seated lipomas is rather high. Clinical examination has its limitations, as it is not certain whether the lipoma is benign. Therefore, we recommend the patients to undergo standard radiology, ultrasonography, CT or MRI to check

**OPEN ACCESS**

**ISSN: 2637-8841**

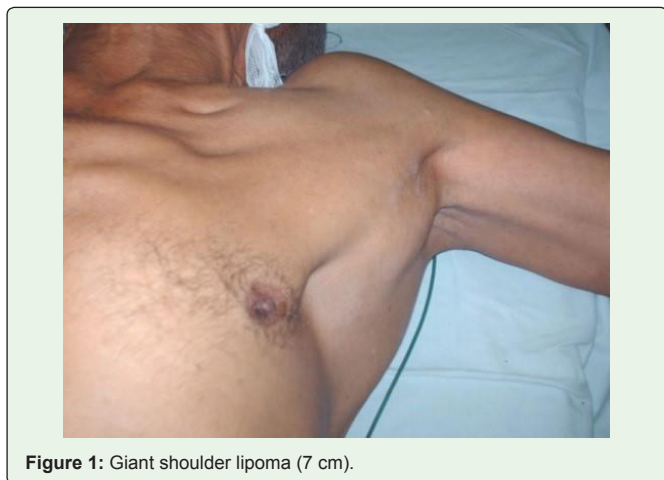

Figure 1: Giant shoulder lipoma (7 cm).

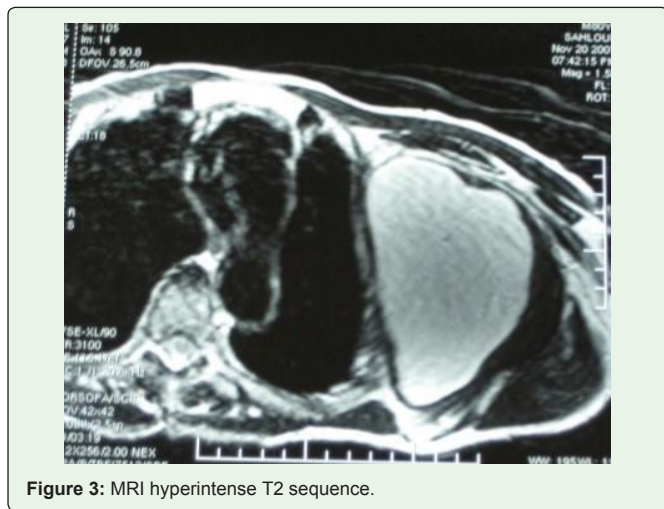


Figure 3: MRI hyperintense T2 sequence.

the extent and the nature of the lipoma. The mean interval between the beginning of symptoms and the surgical treatment was 28 months (range from 5 to 84 months). There were two intramuscular lipomas (one deltoid muscle, one biceps), two angioliopomas (forearm, finger) and nineteen lipomas (7 lipomas in the shoulder, 7 lipomas in the arm, 2 lipomas in the hand, 1 lipoma in the elbow and one lipoma in the forearm). All patients presented with soft-tissue mass that was painless in 18 cases, associated with paresthesia of the fingers in two cases (one angioliopoma of the finger and one lipoma of the hand compressing the ulnar nerve). One patient presented an elbow mass with compression signs of the cephalic vein and venous stasis. A patient with giant shoulder lipoma (7 cm) presented an enormous mass with limitation of abduction secondary to brachial plexus deficit and compression of the axillary vascular pedicle (Figures 1- 4). Only one patient presented a carpal tunnel syndrome, he had a lipoma of the hand that compressed the median nerve.

Radiography was performed in all patients. It has objectified a clear picture in soft tissue with clear contours in six cases. A thickening of soft tissues was observed in 10 cases. Radiographic examination was considered normal in 7 cases. Ultrasonography demonstrated a homogeneously hyperechogenic mass in 10 cases. In

five cases it was echogenic structure traversed by fibrous spans. In 2 cases it was described as a poorly defined heterogeneous mass crossed by hyperechoic streaks. CT was performed in nine patients; our cases displayed the typical CT aspect of lipomas, consisting of a well-limited mass with fat density (between -65 and -100 HFU). In our series five patients underwent MRI; lipomas showed homogeneity on T1- and T2-weighted images with high signal on T1-weighted sequences, intermediate or high on T2-weighted sequences and low signal on fat-suppressed T1- weighted sequences (Figures 2 and 3). The two cases of angioliopoma showed heterogeneous enhancement visualized especially at the peripheral part of the lesion.

All lipomas were extirpated surgically by marginal resection (Figure 4). Four of the lipomas were adjacent to neurovascular bundle (one with the brachial plexus and the axillary vascular pedicle, one with the median nerve another with the ulnar nerve and one with the cephalic vein). It needed careful dissection to avoid injuring nearby neurovascular structures. Lipomas had a mean size of 8 cm ranging from 3 to 22 cm. All the lipomas had a well-defined border. None had complications or recurrence at a mean of 3 years follow-up (range: 2 to 5 years) after resection.

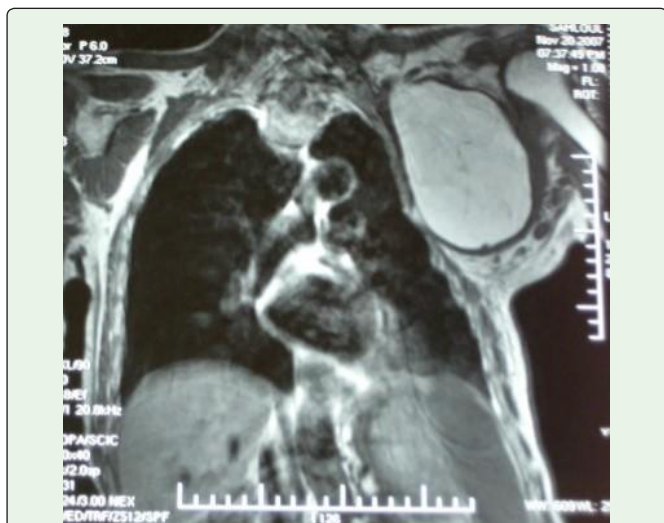

Figure 2: MRI hyperintense T1 sequence.

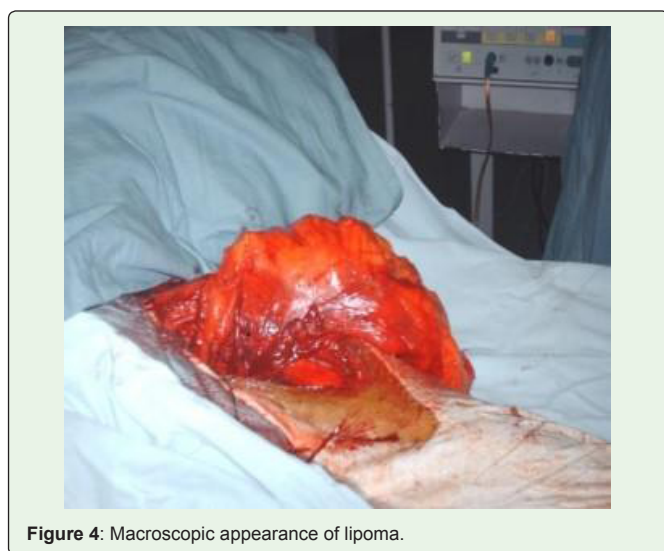


Figure 4: Macroscopic appearance of lipoma.

## Discussion

Deep-seated lipomas are most commonly discovered between the ages of 30 and 60 [4]. Unlike our study, men are more affected than women [5]. This most probably suggests the statement that deep-seated lipomas tend to appear in the middle to late decades of life when fat begins to accumulate to form a lipoma inside the body. They generally grow slowly and may sometimes infiltrate deeply and wrap around nerves. They usually appear as large size at diagnosis and create pressure on the nerves, particularly if located deeply. The patient will, therefore, experience a painful feeling and a swelling on his upper limb. Deep lipomas can be located in any part of the body. The most common sites for intramuscular lipomas in the upper limb are the shoulder and upper arm while intermuscular lipomas are usually located in the forearm [6]. Clinically, intramuscular lipomas are most of the time discovered during investigation of a chronic swelling. Other symptoms depend on the location and the volume of the tumor and are secondary to local compression on adjacent nerves [7]. This suggests that cases of nerve compression by lipoma can sometimes be very complex. Although the chance of getting into such complicated case is rare, (like the four cases of our series) extra attention should always be put when cases involving compression of nerves are encountered. Nerve damage due to retraction during the dissection process may result in chronic nerve pain. In the shoulder, deep lipomas can cause pain [8], brachialgia [9] or limitation of joint movement [10] as in our observation of the intramuscular lipoma of the shoulder. While deep lipomas of the wrist can generate carpal tunnel syndrome, deep lipomas of the Guyon's canal can cause an ulnar neuropathy. In the hand, deep lipomas may cause mechanical dysfunction and altered sensitivity [11,12].

Imaging features of benign lipomatous lesions are most of the time specific [13]. Plain radiographs of deep lipomas show usually a radiolucent mass. Deep lipomasechogenicity is non-specific; they could be hyperechogenic, isoechogenic or hypoechogenic [13]. CT suspects the diagnosis of deep lipoma showing usually a well-circumscribed mass, hypodense on CT (between -65 Hounsfield and -120 Hounsfield) and there is no enhancement of the lipomatous component after the administration of intravenous contrast material. MRI is better than CT in evaluating lipomatous mass extension [6]. On MRI [14], deep lipomas are usually identified as homogeneous masses with high fat signal (bright) on T1-weighted images and intermediate on T2-weighted images, and low signal (dark) on fat-suppressed T1-weighted sequences. Deep lipomas do not enhance after the administration of intravenous gadolinium. In our series, MRI was used for local staging in five cases, as this has been shown to be an accurate diagnostic technique for this kind of tumor. This showed comparable results with the literature that MRI gave the correct diagnosis in 94 % of cases in a study of 134 patients [2].

The main differential diagnosis of deep lipomas is liposarcomas. The most important signs of malignancy shown by MRI are tumor heterogeneity, irregular septas, incomplete STIR suppression and large size. The non-lipomatous components show high signal after gadolinium injection on fat-suppressed T1-weighted images. Surgical biopsy of unhomogeneous deep lipomas is recommended to decide between the two diagnoses.

The treatment of choice of deep lipomas remains the complete surgical marginal excision [15] which requires a very extensive

and careful dissection in order to spare vessels and nerves that are located nearby. In some cases where the deep lipoma encases the neurovascular bundle and the removal of lipoma is thus incomplete the likelihood of recurrence is very increased [13]. The prevalence of local recurrence of deep lipomas has been estimated at 4-5 %, and it occurs more frequently with infiltrating lipomas. There are always difficulties concerning dissection of deep-seated lipomas. It may likely cause traction injury to the nerve, resulting in neuralgia [16].

## Conclusion

This compromise between adequate surgical margins and functional disability may lead to incomplete resection and higher local recurrence rate. In contrary to infiltrative lipoma, benign circumscribed deep lipoma has a low recurrence rate. This study not only describes the general features of deep-seated lipoma in 23 patients, but also emphasize that complications may still arise although this entity is rare.

## References

- Fletcher CD, Martin-Bates E. Intramuscular and intermuscular lipoma: neglected diagnoses. *Histopathology*. 1988; 12: 275-287.
- Cribb GL, Cool WP, Ford DJ, Mangham DC. Giant lipomatous tumours of the hand and forearm. *J Hand Surg Br*. 2005; 30: 509-512.
- De La Cruz Monroy MF, Durani P, Offer GJ. Unusual case of finger lipoma: a case report and literature review. *J Plast Reconstr Aesthet Surg*. 2015; 68: 284-286.
- Elbardouni A, Kharmaz M, Salah Berrada M, Mahfoud M, Elyaacoubi M. Well-circumscribed deep-seated lipomas of the upper extremity. A report of 13 cases. *Orthop Traumatol Surg Res*. 2011; 97: 152-158.
- Kransdorf MJ. Benign soft-tissue tumors in a large referral population: distribution of specific diagnoses by age, sex, and location. *AJR Am J Roentgenol*. 1995; 164: 395-402.
- Nishida J, Morita T, Ogose A, Okada K, Kakizaki H, Tajino T, et al. Imaging characteristics of deep-seated lipomatous tumors: intramuscular lipoma, intermuscular lipoma, and lipoma-like liposarcoma. *J Orthop Sci*. 2007; 12: 533-541.
- Leffert RD. Lipomas of the upper extremity. *J Bone Joint Surg Am*. 1972; 54: 1262-1266.
- Warner JJ, Madsen N, Gerber C. Intramuscular lipoma of the deltoid causing shoulder pain. Report of two cases. *Clin Orthop Relat Res*. 1990; 253: 110-112.
- Sergeant G, Gheysens O, Seynaeve P, Van Cauwelaert J, Ceuppens H. Neurovascular compression by a subpectoral lipoma. A case report of a rare cause of thoracic outlet syndrome. *Acta Chir Belg*. 2003; 103: 528-531.
- Le Huec JC, Leger O, Schaevebeke T, Moinard M, Rupp L, Le Rebeller A. Deep muscular lipoma of the shoulder. Apropos of 4 cases. *Rev Chir Orthop Reparatrice Appar Mot*. 1996; 82: 263-267.
- Oster LH, Blair WF, Steyers CM. Large lipomas in the deep palmar space. *J Hand Surg Am*. 1989; 14: 700-704.
- Singh V, Kumar V, Singh AK. Case report: A rare presentation of Giant palmar lipoma. *Int J Surg Case Rep*. 2016; 26: 21-23.
- Murphey MD, Carroll JF, J Flemming D, Pope TL, Gannon FH, Kransdorf MJ. From the archives of the AFIP: benign musculoskeletal lipomatous lesions. *Radiographics*. 2004; 24: 1433-1466.
- Kransdorf MJ, Bancroft LW, Peterson JJ. Imaging of fatty tumors: distinction of lipoma and well-differentiated liposarcoma. *Radiology*. 2002; 224: 99-104.

15. Billing V, Mertens F, Domanski HA, Rydholm A. Deep-seated ordinary and atypical lipomas: histopathology, cytogenetics, clinical features, and outcome in 215 tumours of the extremity and trunk wall. *J Bone Joint Surg Br.* 2008; 90: 929-933.
16. Nishida J, Shimamura T, Ehara S, Shiraishi H, Sato T, Abe M. Posterior interosseous nerve palsy caused by parosteal lipoma of proximal radius. *Skeletal Radiol.* 1998; 27: 375-379.