

Recent Advancements in Diagnostic Aids
in Orthodontics - A ReviewAshish Kakadiya¹, Ragni Tandon², Aftab Azam², Rohit Kulshrestha^{3*} and Madhvi Bhardwaj⁴¹Consulting Orthodontist, Private Practice Surat, India²Department of Orthodontics and Dentofacial Orthopedics, Saraswati Dental College, India³Consulting Orthodontist, Private Practice, Mumbai, India⁴Department of Orthodontics and Dentofacial Orthopedics, Career PG Institute of Dental Sciences, India

Article Information

Received date: Aug 05, 2017

Accepted date: Aug 30, 2017

Published date: Sep 05, 2017

*Corresponding authors

Rohit Kulshrestha, Consulting
Orthodontist, Private Practice,
Mumbai, India, Tel: +918601462462;
Email: kulrohit@gmail.comDistributed under Creative Commons
CC-BY 4.0Keywords CBCT; Digital models;
Diagnostic aids

Article DOI 10.36876/smd.1016

Abstract

Every medical, dental and surgical procedure is solely based on the diagnosis of the underlying pathology or disorder. In recent times there has been a tremendous advancement in scientific technology which has helped dental practitioners all over the world. The use of computers in cephalometry has made it easier to view and measure various readings. Computer aided design and computer aided manufacturing have increased the accuracy and quality of all dental materials. In the field of Orthodontics, there have been many advances. This article summarizes the recent advancements in diagnostic aids in Orthodontics which has helped revolutionize treatment planning for the Orthodontic fraternity.

Introduction

Recent advances in diagnostic aids address a special aspect of orthodontic diagnosis and treatment planning that has become increasingly, important in our litigious society [1]. Successful orthodontic treatment is dependent on the disciplined approach to record taking and diagnosis as well as careful monitoring of progress in treatment, an inadequate record may be reflective of a poor standard of treatment. The essentials for orthodontic records are a diagnostic report supported by study models, radiographs and photographs to establish the condition of the case before treatment and to record progress during treatment. The problem oriented dental records significantly aids in making the appropriate diagnosis. There is a significant improvement over the morphologically oriented diagnostic methods. The orthodontist's job is to fit the pieces of the human craniofacial complex puzzle together. The expected outcome of this endeavour is a harmonious rearrangement that is not only functional but also aesthetically pleasing. Clearly, this process must take into account the relationships in all three special axes. Oddly enough, while orthodontic treatment affects all three dimensions, many of the current tools of diagnosis employ only a Two Dimensional (2D) representation of the patient. The two goals of orthodontic treatment (function and aesthetics) are dynamic entities. The statically occluded teeth are of limited value, though they might look good in the form of a plaster cast. This is no different than the good-looking and the not so-good-looking, giving at least one pose to the photographer where they would appear aesthetically pleasing. In the absence of a system where function and aesthetics can be assessed, both the orthodontist and the patient are left to imagine or fantasize, rather than know, what the treatment outcome might be [2].

The development of integrated 3D tools for diagnosis and treatment planning is one of the most exciting developments in orthodontics as the specialty moves into the 21st century. The development of Computed Tomography (CT) and Three-Dimensional (3D) reconstruction in the 1970's brought about a revolution in diagnostic radiology because cross-sectional imaging became possible. By the late 1980's, 3D reconstruction algorithms were more optimized, and three-dimensional image reformatting of standard 2D CT data (3D CT) became an often used tool to provide the radiologist and surgeon with readily recognizable images of complex anatomic structures such as the skull. These techniques can exactly record and represent the life-size and shape of the object. Three-dimensional visualization with proper computer software and environment can be used for diagnosis, surgical planning, and simulation of operation. Developing such a computer system naturally combines knowledge from medicine, dentistry, biomedical engineering and computer science [3].

The practice of orthodontics has been transformed by the computer revolution of the 1990's. Digital orthodontics has created a paradigm shift in practice management. The orthodontic practice of the 1970's and 1980's can be seen in high contrast to the dynamic practices of the new millennium. With treatment records always at the orthodontist finger tips, orthodontic treatment has streamlined and patient management has reached levels of sophistication never before possible. The internet and the development of high-speed communication modalities have enabled group practices, with multiple locations, to access records in outlying locations electronically. This paradigm shift will

OPEN ACCESS

ISSN: 2575-7776

propel orthodontics well into the future [4]. As computers became more dynamic and reliable, orthodontic practitioners started to use computers unique strengths mostly to help in diagnosis and treatment planning. The key element in orthodontic treatment remains a skilled orthodontic specialist with an understanding of the biological and biomechanical knowledge base that our specialty has painstakingly acquired in more the 100 years of collective experience in treatment and research [5]. The purpose of this article was to review the recent diagnostic aids which help the Orthodontist in treatment planning.

Cone Beam Computed Tomography

Craniofacial CBCT were developed to counter some of the limitations of conventional CT scanning devices. In craniofacial CBCT the object to be evaluated is captured as the radiation falls onto a two-dimensional retractor. This simple difference allows a single rotation of the radiation source to capture an entire region of interest as compared to conventional CT device where multiple slices are stacked to obtain a complete image. The cone beam also produces a more focused beam and considerably less scatter radiation compared to conventional fan shaped CT devices (Figure 1).

This significantly increases x-ray utilization and reduces the x-ray tube capacity required for volumetric scanning. It is said that radiation exposure is 20% of conventional CT or equivalent to full mouth peri-apical radiographic exposure [5].

Advantages of CBCT

- Less cost
- Smaller in size
- Exposure chamber (head) is custom built and reduces the amount of radiation
- Images are comparable to conventional CT and are displayed as full head view, as skull View or as regional components [6,7].

Clinical Applications in Orthodontics

With CBCT Orthodontists have many images that are not possible with conventional radiographic measures.

- Impacted teeth and oral abnormalities
- Airway analysis
- Assessment of alveolar bone height and volume
- TMJ morphology
- Lateral and frontal Cephalogram views
- Skeletal views
- Facial analysis
- 3D review of dentition [8]

Radiation Exposure

CBCT provides three-dimensional images with up to four times less radiation than a conventional CT scan. The resultant radiation is dependent on the settings used (Kvp and mA). The use of lower mA and/or collimation are some of the ways to reduce the amount of radiation the patient receives, but at the same time produces lower

image quality than by using higher settings. The patient's effective exposure from a resultant CBCT is as low as 45 μ Sv to as high as 650 μ Sv. Full mouth radiographs produce an exposure of 150 μ Sv and a round trip from Tokyo to Paris is about 135 μ Sv of exposure. The ADA Council on scientific affairs recommends the use of techniques that would reduce the amount of radiation received during dental radiography known as the ALARA principle (as low as reasonably achievable). This includes taking radiographs based on the patient needs, using the fastest film compatible with the diagnostic task, collimating the size of the beam to as close the size of the film as feasible and using lead aprons and thyroid shields.

Digital Cephalometry

In 1922, Pacini described a rather primitive method for standardization of radiographic imaging of the head. He recommended positioning of the subject at a fixed distance of 2m from the x-ray source with a film cassette fixed to the head with a wrapping of gauze bandages [8,9]. Almost a decade later in 1931, Broadbent and Hoffarth (The United States and Germany) simultaneously published their own methods of obtaining standardized lateral head radiographs. Their methods published in the *Angle Orthodontist* in 1937, introduced the field of cephalometry to the orthodontic community.

Cephalometry is a vital tool in orthodontic for evaluation of craniofacial complex, determination of morphology and growth, diagnosis of anomalies forecasting future relationship, planning treatment and evaluating the results of growth and effects of treatment. Cephalometrics remains the only quantitative method that permits investigation and examination of the spatial relationship between both cranial and dental structures. The lateral cephalogram provide information regarding skeletal, dental, and soft tissue morphology as well as relationship between these structures [10].

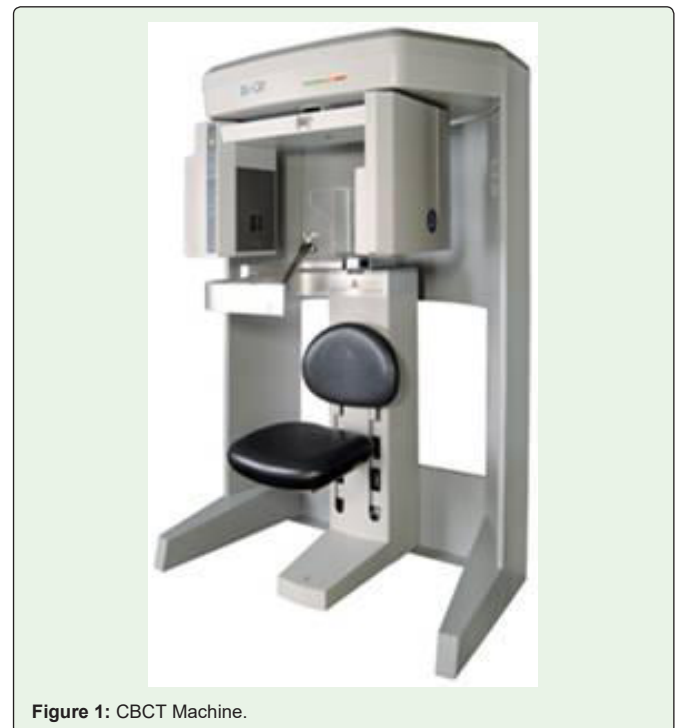

Figure 1: CBCT Machine.

The use of lateral cephalograms in research includes -

- Quantifying craniofacial parameters in individuals as well as a population of individuals
- Distinguishing normal from abnormal
- Comparing treated samples to untreated controls
- Differentiating populations as homogenous or mixed, and assessing the change of pattern over time

Since its advent in 1931, conventional cephalometry has remained unchanged. Digital radiography has been accepted in the dental community, but high cost delayed their progress. Recently with the development of cost effective radiography (extra oral) and increased utilization of computers in orthodontics has made digital cephalometric imaging a viable option. The paradigm shift is occurring in orthodontics from the widely accepted film based to digital cephalometry. The methodology and various techniques for the development of digital cephalograms are the same procedure as described earlier for digital radiography. To accept this scientific description various studies are being carried out to accept the reliability of these digital cephalograms (Figure 2).

Rudolph et al. [11] compared the reliability of digital and conventional cephalometric radiographs in terms of landmark identification error. They concluded similar reproducibility and precision in landmark identification using both direct digital and conventional lateral cephalometric head films. Heiko vesser et al. [12] studied and compared the radiation exposure and dose between conventional cephalometry and digital cephalometry. They concluded that digital cephalometric radiography cuts the radiation dose in half compared with the conventional screen film technique and that digital cephalometry is more advantageous than conventional cephalometry in that perspective. Jia Kuing Liu et al. [13] studied the accuracy of computerized identification of landmarks using various angular and linear measurements. They concluded that computerized identification of certain landmarks is questionable and further studies are needed to confirm their accuracy. Geelen et al. [14] studied the reproducibility of cephalometric landmarks on conventional film, hard copy and monitor displayed images obtained by a storage phosphor technique. They concluded that there was no clinically significant difference in landmark identification among the various methods.

A plethora of software's is available to clinician to choose from -

- Vistadent
- Dolphin
- Quick ceph
- Dentofacial Planner
- Vixwin software
- Dr ceph
- Ortho plan
- Ceph x
- Orthoview ceph

Factors to be considered before going to purchase software are -

- Facility of integration of photographs and study models
- Windows based system available
- DICOM compatibility
- Lateral as well as postero-anterior analysis should be possible

Softwares Developed in India

Digiceph

Method for computerized digitization analysis and superimposition

- 13 cephalometric analysis
- Developed by the center for Bio-Medical Engineering, IIT Delhi and Dept of Dental Surgery AIIMS

Digital Imaging and Communications in Medicine (DICOM)

American College of Radiology (ACR) and the National Electrical Manufacturers Association (NEMA) formed a joint committee in order to create a standard method for transmission of medical images and their associated information. DICOM defined information standardized not only for images but also for patients, students, reports and other data groupings. With the enhancement made in DICOM (version 3.0) came the development and expansion of picture archiving and communication system and its interfacing medical information systems.

Digital Study Models

Study models have long been an essential part of the orthodontic process. They have traditionally been cast out of either plaster or stone and have served two main purposes:

- To provide information for diagnosis and treatment planning
- To provide a 3D record of the original malocclusion, any stages during correction and outcome of the treatment [15,16].

Although study models are almost indispensable to the orthodontist, because they are cast in plaster or stone, they do have a number of drawbacks in terms of:

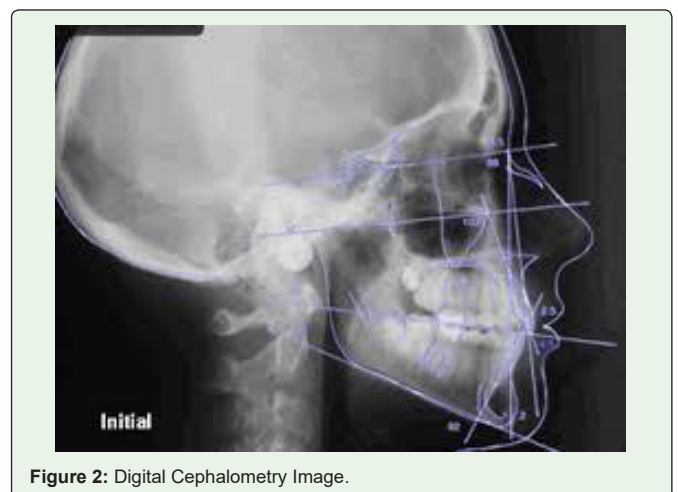


Figure 2: Digital Cephalometry Image.

- Storage and retrieval;
- Diagnostic versatility;
- Transferability;
- Durability.

The introduction of digital models offers the orthodontist an alternative to plaster study models routinely used. The digital study models overcome most of the drawbacks of plaster study models in addition to being the last component of a fully electronic patient chart (with digital photography and digital radiography already in use). This computerized system opens a new realm of orthodontic diagnosis (Figure 3).

Procedure [17]

There are two basic methods of producing digital study models:

Destructive imaging: Removes part of a cast, little at a time, while it is being imaged.

Non-destructive imaging: uses structured light, laser light, or x-ray to an image while leaving the original cast intact.

Two successful companies in producing high-quality 3-D models are: -

- Orthocad [16,18]
- Geodigm [17]

Orthocad

The Orthocad digital study model capture, assessment, and storage system are used by approximately 10% of the orthodontists in USA and Canada [16]. This software has been developed by CADENT (computer aided dentistry, Fairview, NJ, USA.). They use state of the art computer-aided design to optically scan in the model image from a plaster equivalent. These are then presented to orthodontist through the patent orthocad software user interface that allows both structured and free manipulation of models in virtual space, and data collection through a range of diagnostic tools.

Procedure

High-Quality Impressions: It is essential to take high-quality impressions and a bite registration. The impressions can be taken in high-quality alginate, polyvinyl silicone or polyether material. The aim is to produce impressions that are extremely accurate and dimensionally stable. The alginate impressions are then sanitized wrapped in lamp paper towel and placed in sealable plastic bags to ensure retention of moisture. The impressions are then shipped and in a case of longer periods for shipping and storage polyether materials may be used.

Scanning of impressions

When the impressions are received, they are converted to plaster equivalents and optically scanned without destruction of plaster equivalent into the Orthocad computer system. Then the patient's virtual 3-D models are downloaded to your computer [19].

Manipulation of virtual models

Manipulation of virtual models is possible by using the Orthocad proprietary software and the virtual 3-D images are downloaded from the main server by the account holder.

Static views from any perspective

Orthocad three-dimensional browsers allow five simultaneous views of models, thus allowing them to be examined from five different perspectives instead of having to rotate a particular view [16,18].

Grab and drag manipulation in all planes of space

The jaw alignment tool enables the clinician to fine tune occlusion in case wax bite has distorted. The relationship of jaw can be recorded anteroposteriorly, between the limits of centric relation and centric occlusion and software remember this relationship.

Occlusogram views highlighting occlusal contacts

The computer-generated occlusogram has a colour scheme that portrays tightness of contact points between jaws, essentially simulating wax bite width between articulating maxillary and mandibular teeth. The occlusogram changes if either jaw is moved laterally or vertically [20]. Occlusal information is important for both initial diagnoses i.e. open versus deep bite, high versus low mandibular plane angle and for assessment of jaw function. Furthermore, a comparison of pre and post treatment occlusograms can help evaluate treatment methodology and stability of results.

Transverse and vertical sectioning

Unlike plaster procedures, digital models can be sectioned any time in the sagittal or transverse plane. This may shed a new light on dental and skeletal asymmetries and can help pinpoint skeletal and dental midlines.

Diagnostics

Measurements are made with a virtual caliper and automatically stored. Various analysis like tooth width measurements, space assessment, Moyers and Tanaka-Johnston prediction, Bolton

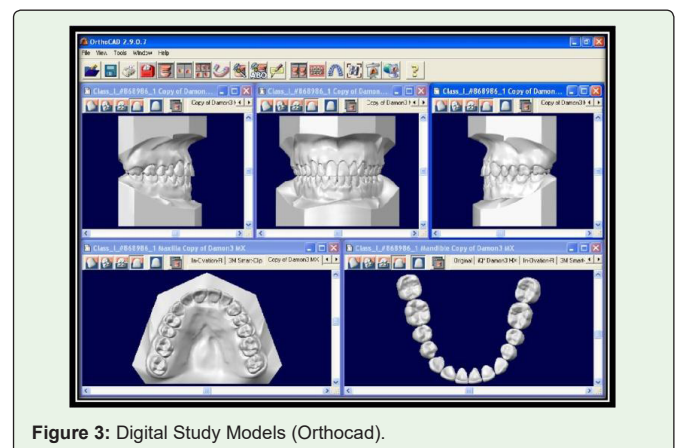


Figure 3: Digital Study Models (Orthocad).

analysis, arch width measurements can be made. The virtual caliper allows any section of the model to be measured within 100 microns (0.1 mm). These are then calculated along with arch form and arch size to give space discrepancy. All contact points and measurements are saved with Individual patient folder into which the digital model is also incorporated for future references. They can also be e-mailed to fellow dentists and other health professionals along with notes, views, and measurements.

Advantages

- It is a simpler and more effective way of measuring and storing data received from a virtual model
- Ease of storage and integration into the patient’s digital file along with digital photographs, X-ray, and clinical notes
- Retrieval and viewing along with the patient’s other clinical data can be done at chair side
- Can be transferred to other healthcare personnel via prints or e-mail attachment

Disadvantages

- Virtual models cannot be mounted and articulated in reference to patients TMJ functions, although jaw alignment tool comes close to this
- The models are expensive and cost about 36\$ per set of models and shipping costs about 55\$
- Time-consuming
- The main reason why only 10% of orthodontists use it is that the legal acceptance of digital study models is still questionable

Orthocad could revolutionize the way in which study models are viewed, managed and stored. The ability to rotate, tilt and section models, and hold them in any position, allows for detailed analysis, with added advantage of bringing models up instantly with other clinical information, chair side. In an era of electronic patient records, when all patient information is stored digitally, commercially available digital model systems, such as orthocad will soon be the norm.

Geodigm

Geodigm E-models are constructed through a proprietary laser scanning process, that digitally maps the geometry of patient’s anatomy into a high dimensional 3-D image, with an accuracy of 0.1 mm. Scanners project a laser stripe on the surface of the cast and use digital cameras to analyze distortions in the stripe. The cast is oriented in all axes to expose for scanning. This produces 3D vertices that are connected to thousands of triangles to form the 3D image. The software then displays the e-model on the computer screen by giving colour shades, to each triangle based on its orientation to a digital light source. The result is a 3D image, which can be viewed, measured or manipulated on screen as if it is cast in your hand [17].

Clinical Management of Models

The orthodontist sends the impressions and bite registration to Geodigm and plaster cast is made which is scanned to an e model and articulated. The model can be then downloaded from the main server. A copy is maintained on Geodigm server for the security of

data storage. Using models, the clinician can move, rotate, or zoom in any plane or orientation. Point to point, Bolton analysis, and curve length measurement can easily be made by pointing and clicking the mouse. Colour bite mapping features permit analysis of occlusal relationships, 3D colour coded map demonstrates occlusal content between arches. In addition, there is an articulation feature which allows the clinician to set the centre of rotation. The articulation process can be animated and viewed as occlusal contact happens. One of latest developments is e-plan, which simulates multiple treatment plans to help determine most effective treatment. This also allows simulation of rotation movements and allows patient to view their own teeth from malocclusion to a post treatment view. The opportunities for 3D technology are endless. These new software’s are providing new efficiency for doctors and enhanced patient care.

Ultrasonography

The phenomenon perceived a sound is the result of periodic changes in pressure in the air against the eardrum. The periodicity of these changes lies anywhere between 1500 and 20000 cycles per second (hertz, Hz). By definition, ultrasound has a periodicity of greater than 20 kHz. Thus it is distinguished from other mechanical waveforms simply by having a vibratory frequency greater than audible range. Diagnostic Ultrasonography, the clinical application of Ultrasound, employs vibratory frequency in the range of 1 to 20 MHz. [21] Scanners used for sonography generate electrical impulses that are considered with high-frequency sound waves by a transducer, which is a device that converts one form of energy to another, in this case, sonic energy to electrical energy (Figure 4). The most important part of the transducer is a thin piezoelectric crystal or material made up of a great number of dipoles arranged in a geometric pattern. A dipole is a distorted molecule with a positive charge on one side and negative charge on the other. Currently most widely used piezoelectric material is Lead Zirconate. The electrical impulse generated by scanner causes dipoles within crystal to realign themselves within electric field and thus suddenly change a series of vibration that produces sound waves that are transmitted into tissue being examined [22].

As ultrasound beam passes through or interacts with tissues of different acoustic impedance, it is attenuated by a combination of absorption, reflection, refraction, and diffusion. Sonic waves that are reflected back (echoes) towards transducer causes a change in

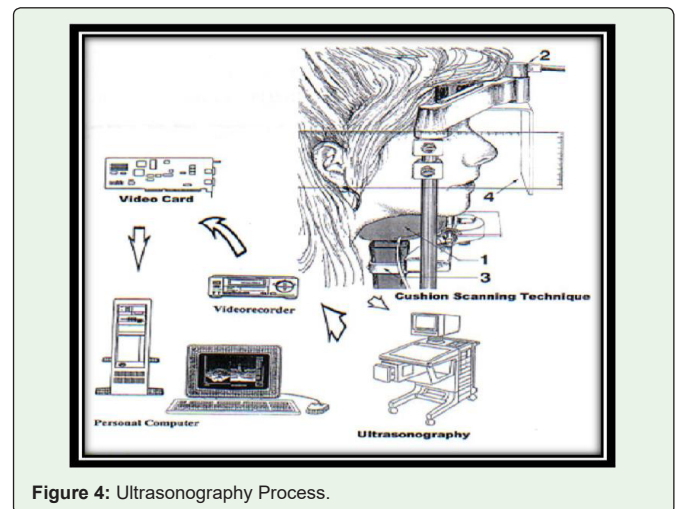


Figure 4: Ultrasonography Process.

thickness of the piezoelectric crystal, which in turn produces an electric signal that is amplified, processed and then displayed on a monitor. On this system, transducer serves both as receiver and transmitter. High-resolution systems may offer a slight thickness of 0.5 mm or less and a lateral resolution of 1 mm. Techniques currently in use permit echoes to be processed at a sufficiently rapid rate to allow perception of motion. This is called real time imaging [23]. In contrast to x-ray imaging, where an image is produced by transmitted imaging here it is produced by reflectors portion of the beam. The fraction of the beam that is reflected back to the transducer is dependent on the acoustic impedance of tissue, which is a product of its density (and thus the velocity of sound through it) and beam angle of incidence. Because of its acoustic impedance, a tissue has an internal echo pattern that is characteristic. The changes in echo pattern are correlated with pathologic changes in tissue, thus not knowledge of only technique, but also the anatomy of the structure is a must.

Applications (In Head and Neck) [24]

Mainly used in imaging of -

- Lymph nodes
- Post surgery, edema, and hematoma
- Eye, thyroid gland, and parotid gland
- Submandibular salivary gland
- To demonstrate thickness of masticatory mucosa
- Demonstrate displacement of soft tissue under denture by forces of occlusion

Comparison of Tongue Functions between Mature and Tongue-Thrust Swallowing [25]

Tongue functions during swallowing are of interest to many orthodontists. In normal deglutition, the tip of the tongue rests on the lingual part of the dentoalveolar area, the contraction of the perioral muscles is minimal during deglutition, the teeth are in momentary contact during swallowing, and there is neither a tongue thrust nor a constant forward posture. Several methods for evaluation of tongue movements, such as radio-cinematography, electromyography, and electromagnetic articulography, have been used in previous studies. Electropalatography and electromagnetic articulography are not suitable for examining normal tongue function because it is difficult for subjects to swallow normally with receiver coils and wires attached to their palates or tongues. X-ray cinematography and computerized tomography have the disadvantage of radiation exposure. Magnetic resonance imaging is not suitable for examining swallowing movements because of its high cost and long acquisition time [26]. Ultrasonography has the advantages of being non-invasive, rapid, easily repeatable, and relatively inexpensive. Ultrasonography has been used in many studies for static imaging of the oral cavity (e.g. for studying tongue morphology and for diagnosis of sialolithiasis, cysts, and tumours). Dynamic ultrasound investigation of tongue movement through sub mental scanning has been described by many researchers.

A major obstacle of these previous dynamic ultrasound studies was that they used direct transducer-skin coupling scanning to

observe tongue movements, this causes various artifacts resulting in inaccurate measurements of tongue movements. A cushion scanning method provides a solution to these problems. With a cushion scanning system that consists of a cushion device, a head support, a probe holder, and a head position recording device, the tongue dynamic can be correctly recorded and measured. Therefore, noninvasive real-time B+M-mode ultrasonography with CST has become the state-of-the-art tool to study tongue morphology and observe tongue functions such as swallowing and speech.

Ultrasound Imaging of Condylar Motion [27]

Imaging of the temporomandibular joint in an effort to understand normal and abnormal function continues to be a challenge. The principal methods currently used to image the joint in the sagittal view are x-rays, magnetic resonance imaging, and arthroscopy. The main disadvantage of x-rays is that they provide a static view while exposing the surrounding structures to radiation. With magnetic resonance imaging, the patient's head position is abnormal, which can influence mandibular motion. It is a costly procedure and often requires the patient to travel to a special facility. Arthroscopy involves surgical invasion of the joint with attendant surgical risks as well as the significant likelihood of altering normal function by its presence. Ultrasound imaging has been recognized for some time as having several important advantages: it does not require special facilities and thus has the potential to become available in an orthodontic office, and it can be used to view the joint in a continuum without invasion, discomfort, alteration of the patient's normal head posture, or interference with condylar motion.

Audio frequencies greater than 1600 Hz (cycles per second) are considered ultrasonic. An ultrasonic sound wave passing through the tissue will have a portion of the sound wave reflected on transiting dissimilar tissues. This reflected energy is returned to the ultrasonic emitting device (transducer) where the location of the interface is determined, and an appropriate image is produced representing the interface contours. In earlier studies, ultrasonic transducers have been placed at various parts of the skin surfaces related to the temporomandibular joint area. This produced nonconventional images of the joint from the frontal, superior, or both aspects. Recently Hirt and Knupfer obtained images of the temporomandibular joint in the more conventional sagittal plane. These were images of the joints of cadavers. Until now, obtaining conventional (sagittal) images of the temporomandibular joint via sonography has been limited for several reasons. Ultrasound is unable to penetrate the relatively large mass of bone overlying the joint, and the size of the transducer has prevented its strategic placement in order to produce conventional sagittal images [27].

Three-dimensional ultrasonography

Three-dimensional ultrasound imaging is a new technology that presents views of the fetal face with greater clarity than the conventional two-dimensional imaging described previously. The advantages include viewing of the face in a standard anatomic orientation, manipulation of planar views without concern for fetal movement, identification of the exact location of the planar images relative to the surface facial image, and easy interpretation of the lifelike rendered three-dimensional images by a non-trained observer. The sensitivity of three-dimensional imaging in diagnosing cleft lip and palate is considerably greater than two-dimensional imaging.

Sure Smile

Recent advances in computer management 3D imaging of dentition, manipulation of complex 3D data, and robotics have resulted in a new approach to treatment [28]. A patient centred practice is one that delivers high-quality care with a minimum amount of patient discomfort, compliance demand and chair time and completes treatment on time.

Benefits of Sure Smile

- Reduce errors in treatment resulting from appliance management
- It provides image capturing, 3D visualization of tools for diagnosis, monitoring, and patient communication along with precision appliances that can help the orthodontist to deliver truly customized care in a patient oriented practice.

Clinical Procedures [29]

The process begins with a 3D scan of patients dentition using the oro-scanner (oro matrix) a hand held scanner, this captures in real time in vivo images of dentition. The dentition is prepared for scanning by applying a thin white film, similar to articulating spot spray. It uses structured white light to generate images in rapid succession by projecting a precisely patterned grid on to the teeth. As the hand held scanner is passed over the dentition, reflected images of dentition, reflected images of a distorted grid are recorded with a video camera built into the handle of the scanner. The scanner is passed over the dentition in a rocking motion to allow visualization of all tooth surfaces, including undercut areas. The entire process takes about 1½ minutes per arch. The image is reference independent; meaning the image capturing process is not affected by the movement of patient or scanner. The scanner is placed in a mobile care smile cart that rolls from chair to chair. During the scanning stage, the multiple and over lapping images go to the computer. With sophisticated data registration and management techniques, the images are processed and the computer model is created. The teeth are then compared with teeth in a library of dental morphology. Information voids in the scan are filled with data from the library to further refine models (Figure 5).

A full oral scan is taken and integrated with conventional photographs and x-rays and entered into the electronic patient chart.




Figure 5: Sure Smile Technology.

Once the process is complete the teeth can be moved like independent objects in 3 dimensions with software controls. The windows based software allows the operator to diagnose plan treatment and simulate the results. 3D viewing of models like frontal, lateral, posterior or occlusal views or different perspective by using navigation tools. The teeth can also be viewed in individual arches. The operator can diagnose and plan the treatment with tools to measure tooth and arch dimensions and symmetric and asymmetric arch forms. A coronal cross section like a 3D CAT scan is also available for evaluation of 3rd order relationship.

The clinician plans treatment on parameters such as midline, occlusal plane and arch dimensions, multiple plans are to be simulated for comparison. The final treatment plan is then represented in form of 3D diagnostic setup – the Target occlusion. The operator can get treatment alternative by moving the teeth with a mouse or selected menus by enhancing or reducing teeth mesially or distally to simulate inter-proximal spacing. The change in X, Y and Z coordinates can be done in individual teeth to show case difficulty and treatment changes. Inter-arch contact and relations, such as overbite and overjet can be viewed with a cutting plane tool, which displays an inter-proximal or a transverse view at any location along with the arch. Once the target occlusion is done the digital bonding system form library is selected. Then geometric calculation and incorporation of various forces into the wires and their impact in teeth can be calculated. The operator based on the amount of tooth movement and forces required can decide the optimal treatment plan. Any errors in positioning brackets and wire combination can be managed at any stage during the cycle. New oral scans can be used for designing finished wires and fixed 3-3 lingual retainers before debonding.

Advantages of Sure Smile [29]

- Undesirable tooth movement may be reduced
- Arch-wire selection errors may be reduced
- Bracket positioning errors may be reduced
- Bonding adhesive thickness errors can be reduced

Accuracy of System [30]

- Oro scanner – unblurred images per second with as many as 3500 3D measuring points per image
- Greater accuracy of each points more than 50 microns, a linear error of 0.1 mm per tooth
- Wire bending – Bend positioning error $\pm 0.1\text{mm}$, Angular/torsional error ± 10
- Digital bracket movement $\pm 25\text{microns}$; in vivo $\pm 1\text{mm}$

Conclusion

The above mentioned technological advancements have helped not only the Orthodontists but the whole dental community. These advancements can be used in all branches of dentistry (Prosthodontics, Endodontic, Oral surgery etc). Diagnosis and treatment planning has become much more accurate, easier and less time consuming with these software's. Researchers and developers are striving hard continuously to make dentistry easier for all practitioners worldwide. Their dedication and efforts are very well appreciated and hope

they continue to strive forward with much more technological advancement.

References

- Rakosi T, Jonas I, Graber TM. *Orthodontic Diagnosis*. Thieme Medical Publishers Inc., New York. 1993.
- Tuncay OC. 3D imaging and motion animation. *Semin Orthod*. 2001; 7: 244-250.
- Xia J, Wang D, Samman N, Yeung RW. Computer assisted three-dimensional surgical planning and simulation *Int J Oral Maxillofac Surg*. 2000; 29:11-17.
- Athanasiou AE. *Orthodontic Cephalometry*. Philadelphia: Mosby-Wolfe. 1995.
- Halazonetis DJ. From 2-dimensional cephalograms to 3-dimensional computed tomography scans. *Am J Orthod Dentofac Orthop*. 2005; 127: 627-637.
- Akira N, Glenn T, Yoshinori Arai. Two and three-dimensional orthodontic imaging using limited cone beam computed tomography. *Angle Orthod*. 2005; 75: 895-903.
- Kau CH, Richmond S. Three-dimensional cone beam computerized tomography in orthodontics. *J Orthod*. 2005; 32: 282-293.
- Scarfe WC, Farman AG, Sukovic P. *Clinical Applications of Cone-Beam Computed Tomography in Dental Practice: J Can Dent Assoc*. 2006; 72: 75-80.
- Chen J, Kuang Chen, Chang F, Kun Chen. Comparison of landmark identification in traditional versus computer aided digital Cephalometry. *Angle Orthod*. 2000; 70: 387-392.
- Gregory I, Stuart A, Arthur J, William D. Comparison between traditional 2-dimensional cephalometry and a 3-dimensional approach on human dry skulls. *Am J Orthod Dentofac Orthop*. 2004; 126: 397-409.
- Rudolph DJ, Sinclair PM, Coggins JM. Automatic computerized identification of Cephalometric landmarks. *Am J Orthod Dentofac Orthop*. 1998; 113: 173-179.
- Heiko Visser, Tina Rödiger, Klaus-Peter Hermann. Dose Reduction by Direct-Digital Cephalometric Radiography. *Angle Orthod*. 2001; 71: 3: 159-163.
- Jia-Kuang Liu, Tainan, Taiwan, Yen-Ting Chen, Kuo-Sheng Cheng. Accuracy of computerized automatic identification of cephalometric landmarks. *Am J Orthod Dentofac Orthop*. 2000; 118: 535-540.
- Geelen W, Wenzel A, Gotfredsen E, Kruger M, Hansson LG. Reproducibility of cephalometric landmarks on conventional film, hardcopy, and monitor-displayed images obtained by the storage phosphor technique. *Eur J Orthod*. 1998; 20: 331-340.
- McClure SR, Sadowsky PL, Ferreria A, Jacobson A. Reliability of digital versus conventional Cephalometric radiology: A comparative evaluation of landmark identification error. *Semin Orthod*. 2005; 11: 98-110.
- Joffe L. Current products and practices Orthocad: Digital models for a digital era. *J Orthod*. 2004; 31: 344 -347.
- James Mah, Martin Freshwater. The Cutting Edge. *J Clin Orthod*. 2003; 37: 101-103.
- Ronald Redmond W. Digital models: A new diagnostic tool. *J Clin Orthod*. 2001; 35: 386-388.
- Okumuru H. 3-D computer aided design system applied to diagnosis and treatment planning. *Am J Orthod Dentofac Orthop*. 1999; 116:126-131.
- Fiorelli G, Melsen B. The '3-D occlusograms software'. *Am J Orthod Dentofac Orthop*. 1999; 116: 363-368.
- Santoro M, Galkin S, Teredesai M, Nicolay OF, Cangialosi TJ. Comparison of measurements made on digital and plaster models. *Am J Orthod Dentofac Orthop*. 2003; 124: 101-105.
- Benington PC, Gardener JE, Hunt NP. Masseter muscle volume measured using ultrasonography and its relationship to facial morphology. *Eur J Orthod*. 1999; 21: 659-670.
- Cheng CF, Peng CL, Chiou HY, Tsai CY. Dentofacial morphology and tongue function during swallowing. *Am J Orthod Dentofac Orthop*. 2002; 122: 491-499.
- Satiroğlu F, Arun T, Işık F. Comparative data on facial morphology and muscle thickness using ultrasonography. *Eur J Orthod*. 2005; 27: 562-567.
- Peng CL. Comparisons of tongue functions between mature and tongue thrust swallowing-an ultrasound investigation. *Am J Orthod Dentofac Orthop*. 2004; 125: 562- 570.
- Peng CL, Jost-Brinkmann PG, Yoshida N, Miethke RR, Lin CT. Differential diagnosis between infantile and mature swallowing with ultrasonography. *Eur J Orthod*. 2003; 25: 451-456.
- Braun S, Hicken JS. Ultrasound imaging of condylar motion: a preliminary report. *Angle Orthod*. 2000; 70: 383-386.
- Mah J, Sachdeva R. Computer assisted orthodontic treatment: The sure smile process. *Am J Orthod Dentofac Orthop*. 2001; 120: 85-87.
- Sachdeva RC. SureSmile technology in a patient-centered orthodontic practice. *J Clin Orthod*. 2001; 35: 245-253.
- Sachdeva R., James F., Andre F., Richard I. Sure smile: A report of the clinical findings. *J Clin Orthod* 2005; 39: 297-314.