

Inflammatory Myofibroblastic Tumor of
the Bladder in a 15-Year-Old BoySelim Taş¹, Kaan Karamık^{1*}, Mahmut Ekrem İslamoğlu¹, Mutlu Ateş¹, İrem Atalay
Karaçay², Hakan Anıl¹, Ali Yıldız¹ and Murat SAVAŞ¹¹Department of Urology, Antalya Training and Research Hospital, Turkey²Department of Pathology, Antalya Training and Research Hospital, Turkey

Article Information

Received date: Dec 04, 2017

Accepted date: Dec 15, 2017

Published date: Dec 18, 2017

*Corresponding author

Kaan Karamık, Department of Urology,
Antalya Training and Research Hospital,
Antalya Eğitim Araştırma Hastanesi
Varlık Mah, 07050 Muratpaşa/Antalya,
Turkey, Tel: +90 5544876649;
Fax: +90 242 247 00 27;
Email: kaankaramik@gmail.com

Distributed under Creative Commons
CC-BY 4.0

Keywords Inflammatory myofibroblastic
tumor; Anaplastic lymphoma kinase-1;
Fluorescence in situ hybridization;
Immunocytochemistry

Article DOI 10.36876/smju.1036

Abstract

Inflammatory myofibroblastic tumor is a rare soft tissue tumor which characterized by proliferation of myofibroblastic spindle cells and inflammatory cells. Inflammatory myofibroblastic tumor of the bladder and other spindle cell neoplasms of the bladder can exhibit similar clinical features. It is important to differentiate this tumor from the other spindle cell neoplasms. At this point, immunocytochemistry has a significant role. Anaplastic lymphoma kinase-1 has been considered diagnostically effective. Herein, we describe a case of 15-year-old boy with an inflammatory myofibroblastic tumor of the bladder. Fluorescence in situ hybridization analysis and immunohistochemical markers helped in correct diagnosis and further treatment decision.

Introduction

Inflammatory Myofibroblastic Tumor (IMT) is a rare neoplasm composed of myofibroblastic and fibroblastic spindle cells with an associated inflammatory cells infiltrate. IMT has been described in every organs and anatomical sites including the bladder. The malignant potential for these tumors¹ is debated. For this reason, it is important to differentiate this tumor from the other spindle cell neoplasms such as sarcomatoid variant of urothelial carcinoma and leiomyosarcoma. Some of immunohistochemical markers, especially Anaplastic Lymphoma Kinase-1 (ALK-1) with expression analyzed by Fluorescence In Situ Hybridization (FISH), have gained a distinct entity for the diagnosis of the IMTs. The treatment for IMT of the bladder is local surgical resection of the lesion. Here we present a case of IMT of the bladder in 15-year-old boy who was successfully treated by a bladder preserving approach.

Case Report

A 15-year-old boy was admitted to our clinic in May 2016 with a lower abdominal pain and urinary frequency. On physical examination, a tender suprapubic mass was palpable. He had a medical history of cryptorchidism and operated in 2011. He had no history of urinary tract infection or trauma, and had never undergone bladder instrumentation. Abdominal ultrasound revealed normal upper urinary tract and a 5 cm bladder tumor. Routine urine analysis and complete blood cell count did not demonstrate any pathologic finding. Contrast-enhanced computed tomography showed a 57 mm, solitary and round mass locating at the wall of the bladder dome, without signs of lymphadenopathy or metastatic spread (Figure 1). The mass thickened of the bladder wall and inflamed adjacent tissues.

Cystoscopic examination revealed a submucosal mass measuring 5 cm in size that grew into the lumen with a normal mucosal appearance and located at the dome of the bladder. It was decided that complete transurethral resection could not be performed considering the size of the tumor and extravesical spread and associated adjacent tissues inflammation. A midline lower abdominal, extraperitoneal approach used, and the anterior bladder wall opened. The mass with a cuff of normal bladder wall and the adherent peritoneal and bladder tissue, was excised. Frozen sections of the surgical margins were sent to pathology and reported as negative.

On gross examination, the mass measured 10×7×6 cm and was well-circumscribed and firm and a gray-white surface. Bladder tissue, including muscle, was widely infiltrated by spindle cells with organized in a fascicular growth pattern. Inflammatory cells were noted in the background. There were foci of necrosis but mitotic figures and marked atypia were absent. Immunohistochemical staining showed the tumor cells were positive for Smooth Muscle Actin (SMA), ALK-1, pancytokeratin and negative for desmin, myogenin and CD117 (Figure 2). To confirm the diagnosis of the IMT of the bladder, we also conducted FISH analysis of ALK-1 (Figure 3). From the histomorphology, immunophenotype and FISH analysis, the tumor was definitely diagnosed as IMT. To date, the patient has been followed up for 15 months and remains recurrence-free.

OPEN ACCESS

ISSN: 2574-8017

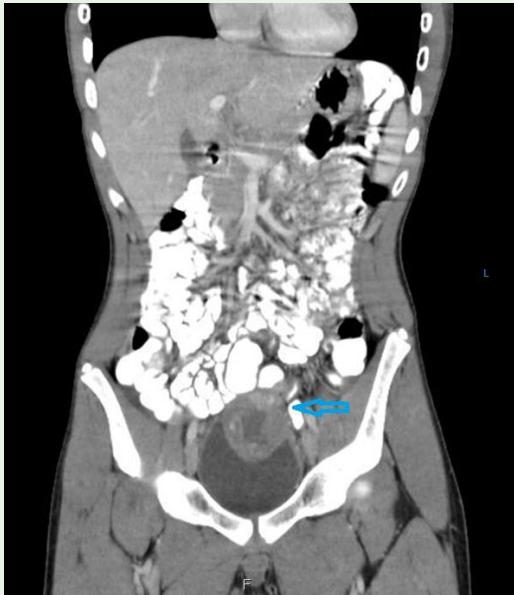

Figure 1: Solitary and round mass at the bladder dome.

Discussion

IMT is an uncommon soft tissue tumor which characterized by proliferation of myofibroblastic spindle cells and inflammatory cells. The first 2 cases reported, involving lung, was described by Brunn in 1939 [1]. Roth was the first who reported IMT as a pseudosarcomatous tumor in the bladder [2]. IMT has been assigned various other names, including nodular fasciitis, pseudosarcomatous fibromyxoid tumor, inflammatory pseudotumor, and pseudosarcomatous myofibroblastic tumor. In order to prevent this terminology complexity, the current World Health Organization soft tissue sarcoma classification recommends to use the term 'Inflammatory Myofibroblastic Tumor'.

Patient with IMT of the bladder may present with macroscopic hematuria followed by dysuria, urinary frequency, and lower abdominal pain [3]. Sometime a palpable mass may be the clinical presentation of this lesion [4]. Constitutional symptoms have also been described [5]. In our case, the patient did not have gross hematuria. If the lesion confined to the submucosa, hematuria may be absent. Pediatric IMT of the bladder masses range in size from 1.8 to 13 cm [6]. The commonest tumor location of IMT of the bladder in children is the dome compared to the posterior wall in adults [3,6].

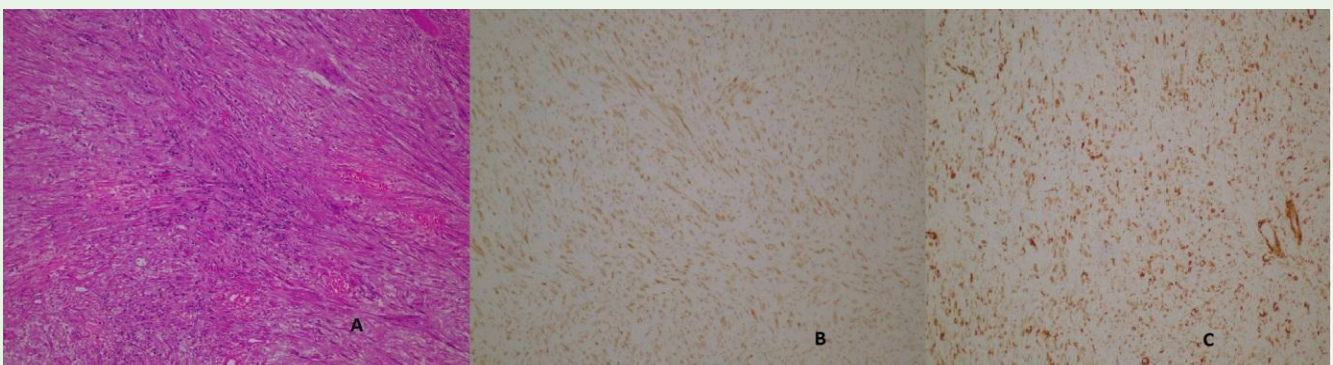


Figure 2: (A) Microscopy revealed spindle cells and inflammatory cells, x100, H&E (B) ALK-1 immunostaining of spindle cells (C) SMA immunostaining of spindle cells.

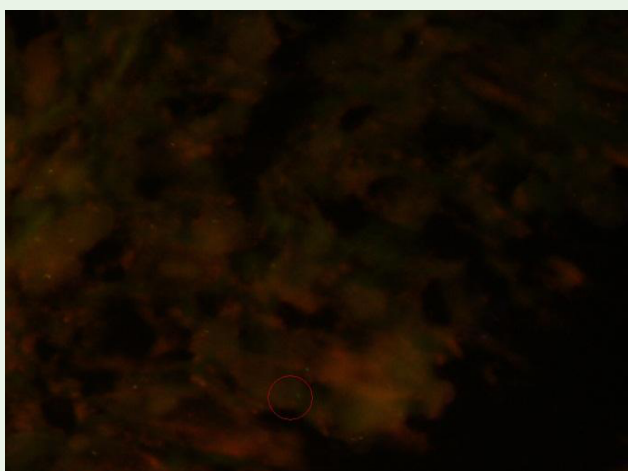


Figure 3: Signals positive for ALK-1 gene rearrangements with using FISH analysis.

The aetiology of IMT of the bladder is still unknown. IMT has been initially viewed as an inflammatory situation caused by chronic cystitis, trauma, and surgery. In some cases, there has been shown that Epstein Barr Virus and Human Herpes Virus 8 DNA on immunohistochemistry analysis of the lesions [7]. In the present case, the patient had an orchiopexy history.

IMT of the bladder and other spindle cell neoplasms such as sarcomatoid variant of urothelial carcinoma and leiomyosarcoma can exhibit similar clinical features. Differential diagnosis of these tumors may be difficult because of their overlapping histologic features and present a clinical challenge. The pathology report is essential tool to enhance patients care. To properly differentiate immunochemistry is important. ALK-1 staining plays a significant role in the distinction of IMT from other spindle cell neoplasms [8]. ALK-1 has been reported in up to 89% of IMT of the bladder [9]. Leiomyosarcomas and sarcomatoid carcinomas do not express ALK-1. Vimentin, SMA and cytokeratin are also express in IMT of the bladder. Furthermore, IMT of the bladder is typically negative

myogenin and myoD1 to differentiate from rhabdomyosarcomas. In this case, immunohistochemically, the tumor cells showed cytoplasmic positivity for SMA, ALK-1 and pancytokeratin. ALK-1 alteration was also displayed on FISH analysis.

ALK rearrangements were first described in Anaplastic Large Cell Lymphoma (ALCL) [10]. Translocation of the ALK gene occurred in 50%-60% of cases of ALCL. ALK gene rearrangements have been reported in case of IMT of the bladder [8]. This does not only helps in the differential diagnosis, but also gives an idea about aetiology of the tumor. IMT has most probably a neoplastic nature. Although the tumor is mostly localized and benign, it is rarely reported in the literature that local recurrence and metastasis support the neoplastic nature [11,12].

Conservative bladder-preserving surgery (transurethral resection or partial cystectomy) was accepted in the literature for the treatment of IMT of the bladder. In children, no proven recurrence or metastasis have been reported [6]. There were several cases of tumor recurrence in IMT of the bladder in adults [12]. Kim et al [11], had reported a 71-year-old male with IMT of the bladder who developed multiple metastases. Despite tending to a benign course, patients follow-up should be carefully undertaken. Although there is no definite follow-up scheme, postoperative management plan is perform a biannually magnetic resonance imaging scan and annually cystoscopy. Follow-up at 20 months showed no evidence of tumor recurrence.

Conclusion

It is still important to correct the diagnosis of inflammatory myofibroblastic tumor although the etiologic factors and biological behavior are not clearly known. Herein, the presence of ALK-1 by histopathological and FISH method is in effect. In clinical practice, local and complete resection of the lesion is recommended, combined with close clinical follow-up.

References

1. Brunn H. Two interesting benign lung tumors of contradictory histopathology, remarks on the necessity for maintaining chest tumor registry. *J Thorac Surg.* 1939; 9: 119-131.
2. Roth JA. Reactive pseudosarcomatous response in urinary bladder. *Urology.* 1980; 16: 635-637.
3. Teoh JY, Chan NH, Cheung HY, Hou SS, Ng CF. Inflammatory myofibroblastic tumors of the urinary bladder: A systematic review. *Urology.* 2014; 84: 503-508.
4. Süer E, Gülpınar Ö, Mermerkaya M, Burgu B, Celepli P, Sertçelik A, et al. Inflammatory myofibroblastic tumor of the bladder in a 10-year-old girl. *Urology.* 2012; 80: 1138-1140.
5. Williamson SR, Lopez-Beltran A, MacLennan GT, Montironi R, Cheng L. Unique clinicopathologic and molecular characteristics of urinary bladder tumors in children and young adults. *Urol Oncol.* 2013; 31: 414-426.
6. Collin M, Charles A, Barker A, Khosa J, Samnakay N. Inflammatory myofibroblastic tumour of the bladder in children: A review. *J Pediatr Urol.* 2015; 11: 239-245.
7. Mergan F, Jaubert F, Sauvat F, Hartmann O, Lortat-Jacob S, Revillon Y, et al. Inflammatory myofibroblastic tumor in children: clinical review with anaplastic lymphoma kinase, Epstein-Barr virus, and human herpes virus 8 detection analysis. *J Pediatr Surg.* 2005; 40: 1581-1586.
8. Coffin CM, Patel A, Perkins S, Elenitoba-Johnson KS, Perlman E, Griffin CA. ALK1 and p80 expression and chromosomal rearrangements involving 2p23 in inflammatory myofibroblastic tumor. *Mod Pathol.* 2001; 14: 569-576.
9. Freeman A, Geddes N, Munson P, Joseph J, Ramani P, Sandison A, et al. Anaplastic Lymphoma Kinase (ALK 1) staining and molecular analysis in inflammatory myofibroblastic tumours of the bladder: a preliminary clinicopathological study of nine cases and review of the literature. *Mod Pathol.* 2004; 17: 765-771.
10. Medeiros LJ, Elenitoba-Johnson KS. Anaplastic Large Cell Lymphoma. *Am J Clin Pathol.* 2007; 127: 707-722.
11. Kim HW, Choi YH, Kang SM, Ku JY, Ahn JH, Kim JM, et al. Malignant inflammatory myofibroblastic tumor of the bladder with rapid progression. *Koeran J Urol.* 2012; 53: 657-661.
12. Montgomery EA, Shuster DD, Burkart AL, Esteban JM, Sgrignoli A, Elwood L, et al. Inflammatory myofibroblastic tumors of the urinary tract: a clinicopathologic study of 46 cases, including a malignant example inflammatory fibrosarcoma and a subset associated with high-grade urothelial carcinoma. *Am J Surg Pathol.* 2006; 30: 1502-1512.