

Subcapsular Hepatic Haematoma with Haemorrhagic Shock After an Endoscopic Retrograde Cholangiopancreatography

Sonia Trabanco^{1,2*}

¹Resuscitation Unit of the Anesthesiology Service, University Hospital Marqués de Valdecilla, Santander, Spain

²Post Anesthesia Care Unit, Department of Anesthesiology, Marqués de Valdecilla University Hospital, Spain

Article Information

Received date: Feb 28, 2017

Accepted date: Mar 01, 2017

Published date: Mar 06, 2017

*Corresponding author

Sonia Trabanco, Resuscitation Unit of the Anesthesiology Service, University Hospital Marqués de Valdecilla, Avda Valdecilla nº 25, 39008 Santander, Spain, Tel: 0034-9422-02520; E-mail: soniatrabanco@gmail.com or m327@humv.es

Distributed under Creative Commons CC-BY 4.0

A 51-year-old man with obstructive jaundice who underwent an endoscopic retrograde cholangiopancreatography (ERCP). After the procedure he developed abdominal pain and hypotension, so a Computed Tomography (CT) was performed showing a voluminous subcapsular hepatic haematoma (25 × 17 × 5.3 cm), with signs of active bleeding and sub diaphragmatic air bubbles [1] (Figure 1).

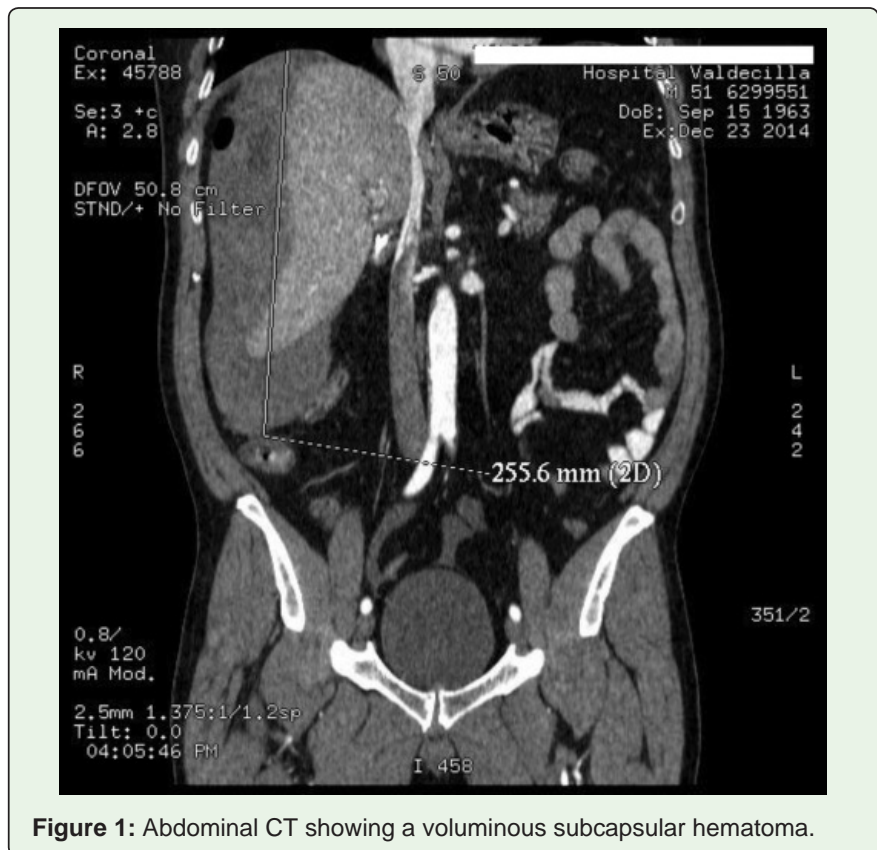


Figure 1: Abdominal CT showing a voluminous subcapsular hematoma.

Due to haemorrhagic shock, an urgent laparotomy was performed, but at no point could any bleeding be seen. He needed many units of blood product transfusions and hepatic packing was performed, which was removed 48 hours later.

In the postoperative period he developed fever and *Streptococcus mitis* was isolated in the bilis samples, so he was treated with a broad-spectrum antibiotic. He was discharged 26 days later without complications [2] (Figure 2).

Subcapsular hepatic haematoma with haemorrhagic shock is a rare complication after an ERCP. It could be explained by an accidental puncture of the intrahepatic biliary tree by the guide wire and the rupture of small calibre intrahepatic vessels, passing air bubbles to the biliary tree and into the haematoma.

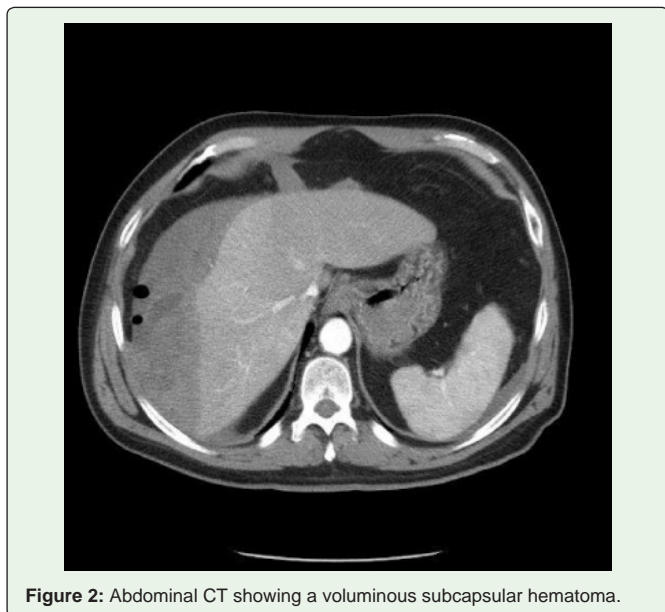

Figure 2: Abdominal CT showing a voluminous subcapsular hematoma.

Abdominal pain, with or without hypotension, would be a cause for concern. Once the diagnosis is made, patients have to be closely monitored and given broad-spectrum antibiotic therapy. Most cases are managed conservatively, with periodic radiological checks [3]. In cases of progression, selective embolization of some hepatic arterial branches can be considered, keeping back the surgical intervention for cases with haemodynamic instability or signs of haematoma infection.

References

1. Fei BY, Li CH. Subcapsular hepatic haematoma after endoscopic retrograde cholangiopancrea-tography: An unusual case. *World J Gastroenterol.* 2013; 19: 1502-1504.
2. Kwon CI, Song SH, Hahm KB, Ko KH. Unusual complications related to endoscopic retrograde cholangiopancreatography and its endoscopic treatment. *Clin Endosc.* 2013; 46: 251-259.
3. Del Pozo D, Moral I, Poves E, Sanz C, Martín M. Subcapsular hepatic haematoma following ERCP: case report and review. *Endoscopy.* 2011; 43: E164-E165.