

# Strangulated Right Diaphragmatic Hernia: A Diagnostic Trap to Avoid

Razafimanjato NNM<sup>1\*</sup>, Ravoatrarilandy M<sup>2</sup>, Hunald Fa<sup>2</sup>, Rakotovao HJL<sup>2</sup> and Castier Y<sup>3</sup>

<sup>1</sup>Department of surgery & division of Vascular, Thoracic surgery and lung Transplantation; Bichat-Claude Bernard Hospital, France

<sup>2</sup>Department of Surgery & Division of Thoracic Surgery, Teaching Hospital of Joseph Ravoahangy Andrianavalona Ampefiloha, Madagascar

<sup>3</sup>Department of surgery & division of Vascular, Thoracic surgery and lung Transplantation; Bichat-Claude Bernard Hospital, Teaching Hospital of Paris Nord Val de Seine, France

## Article Information

Received date: Sep 21, 2017

Accepted date: Oct 04, 2017

Published date: Oct 06, 2017

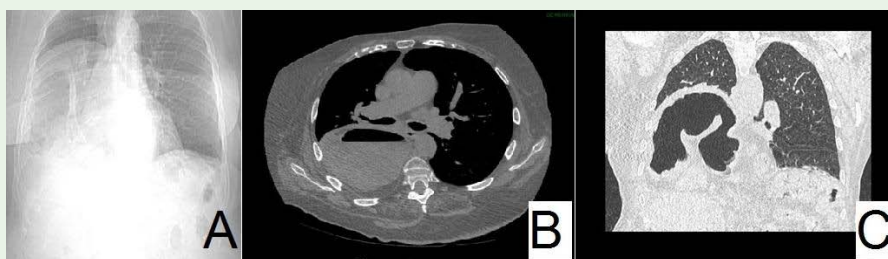
## \*Corresponding author

Razafimanjato Narindra Njarasoa Mihaja,  
Department of surgery; Bichat-Claude  
Bernard Hospital, 46 rue Henri Huchard,  
75877 Paris Codex 18; Faculty of  
medicine UPMC, Paris 6, France,  
Tel: +261.32.64.368.41;  
Email: razafesteban@yahoo.fr

**Distributed under** Creative Commons  
CC-BY 4.0

An 78 year old woman with Chronic Obstructive Pulmonary Disease (COPD) post tobacco (30 packs annuall) and Cardiac Arrhythmia was admitted to our hospital. It was noted a medical history of laparotomy sub costal for for cholecystectomy 20 years ago. She present with worsening of respiratory symptoms such as dyspnoea of rest for more than one week. Physical examination showed the patient was afebrile with acute respiratory distress (oxygen saturation at 87%) associated with confusion (Glasgow score : 10) and a high blood pressure situation (200/100 mm Hg) accompagnied by tachycardia (heart rate approximately 125 BPM) and abdominal distension comes with vomiting alimentary. Laboratory investigations indicated : respiratory acidosis (pH: 7.07) with hypercapnia at 91 mm Hg, a PaO2 at 135 mm Hg and alkaline reserve at 36 mmol/l. The rest of biological examinations did not show any other specific abnormalities.

A chest X ray in a semi-upright position showed homogenous radio-opacity with complete collapse of right lower lobe, thickened caesuras and mediastinal deviation. The first hypothesis was a decompensation of Chronic Obstructive Pulmonary Disease (COPD) complicated of respiratory acidosis caused by a viral infection. The patient had an antibiotherapy probabilistic, corticosteroid therapy and Non- Invasive Ventilation (VNI) with favourable evolution. Chest Thorax (CT) realized following an acute episode revealed in axial air fluid level and established the diagnosis of herniation of large bowel into the right hemithorax in coronal section (Figure 1). A posterolateral thoracotomy procedure was performed which involved the reduction of paraoesophageal hernia without bowel resection into the abdominal cavity, excision of the hernia sac, a suture repair of crural pillars and diaphragmatic plicaturer (Figure 2). The patient had an uneventful post-operative recovery. In the immediate post-operative period, the patient had a daily chest physiotherapy and non-invasive ventilation session. The chest X-ray showed a good re-expansion of the right lung with disappearance of intra-thoracic herniation authorizing the removal of chest drains early on 3 day and 4 day postoperatively. No recurrence was noted after 6 months of decline.

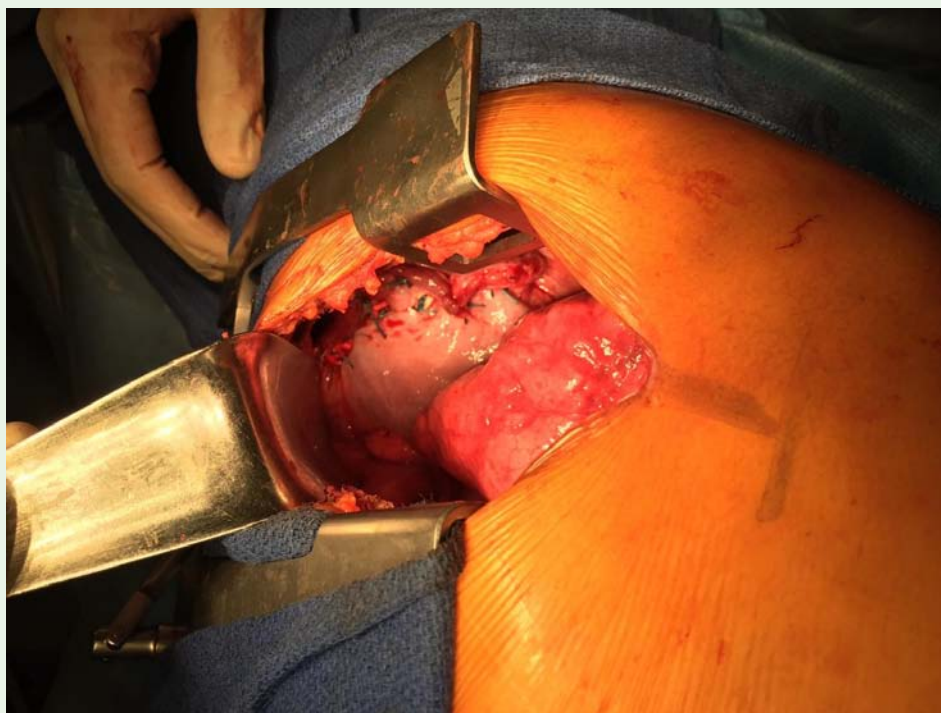


**Figure 1:**

A : CT topogram shows herniation of the liver and large bowel loops into the right hemithorax, with a shift of the heart and mediastinum to the left side caused by herniation.

B : Axial CT scan image shows a giant right-sided thoracic air-fluid level indicating obstruction and slight mediastinal shift.

C : Coronal CT scan image demonstrating herniation of bowel loops and liver in the right hemithorax through the large diaphragmatic defect.



**Figure 2:** Operative photograph: reparation (plicature) of the diaphragmatic defect visualised at thoracotomy.

## Discussion

Complex hernia paraesophageal (type-IV) which contains abdominal viscera herniating through the hiatus into the thoracic cavity other than the stomach represents at most 5-15% among all the other types [1]. There are particularly likely to incarcerate and cause symptoms of intermittent epigastric pain [2]. Image of compressive air-fluid level in chest X-ray should lead to the elimination of a pulmonary abscess and other aetiologies of hydropneumothorax with a risk of chest drainage and visceral perforation [3]. Today symptomatic paraesophageal hernias are recommended for repair [4]. The majority of published reports suggest that laparoscopic repairs with less pain are favored compared to an aggressive surgical approach [4,5]. Current practice favors a laparoscopic approach, complete sac excision, primary crural repair with or without use of mesh, and a routine fundoplication. Transthoracic repair avoids the previous operative field (fascial retraction and visceral adherence) in abdominal surgery patients as in our observation [6,7]. The possibility of a strangulation of a diaphragmatic hernia should be systematically borne in clinician's mind before an image air-fluid level intra thoracic associated at non-febrile digestive symptomatology. Imaging examinations should in no case delay surgery.

## Author Contribution

**Data Curation:** Razafimanjato NNM.

**Investigation:** Razafimanjato NNM, Ravoatrarilandy M.

**Writing-Original Draft:** Razafimanjato NNM, Ravoatrarilandy M.

**Writing-Review & Editing:** Rakotovao HJL, Castier Y.

## Acknowledgement

The author is very grateful to Razafimanjato A. Esteban for his help in preparing this article.

## References

1. Samiullah SI, Taimur M. Strangulated paraesophageal hiatus hernia: a case report. *Isra Medical Journal*. 2015; 7: 171-174.
2. Ouyang W, Dass C, Zhao H, Kim C, Criner G, COPD Gene Investigators. Multiplanar MDCT measurement of esophageal hiatus surface area: association with hiatal hernia and GERD. *Surg Endosc*. 2016 ; 30: 2465-2472.
3. Cruz CJ, Minagi H. Large-bowel obstruction resulting from traumatic diaphragmatic hernia: imaging findings in four cases. *AJR Am J Roentgenol*. 1994 ; 162 : 843-845.
4. Lebenthal A, Waterford SD, Fisichella PM. Treatment and controversies in paraesophageal hernia repair. *Front Surg*. 2015; 2: 13.
5. Stylopoulos N, Gazelle GS, Rattner DW. Paraesophageal hernias: operation or observation? *Ann Surg*. 2002; 236: 492.
6. De Meijer VE, Vles WJ, Kats E, Den Hoed PT. Iatrogenic diaphragmatic hernia complicating nephrectomy: top-down or bottom-up? *Hernia*. 2008; 12: 655-658.
7. Armstrong PA, Miller SF, Brown GR. Diaphragmatic hernia seen as a late complication of laparoscopic cholecystectomy. *Surg Endosc*. 1999; 13: 817-818.