

Action of Ascorbic Acid Supplementation in The Prevention of Morphological Changes in the Myocardium in Mice with Muscular Dystrophy

Marília Fabiana De Oliveira Lima¹, Flávia De Oliveira², Marcelo José Santiago Lisboa¹, Sandra Regina Stabile³, Natan Reyges Castro Da Purificação¹, Melyna Soaressouto¹, Quintana, Hananiah Tardivo², Edson Aparecido Liberti⁴ and Naianne Kelly Clebis^{1*}

¹Laboratório De Microscopia Celular E Tecidual, Universidade Federal Do Rio Grande do Norte, Brazil.

²Departamento De Biociência, Universidade Federal De São Paulo, Brazil

³Departamento De Ciências Morfofisiológicas, Universidade Estadual De Maringá, Brazil

⁴Instituto De Ciências Biomédicas, Universidade De São Paulo, Brazil

Article Information

Received date: Nov 13, 2018

Accepted date: Nov 23, 2018

Published date: Nov 27, 2018

*Corresponding author

Naianne Kelly Clebis, Departamento de Morfologia - Laboratório de Microscopia Celular e Tecidual (MICROCELT), Universidade Federal do Rio Grande do Norte - Centro de Biociências BR 101, s/n - Campus Universitário Lagoa Nova Bairro: Lagoa Nova - Natal/RNCEP: 59078-970, Brazil, Tel: +55 84 32153431; Fax: +55 84 32119207; Email: nkclebis@hotmail.com

Distributed under Creative Commons CC-BY 4.0

Keywords Muscular dystrophy; Duchenne; Heart diseases; Fibrosis; Antioxidants

Abbreviations AA: Ascorbic Acid; CFI: Type I Collagen Fibers; CFIII: Type III Collagen Fibers; COX-2: Cyclooxygenase-2; DMD: Duchenne Muscular Dystrophy; ROS: Reactive Oxygen Species

Article DOI 10.36876/smmd.1030

OPEN ACCESS

ISSN: 2576-5442

Abstract

Duchenne Muscular Dystrophy inducing fibrosis, oxidative stress and muscle necrosis. In the heart, DMD can lead to cardiac failure and death.

Objective: This study evaluated the expression of cyclooxygenase-2 (COX-2) and ventricular histological aspects of Dystrophic mice, as well as the effects of Ascorbic acid (AA) on these parameters.

Materials and methods: 60 mice, 30 C57BL/10 and 30 C57BL/10-Dmdmdx, were distributed into six groups according to their age and treatment (n=10/group): control groups at 30 and 60 days (C30 and C60); Dystrophic animals at 30 and 60 days (D30 and D60); and controls and Dystrophic animals at 60 days supplemented with AA (CS60 and DS60). After the trial period, the animals were euthanized and their hearts were collected. Samples were subjected to Masson's Trichrome, Picrosirius Red under polarized light and COX-2 Immunohistochemistry techniques.

Results: The results showed an increase of collagen fibers in the D30 group and reduction in the area occupied by cardiomyocytes in D60. COX-2 expression was higher in the C30, D30 and D60 groups, indicating a probable cellular remodeling process in C30 and increased oxidative stress leading to fibrosis in dystrophic animals.

Conclusion: AA supplementation prevented muscle loss in DS60 compared to D60, as well as a decrease of fibrosis and the expression of COX-2 in DS60, proving the protective action of AA in the hearts of these animals.

Introduction

Duchenne Muscular Dystrophy (DMD) is a genetic disorder lethal by mutations in the X chromosome that results in alterations of dystrophin, cytoskeletal protein fundamental for the functional muscular function [1-3]. It is known that almost 95% of patients with Duchenne Muscular Dystrophy (DMD) have severe cardiomyopathies at around 20 years of age [4,5].

The cardiac involvement of DMD can be evidenced by abnormalities in the electrocardiogram [6], abnormal movement of the left ventricle [7] walls in fibrotic areas, which can lead to cardiac failure [8,9], but the molecular mechanism of vulnerability resulting from the characteristic lack of dystrophin in DMD is not yet fully elucidated.

The altered flow of calcium ions through the membrane of the weakened muscle fiber increases its intracellular level, increasing the production of Reactive Oxygen Species (ROS). This consequently generates oxidative stress responsible for the oxidation of various contractile proteins, causing inflammatory processes and fibrosis [10]. Fibrosis occurs by the proliferation and replacement of collagen fibers throughout the injured muscle [11]. The fibers enter a repeated cycle of degeneration and regeneration, which involves inflammatory responses and deposition of type I (CFI) and type III (CFIII) collagen fibers in the extracellular matrix, which causes excessive interstitial collagen deposition characteristic of DMD [12].

It is known that some prostaglandins are involved in modulating the inflammatory process and myogenesis [13], steps related to degenerative and fibrotic development of cardiac tissue in DMD. The synthesis of these prostaglandins is catalyzed by different isoforms of Cyclooxygenase (COX) and cyclooxygenase-2 (COX-2) is able to regulate the initial stages of growth of myofibers during muscle regeneration [14]. However, COX-2 is also produced in response to cellular stress, such as the presence of inflammation [15].

To minimize the effects of oxidative stress generated by ROS on different tissues, studies have been conducted using antioxidants in order to reduce concentrations of ROS [10,11]. Among these antioxidants is ascorbic acid (AA), that has a fundamental role in preventing oxidation and the action of ROS, such as damage to biological membranes and DNA.

AA can act in two ways in the cell: in the cytosol, acting as a primary antioxidant, fighting ROS; and indirectly by acting on the plasma membrane by reducing α -tocopheryl into α -tocopherol radicals [16]. AA is a readily available substance and use in the human diet, a fact that has also motivated its use in this study.

Thus, this study aimed to evaluate the collagen deposition and the immunoexpression of COX-2 in the myocardium of mdx mice, as well as the effects of treatment with ascorbic acid in these parameters.

In this study the mdx mouse was used to analyze the effects of DMD [17,18] and the action in the treatment with AA in the heart, once, that studies have shown that the ventricular cardiomyocytes of this animal model show an increase [19], and replacement of the cardiac muscle by connective tissue, as well as necrotic and apoptotic cells [9].

Material and Methods

Materials

All procedures in this study followed the principles adopted by the Brazilian College of Animal Experimentation (COBEA) and were approved by the Commission of Experimentation and Animal Use (CEUA) of the Institute of Biomedical Sciences, University of São Paulo (Nº. 164/2011 by the CEUA/ICB/USP) and by the CEUA of the Federal University of Rio Grande do Norte (Nº.055/2013).

60 male mice with an initial age of 30 days were used in this study, along with 30 controls (C57BL/10) and 30 mdx mice (C57BL/10-Dmdmdx).

Mice remained isolated in polypropylene cages (five animals per cage) equipped with water dispenser and feeder, kept in controlled conditions of temperature ($24 \pm 2^\circ\text{C}$) and lighting (12 hours light/12 hours dark cycle), receiving food and water ad libitum.

The animals were randomly divided into six groups according to the age they would reach at the end of the experiment ($n=5$): control group at 30 days of age (C30); dystrophic at 30 days of age (D30); control at 60 days of age (C60); dystrophic at 60 days of age (D60); control at 60 days of age supplemented with AA (CS60); and dystrophic at 60 days of age supplemented with AA (DS60).

Experimental treatment

CS60 and DS60 animals were directly supplemented by gavage with AA diluted in 1 mL of water, at the dosage of 200 mg/kg body weight [20] for 30 days.

Animal euthanasia, collection and heart fixation: At the end of the experimental period, the animals were weighed and subsequently euthanized in a carbon dioxide chamber (CO_2) at the Biotherium of the Anatomy Department - ICB/USP. The animals were thoracotomized and the obtained hearts were washed in PBS (0.1M, pH 7.4) to eliminate blood and then immediately fixated.

Heart histological preparation: The ventricles were separated from the atria and later they were sectioned transversely into two parts and fixated in Bouin solution and in 10% buffered formalin. After 48 hours the ventricles were processed according to histological procedures, and embedded in paraffin. Slides with 6 μm thick cross-section were stained by Masson's Trichrome and Picrosirius Red histological techniques, and slides with 3 μm thick sections were immunoblotted by COX-2 immunohistochemistry technique.

COX-2 immunohistochemistry

After removing the paraffin with xylene, the slides were rehydrated in absolute alcohol and pretreated for antigen retrieval with citrate buffer (0.01M citric acid, pH 6) in a microwave oven for three cycles of five minutes each. Samples were pre-incubated with solution of 0.3% hydrogen peroxide in PBS (0.1M, pH 7.4) for five minutes to inactivate endogenous peroxidases, and were subsequently blocked with BSA (Sigma, SigmaAldrich, St. Louis, USA) in PBS solution for 30 minutes. Then they were incubated overnight with anti-COX-2 antibody (polyclonal, sc-1747, Santa Cruz Biotechnology, California, USA) in a dark humidified chamber under refrigeration.

The slides were washed with PBS and incubated with biotinylated secondary antibody (IgG polyclonal anti-rabbit, HRP Detection, Biocare, California, USA) for one hour. The material was washed with PBS, treated with streptavidin-peroxidase (TrekAvidin-RP Label, Biocare, California, USA) for 45 minutes, developed in a 0.05% solution of DAB (diaminobenzidine 3-3) (Betazoid DAB), counterstained with Harris hematoxylin (Easy Path) through dehydration phases in absolute alcohol and xylene, and finally the slides were mounted with Entellan.

Obtaining images: For capturing images, a Moticam 5 video camera (Motic China Group Co., Shanghai, China) coupled with a trinocular BA410 light microscope (Motic China Group Co., Shanghai, China) at 40x were used. Image analysis was performed using the Image-Pro Plus software version 4.5.0.29 (Media Cybernetics, Silver Spring, MD, USA).

The field area provided by the microscope at 40x objective was 0.165 mm^2 . Images captured in 20 microscopic fields, per animal, per technique were analyzed, thus totaling an area of 3.3 mm^2 .

Histopathological analysis

Masson's Trichrome stain: areas (μm^2) occupied by heart muscle (stained in red) and Total Collagen Fibers (TCF) (stained in blue) were measured.

Picrosirius Red stain: under polarized were typified using the light:

- Type I collagen fibers (CFI): mature collagen stained in red, orange or yellow;
- Type III collagen fibers (CFIII): immature collagen stained in green.

The area occupied by collagen fibers was determined in μm^2 .

Analysis of COX-2 immunoexpression

According to the Soumaoro's et al. score (2006) [21], the intensity and extent of immunostaining were evaluated in order to analyze COX-2 immunoexpression. For classifying intensity, the cross-classification system was used, where 0 (negative); + = 1 (weak); ++ = 2 (moderate); and +++ = 3 (strong).

The staining extent was rated as 0 (0%), 1 (1-25%), 2 (26-50%), 3 (51-75%) and 4 (76-100%), according to the percentage of the positive areas of immunostaining in relation to the sampling area (20 microscopic fields). The sum of the intensity of immunostaining with its extension (percentage of fields with staining shown) was used as the final immunostaining score (0-7) for COX-2. Positive results were considered >3 .

Statistical analysis

The data were statistically analyzed by GraphPad Prism 5.1 software and expressed as mean \pm standard deviation. One way ANOVA followed by multiple comparisons by Tukey method were used.

P values <0.05 were considered statistically significant.

Results

The results and discussion concerning the body weight of the animals were previously published by our research group [22].

The areas (μm^2) occupied by cardiac muscle and collagen tissue in the different groups are shown in Figure 1A.

Using the Masson's Trichrome technique (Figures 1B-G), an increase of 5.65% in the area occupied by cardiac muscle was observed in animals of the C60 group compared to C30 ($p>0.05$), and a 28.6% increase in CS60 when compared to C60 ($p<0.001$). A reduction of 18.71% in the D60 group compared to D30 ($p<0.01$), and an increase of 30.39% for DS60 in relation to D60 ($p<0.001$).

By comparing the areas occupied by cardiac muscle between the dystrophic animals and their controls within the same age range and treatment, an increase of 12.32% in D30 compared to C30 ($p<0.01$) was observed. In the D60 group, this parameter was 12.53% lower than in the C60 ($p<0.01$), and DS60 was 10.28% lower than CS60 ($p<0.01$).

The area occupied by collagen in the C60 group was 42.41% greater than in C30 ($p<0.001$) and 44.41% greater than in CS60 ($p<0.001$). In D30 and D60, the areas were similar. However, there was a reduction of 14.33% in the DS60 group compared to D60 ($p<0.05$).

Also, in relation to collagen we observed: an increase of 34.26% of area in D30 in comparison to C30 ($p<0.001$); 11.72% reduction in

D60 in relation to C60 ($p<0.05$); and the area was 26.48% greater in DS60 than its control (CS60) ($p<0.001$).

The classification of collagen fibers (myocardial area occupied by CFI and CFIII) of each group is shown in Figure 2A-G.

The area occupied by CFI (mature collagen) in C60 was 28.57% greater than in C30 ($p<0.001$). This area was 26.18% lower in the CS60 group when compared to C60 ($p<0.001$). In dystrophic groups, there was an increase of 24.95% in D60 in comparison to D30, and a 72.67% reduction in DS60 in relation to D60 ($p<0.001$).

The area occupied by CFI was 40.74% greater in D30 than C30 ($p<0.001$), 37.74% greater in D60 in relation to C60 ($p<0.001$) and 40.53% lower in DS60 in comparison to CS60 ($p<0.001$).

The analysis of the area occupied by CFIII (immature collagen) showed a 55.62% reduction in C60 group when compared to C30 ($p<0.001$), and of 35.43% in CS60 in relation to C60 ($p<0.001$) (Figures 2B-F). In dystrophy groups, a 30.5% reduction in D60 compared to D30 ($p<0.001$), and 86.07% in DS60 in relation to D60 ($p<0.001$) were observed.

When comparing dystrophic and its control animals we found: 14.58% reduction in the amount of CFII in D30 in relation to C30 ($p<0.001$); an increase of 25.23% in D60 in relation to C60 ($p<0.001$); and a 71.15% reduction in DS60 in comparison to CS60 ($p<0.001$).

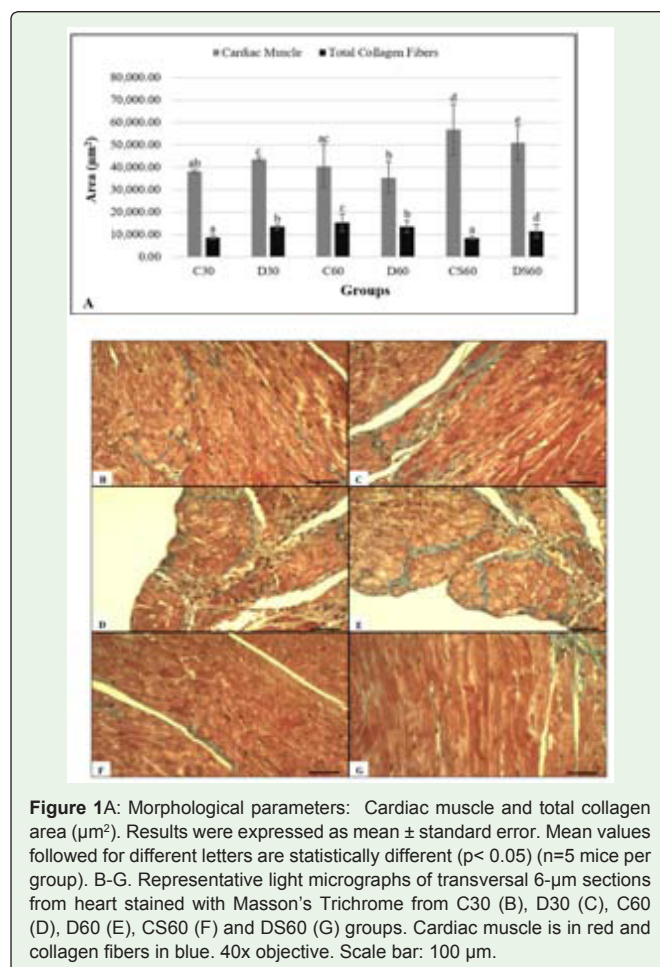


Figure 1A: Morphological parameters: Cardiac muscle and total collagen area (μm^2). Results were expressed as mean \pm standard error. Mean values followed for different letters are statistically different ($p<0.05$) ($n=5$ mice per group). B-G. Representative light micrographs of transversal 6- μm sections from heart stained with Masson's Trichrome from C30 (B), D30 (C), C60 (D), D60 (E), CS60 (F) and DS60 (G) groups. Cardiac muscle is in red and collagen fibers in blue. 40x objective. Scale bar: 100 μm .

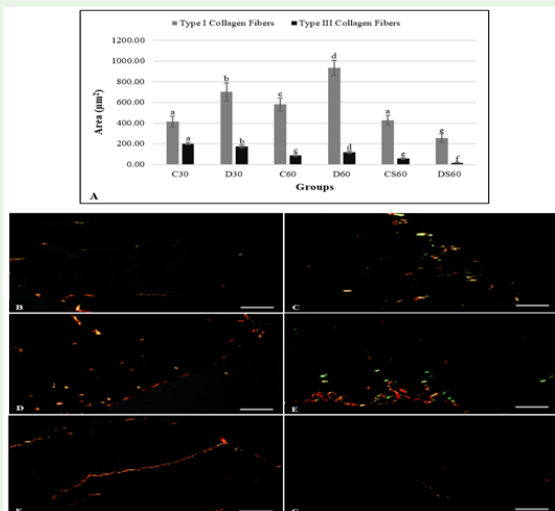


Figure 2: A. Type I and III collagen fibers area (µm²). Results were expressed as mean ± standard error. Mean values followed for different letters are statistically different ($p < 0.05$) ($n=5$ mice per group). B-G. Representative light micrographs of transversal 6-µm sections from heart stained with Picrosirius red under polarized light from C30 (B), D30 (C), C60 (D), D60 (E), CS60 (F) and DS60 (G) groups. Type I collagen fibers are in red, orange and yellow and type III collagen fibers are in green. 40x objective. Scale bar: 100 µm.

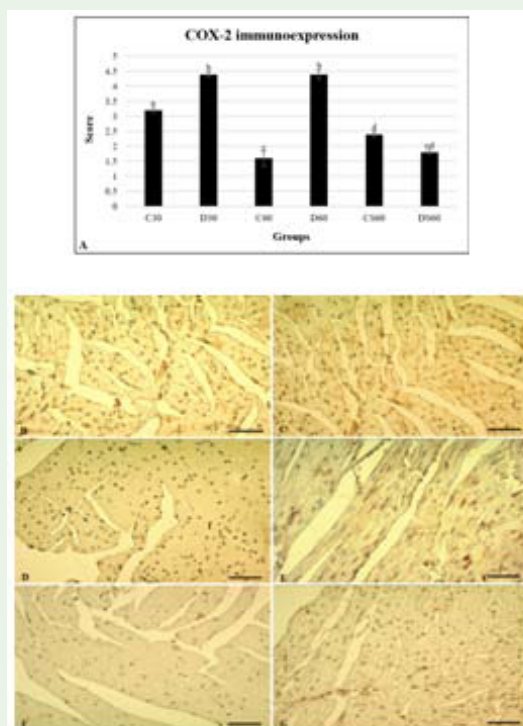


Figure 3: A. Analyses of the COX-2 immunoreactivity by Soumaoro's et al. score (2006). Results were expressed as mean ± standard error. Mean values followed for different letters are statistically different ($p < 0.05$) ($n=5$ mice per group). B-G: Representative light micrographs of transversal 3-µm sections from heart stained with COX-2 immunohistochemistry in C30 (B), D30 (C), C60 (D), D60 (E), CS60 (F) and DS60 (G) groups. 40x objective. Scale bar: 100 µm.

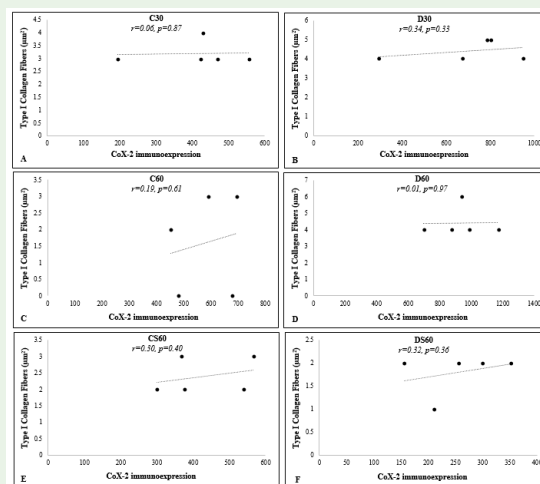


Figure 4: The correlation between the area occupied by type I collagen fibers and COX-2 immunoreactivity in the myocardium of the animals of groups C30 (A), D30 (B), C60 (C), D60 (D), CS60 (E) and DS60 (F). r = Person coefficient; p = significance level; * = $p < 0.05$. ($n = 5$).

Results referring to COX-2 immunostaining in the cardiac tissue are shown in Figure 3A-G.

The expression of COX-2 was higher than 3.0 in C30, D30 and D60 groups; therefore, positive according Soumaoro's et al. [21] score.

The expression of COX-2 enzyme was 29.54% higher in D30 animals in relation to C30 ($p < 0.001$), and in D60 it was 63.63% greater than in C60 ($p < 0.001$). Animals from CS60 group had a 25.0% increase in relation to DS60 ($p > 0.05$).

The correlation between the area occupied by CFI and the COX-2 immunoreactivity was not statistically significant in the groups studied (Figure 4A-F).

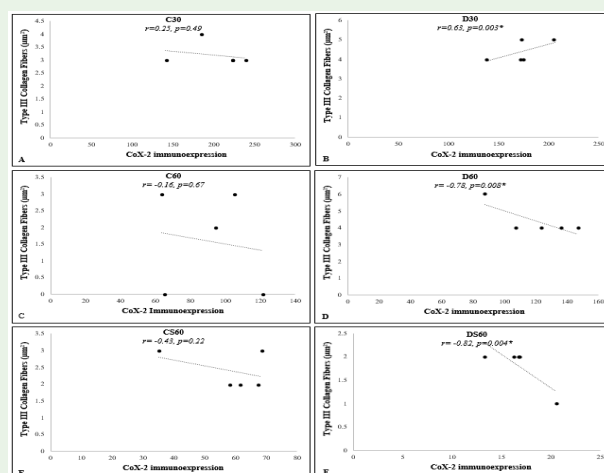


Figure 5: The correlation between the area occupied by type III collagen fibers and COX-2 immunoreactivity in the myocardium of the animals of groups C30 (A), D30 (B), C60 (C), D60 (D), CS60 (E) and DS60 (F). r = Person coefficient; p = significance level, * = $p < 0.05$. ($n = 5$).

However, when the area occupied by CFIII and the COX-2 immunoexpression were analyzed, a positive correlation was observed in the D30 group and negative in the D60 and DS60 groups ($p < 0.05$) (Figure 5B, D and F).

Discussion

Signals of changes was observed in D30 group, such as increased muscle area. According to Nakamura et al. [23], this is a possible indication of cardiachypertrophy in response to peripheral overload. This is followed by an onset of muscle loss, as observed in D60 animals. In a study previously conducted by Sciorati et al. [24], dystrophic animals showed decreased cardiomyocyte numbers in comparison to control animals and dystrophic animals treated with anti-inflammatories, as well as enlargement of cardiomyocytes, presence of fibrotic areas and inflammatory infiltrates [24]. The progressive cardiac muscle weakening causes dilated cardiomyopathy, which along with respiratory dysfunction [25] are among the main causes of mortality in DMD patients. Increasing muscle area in mice from D30 group was accompanied by an increase in total collagen fibers; this association indicates a possible fibrotic lesion process. In D60 animals, reduced muscle area was also accompanied by an increase of collagen fibers.

In DMD, fibrosis intensifies with age leading to loss of cardiomyocytes [26], corroborating the significant decrease in areas occupied by cardiac muscle tissue observed in dystrophic animals at 60 days of age (D60).

Some researchers believe that fibrosis occurs from replacing in replacement of injured muscle tissue [26,27]. However, others suggest that there is initially a swelling of the extracellular matrix and a subsequent increase of collagen fibers, leading to death of the muscle fiber [28]. In both cases, the increase of collagen is associated to muscle damage in dystrophic animals. The results of this study indicate that dystrophic animals at 30 days of age (D30) had increased collagen in relation to their control (C30). However, the area occupied by cardiomyocytes remained greater than in control animals. On the other hand, in animals at 60 days without supplementation, the collagen fibers decreased in D60 compared to C60, which would agree with Duance et al. [28], having initially found an increase of collagen fibers (as observed in animals D30), following muscle injury. However, in animals at 60 days of age supplemented with AA, there was a reduction in the area occupied by collagen fibers in DS60 and CS60, showing the protective effect of the Myo supplementation in this parameter.

Regarding the types of collagen fibers analyzed, CFI increased in untreated dystrophic groups (D30 and D60) in relation to their respective controls (C30 and C60) and supplemented groups (CS60 and DS60). As for CFIII, there was a reduction of the area occupied by the fibers in D60 in relation to D30 group. However, a significant decrease occurred in both analyzes in the areas occupied by CFI and CFIII types in supplemented animals compared to those who did not receive AA. The animals of groups D30 and D60 presented significant differences, as indicated in Figure 1, among some parameters analyzed. There was a significant reduction in the area occupied by cardiac muscle of D30 in relation to D60. However, this reduction is expected during the natural evolution of DMD, when the injured tissue is replaced by collagen fibers [26]. The total area occupied by

collagen showed no significant difference between these groups (D30 and D60). However, there were significant differences regarding the type of collagen presented: while D30 presented a larger area of CFIII, the D60 group obtained a higher average of CFI. These results are in agreement with what is expected in the context of DMD, since the younger dystrophic animals present more CFIII, characteristic of the beginning of the inflammatory process, whereas the older dystrophic animals have more CFI, which are present in the maturation process, characteristic of a late phase of tissue remodeling.

Duance et al. [28] reported that the deposition of CFIII is related to tissue response to injury, but that it decreases at more advanced stages of the disease as muscle fibers are replaced by fat tissue, and that CFIII are replaced by CFI.

The fibrosis that occurs after tissue injury occurs in phases: inflammation, proliferation and maturation. Initially there is an increase in the number of fibroblasts that produce and deposit large amount of CFIII. Throughout the process, the maturation occurs with remodeling and finally CFIII are replaced by CFI [29].

The data referring to CFI in D60 group confirms the fibrotic course of DMD, since there is increased deposition of such fibers in this group, resulting from an already established scarring process associated with decreased CFIII, the same as observed in the natural process of fibrosis. De Oliveira et al. [30] claim that mdx mice have higher amounts of CFI in the gastrocnemius muscle in comparison to normal mice, suggesting muscle fibrosis.

Increased collagen deposition in cardiac muscle tissue may affect it in different ways, from increasing the distance between cells and vessels, thickening muscle bundles, interfering in the transmission of mechanical tension between bundles and even hindering lateral transmission of contractile impulses. Furthermore, fibrosis reduces the compliance of vessels and hampers diastolic filling, which is predisposed to the development of cardiac failure [4,31].

In animals supplemented with AA, the total area occupied by collagen fibers decreased significantly ($p < 0.05$) in DS60 in comparison to D60, indicating the influence of AA on this parameter. The incidences of CFI and CFIII were lower ($p < 0.05$) in DS60 compared to their controls. These results show the potential protective and preventive action of AA in relation to DMD injuries, the consequent fibrosis and the damage associated with it.

Previous studies indicate that fibrosis is associated with loss of muscle function representing the most significant parameter related to poor motor prognosis in DMD [32,33], increasing the importance of the results obtained in this study regarding AA supplementation.

COX-2 is produced in response to cellular stress stimuli, such as the presence of inflammatory processes, growth factors or tumor factors. De Oliveira et al. [30] also detected a higher COX-2 immunoexpression in fibrotic areas of gastrocnemius muscle in mdx mice in comparison to control animals.

In the 30 day groups (C30 and D30), the expression of COX-2 was positive, indicating tissue growth, according to Aleakis et al. [13] and Sharma et al. [14]. However, the expression of COX-2 was even greater in dystrophic animals, also suggesting the presence of an inflammatory process, probably due to increased oxidative stress. In the D60 group, increased COX-2 expression was accompanied

by decreased area occupied by the myocardium, which in this case indicates oxidative stress, as well as changes in collagen indicating fibrosis [28,34]. Oxidative stress and fibrosis resulting from the initial inflammation process [10,30], as observed in D30 animals, affected cardiac muscle tissue promoting its reduction in D60 [24,26].

ROS play a key role in the course of DMD, leading to the oxidation of several proteins, and culminating in myocardial injury that with disease progression results in cardiac dysfunction [11]. According to Jung et al. [35], there is an increased ROS production in mdx animals, which contributes to cardiac dysfunction [34,36]. For this reason, treatments with antioxidant agents are important in order to prevent the development of cardiac failure and increase life expectancy [34].

In CS60 and DS60 animals, the immunoexpression of COX-2 was reduced in relation to their respective C60 and D60 controls, probably due to the antioxidant action of AA. Some substances have been analyzed in the pursuit of improving the quality and life expectancy of DMD patients. Among these are: immunosuppressants that in mdx mice promote reduction of cardiac fibrosis, of the systolic ejection fraction and ventricular mass [37]; and steroids, which reduce the number of deaths due to heart problems among DMD patients [38]. In addition to these, antioxidants which act by reducing free radical levels and oxidative stress [39], and therefore reduce damage caused by the muscle tissue of dystrophic animals have been widely studied [20,40].

Improvements in cardiac morphology and function in dystrophic patients have been reported with the use of N-acetylcysteine [11], quercetin [10], and green tea [41], among others.

AA is one of the most abundant antioxidants in nature and it has shown beneficial effects in studies related to cancer [42], in addition to acting on reducing the damage caused by oxidative stress in the diaphragm muscle of mdx mice [20]. In addition to the antioxidant function, AA has been used in cell cultures designed to develop functional cardiomyocytes. So far, the results indicate that AA acts directly to induce transdifferentiation of fibroblasts into cardiomyocytes, and therefore plays a vital role in human heart reprogramming [43].

Cardiac damage induced during embryonic development decreased with maternal AA supplementation [26]. Wannamethee et al. [44] observed that high AA blood concentrations decrease rates of cardiac failures and heart attack in senile men.

The results of this study indicate that there was an increase of the area occupied by collagen fibers in the heart of mice in the D30 group, followed by reduction of the area occupied by cardiomyocytes in D60, whereas supplementation with AA prevented muscle loss and collagen deposition in DS60 in animals. CFI occupied a larger area in the heart of D30 and D60 animals. However, DS60 group showed a decrease of these fibers in comparison to the other groups. In dystrophic animals, CFIII were more frequent in comparison to control animals only in D60, with a significant reduction of these fibers in the animals from group DS60.

Analyzes of the area occupied by CFI and CFIII and of COX-2 immunoexpression means that the C30 group had normal tissue development. However, in group D30 the increase of CFI indicates the onset of cardiac fibrosis and is associated with an attempt of tissue remodeling stimulated by the local inflammation process with the

increased production of immature collagen and the results showed that the changes did not occur on the mdx model as early as the first month of life. In D60, the concordance between the expression of COX-2 and CFIII and the increased of total collagen area, indicate the reduction mechanism of the cardiac fibrosis, suggesting replacement of cardiac tissue by mature collagen fibers. On the other hand, treatment with AA reversed muscle loss and reduction of ROS and COX-2 immunoexpression, suggesting that the inflammation is related to the progression of ROS, and that antioxidant treatments may contribute to the improvement of the quality of life of DMD patients.

Limitations

Mice of the mdx lineage develop a muscular atrophy similar to DMD. However, although they represent a good model to evaluate the repercussions of this disease, they present some phenotypic differences in relation to the symptoms, which are milder in the animals. Moreover, in mice, the disease goes into remission as the animals age, limiting the study time of the animals.

In addition, mdx is an animal that has a higher cost and is more difficult to obtain, which also limited the sample size used in this study.

Conclusion

We found that cardiac fibrosis in mdx mice with 30 and 60 days was correlated with increased oxidative stress and the AA acts by reducing the availability of ROS and thus reduces the occurrence of heart lesions in mdx mice. Improved quality of life of patients with DMD depends on both the improvement of skeletal performance as well as the development of therapies that delay disease progression and prolong cardiac functions. However, the exact molecular mechanism that culminates in cell vulnerability in DMD is still not fully elucidated. Thus, further studies are needed to clarify how this mechanism occurs and also to establish the optimal dosage of AA to be administered in humans.

References

- Villalta SA, Rosenberg AS, Bluestone JA. The immune system in Duchenne muscular dystrophy: Friend or foe. *Rare Dis.* 2015; e1010966.
- Parvatiyar MS, Marshall JL, Nguyen RT, Jordan MC, Richardson VA, Roos KP, et al. Sarcospan Regulates Cardiac Isoproterenol Response and Prevents Duchenne Muscular Dystrophy-Associated Cardiomyopathy. *J Am Heart Assoc.* 2015; e002481.
- Wang RT, Barthelemy F, Martin AS, Douine ED, Eskin A, Lucas A, et al. DMD genotype correlations from the Duchenne Registry: Endogenous exon skipping is a factor in prolonged ambulation for individuals with a defined mutation subtype. *Hum Mutat.* 2018; 1193-1202.
- Erp CV, Loch D, Laws N, Trebbin A. Timeline of cardiac dystrophy in 3-18-month-old mdx mice. *Muscle Nerve.* 2010; 504-513.
- Johnstone VP, Viola HM, Hool LC. Dystrophic Cardiomyopathy-Potential Role of Calcium in Pathogenesis, Treatment and Novel Therapies. *Genes (Basel).* 2017; E108.
- Nigro G, Comi LI, Politano L, Bain RJ. The incidence and evolution of cardiomyopathy in Duchenne muscular dystrophy. *Int J Cardiol.* 1990; 26: 271-277.
- Hori YS, Kuno A, Hosoda R, Tanno M, Miura T, Shimamoto. Resveratrol ameliorates muscular pathology in the dystrophic mdx mouse, a model for Duchenne muscular dystrophy. *J Pharmacol Exp Ther.* 2011; 338: 784-794.

8. Chenard AA, Becane HM, Tertrain F, de Kermadec JM, Weiss YA. Ventricular arrhythmia in Duchenne muscular dystrophy: prevalence, significance and prognosis. *Neuromuscul Disord*. 1993; 3: 201-206.
9. Shirokova N, Niggli E. Cardiac phenotype of Duchenne Muscular Dystrophy: Insights from cellular studies. *J Mol Cell Cardiol*. 2013; 58: 217-224.
10. Ballmann C, Hollinger K, Selsby JT, Amin R, Quindry JC. Histological and biochemical outcomes of cardiac pathology in mdx mice with dietary quercetin enrichment. *Exp Physiol*. 2015; 100: 12-22.
11. Williams IA, Allen DG. Intracellular calcium handling in ventricular myocytes from mdx mice. *Am J Physiol Heart Circ Physiol*. 2006; 292: H846-855.
12. Dubois RN, Abramson SB, Crofford L, Gupta RA, Simon LS, Van De Putte LB, et al. Cyclooxygenase in biology and disease. *FASEB J*. 1998; 12: 1063-1073.
13. Aleakis C, Partridge T, Bou-Gharios G. Implication of the satellite cell in dystrophic muscle fibrosis: a self-perpetuating mechanism of collagen overproduction. *Am J Physiol Cell Physiol*. 2007; 293: C661-C669.
14. Sharma A, Huard C, Vernochet C, Ziemek D, Knowlton Km, Tyminski E, et al. Brown fat determination and development from muscle precursor cells by novel action of bone morphogenetic protein 6. *PlosOne*. 2014; 9: e92608.
15. Kirkby NS, Chan MV, Zaiss AK, Garcia-Vaz E, Jiao J, Berglund LM, et al. Systematic study of constitutive cyclooxygenase-2 expression: Role of NF- κ B and NFAT transcriptional pathways. *Proc Natl Acad Sci*. 2016; 113: 434-439.
16. May JM. Is ascorbic acid an antioxidant for the plasm membrane? *FASEB J*. 1999; 13: 995-1006.
17. Wells DJ, Wells KE. What do animal models have to tell us regarding Duchenne muscular dystrophy? *ActaMyol*. 2005; 24: 172-180.
18. Banks GB, Chamberlain JS. The value of mammalian models for duchenne muscular dystrophy in developing therapeutic strategies. *Curr Top Dev Biol*. 2008; 84: 431-453.
19. Lorin C, Vögeli I, Niggli E. Dystrophic cardiomyopathy: role of TRPV2 channels in stretch-induced cell damage. *Cardiovascular Research*. 2015; 106: 153-162.
20. Tonon E, Ferretti R, Shiratori JH, Santo Neto H, Marques MJ, Minatel E. Ascorbic acid protects the diaphragm muscle against myonecrosis in mdx mice. *Nutrition*. 2012; 28: 686-690.
21. Soumaoro LT, Uetake H, Takagi Y, Iida S, Higuchi T, Yasuno M, et al. Coexpression of VEGF-C and COX-2 in Human Colorectal Cancer and its Association With Lymph Node Metastasis. *Dis Colon Rectum*. 2006; 49: 392-398.
22. Lisboa MJS, De Oliveira Lima MF, Stabille SR, Zanoni JN, Gagliardo KM, Souto MS, Souza R. Supplementation action with ascorbic acid in the morphology of the muscular layer and reactive acetylcholinesterase neurons of ileum of mdx mice. *Auton Neurosci*. 2017; 205: 57-66.
23. Nakamura A, Yoshida K, Takeda S, Dohi N, Ikeda S. Progression of dystrophic features and activation of mitogen-activated protein kinases and calcineurin by physical exercise, in hearts of mdx mice. *FEBS Letters*. 2002; 520: 18-24.
24. Sciorati C, Staszewsky L, Zambelli V, Russo I, Salio M, Novelli D, et al. Ibuprofen plus isosorbide dinitrate treatment in the mdx mice ameliorates dystrophic heart structure. *Pharmacol Res*. 2013; 73: 35-43.
25. Yasuda S, Townsend D, Michele DE, Favre EG, Day SM, Metzger JM. Dystrophic heart failure blocked by membrane sealant poloxamer. *Nat Cell Biol*. 2005; 436: 1025-1029.
26. Li Y, Zhang S, Zhang X, Li J, Ai X, Zhang L, et al. Blunted cardiac betaadrenergic response as an early indication of cardiac dysfunction in Duchenne muscular dystrophy. *Cardiovasc Res*. 2014; 103: 60-71.
27. Bridges LRL. The association of cardiac muscle necrosis and inflammation with the degenerative and persistent myopathy of MDX mice. *J Neurol Sci*. 1986; 72: 147-157.
28. Duan VC, Stephens HR, Dunn M, Bailey AJ, Dubowitz V. A role for collagen in the pathogenesis of muscular dystrophy? *Nature*. 1980; 284: 470-471.
29. Baptista E, Malafaia O, Czecko NG, Ribas-Filho JM, Nassif P, Nascimento MM, et al. Estudo comparado da cicatrização da prega vocal de suínos após exérese de fragmento com laser de CO₂ e aplicação tópica pós-operatória de mitomicina e 5-fluorouracil. *Acta Cir Bras*. 2009; 24: 13-18.
30. De Oliveira F, Quintana HT, Bortolin JÁ, Gomes AO, Liberti EA, Ribeiro DA. Cyclooxygenase-2 expression in skeletal muscle of knockout mice suffering Duchenne muscular dystrophy. *Histochem Cell Biol*. 2013; 139: 685-689.
31. Pelouch V, Dixon IMC, Golfman L, Beamish RE, Dhalla NS. Role of extracellular matrix proteins in heart functions. *Mol Cell Biochem*. 1994; 129: 101-120.
32. Klingler W, Jurkat-Rott K, Lehmann-Horn F, Schleip R. The role of fibrosis in Duchenne muscular dystrophy. *ActaMyologica*. 2012; 31: 184-195.
33. Desguerre I, Mayer M, Leturcq F, Barbet JP, Gherar RK, Christov C. Endomysial fibrosis in Duchenne muscular dystrophy: a marker of poor outcome associated with macrophage alternative activation. *J Neuropathol Exp Neurol*. 2009; 68: 762-773.
34. Mourkoti F, Kustan J, Kraft P, Day JW, Zhao MM, Kost-Alimova M, et al. Role of Telomere Dysfunction in Cardiac Failure in Duchenne Muscular Dystrophy. *Nat Cell Biol*. 2013; 15: 895-904.
35. Jung C, Martins AS, Niggli E, Shirokova N. Dystrophic cardiomyopathy: amplification of cellular damage by Ca²⁺-signalling and reactive oxygen species generating pathways. *Cardiovasc Res*. 2008; 77: 766-773.
36. Wang Q, Wang W, Wang G, Rodney GG, Wehrens XHT. Crosstalk between RyR2 oxidation and phosphorylation contributes to cardiac dysfunction in mice with Duchenne Muscular dystrophy. *J Mol Cell Cardiol*. 2015; 89: 177-84.
37. Ermolova NV, Martinez L, Vetrone SA, Jordan MC, Roos KP, Sweeney HL, et al. Long-term administration of the TNF blocking drug remicade (cV1q) to mdx mice reduces skeletal and cardiac muscle fibrosis, but negatively impacts cardiac function. *NeuromusculDisord*. 2014; 24: 7583-7595.
38. Schram G, Fournier A, Leduc H, Dahdah N, Therien J, Vanasse M, et al. All-cause mortality and cardiovascular outcomes with prophylactic steroid therapy in Duchenne muscular dystrophy. *J Am CollCardiol*. 2013; 61: 948-954.
39. Araújo ÉJ, Oliveira GA, Sousa LQ, Bolzani VD, Cavaleiro AJ, Tome AD, et al. Counteracting effects on free radicals and histological alterations induced by a fraction with casearins. *An Acad Bras Cienc*. 2015; 87: 1791-1807.
40. Hollinger K, Yang CX, Montz RE, Nonneman D, Ross JW, Selsby JT. Dystrophin insufficiency causes selective muscle histopathology and loss of dystrophin-glycoprotein complex assembly in pig skeletal muscle. *FASEB J*. 2014; 28: 1600-1609.
41. Buetler TM, Renard M, Offord EA, Schneider H, Ruegg UT. Green tea extract decreases muscle necrosis in mdx mice and protects against reactive oxygen species. *Am J Clin Nutr*. 2002; 75: 749-753.
42. Miles SL, Fischer AP, Joshi SJ, Niles RM. Ascorbic acid and ascorbate-2-phosphate decrease HIF activity and malignant properties of human melanoma cells. *BMC Cancer*. 2015; 15: 867.
43. Talkhabi M, Pahlavan S, Aghdami N, Baharvand H. Ascorbic acid promotes the direct conversion of mouse fibroblasts into beating cardiomyocytes. *BiochemBiophys Res Commun*. 2015; 463: 699-705.
44. Wannamethee SG, Shaper AG, Lennon L, Papacosta O, Whincup P. Mild hyponatremia, hypernatremia and incident cardiovascular disease and mortality in older men: A population-based cohort study. *Nutr Metab Cardiovasc Dis*. 2016; 26: 12-19.

Citation: De Oliveira Lima MF, De Oliveira F, Lisboa MS, Stabille SR, Da Purificação NRC, Soaressouto M, et al. Action of Ascorbic Acid Supplementation in The Prevention of Morphological Changes in the Myocardium in Mice with Muscular Dystrophy. *SM Musculoskelet Disord*. 2018; 3(2): 1030. <https://dx.doi.org/10.36876/smmd.1030>