

Multiple Exostosis Disease: Study of Three Senegalese Families

Niasse Moustapha^{1*}, Kane Baïdy Sy², Salissou Garba Mahaman¹, Sarr Lamine², Diouf Coumba¹, Akpo Géraud⁴, Diouf Alioune Badara³, Diallo Saïdou¹, Ndongo Souhaibou² and Pouye Abdoulaye²

¹Department of Rheumatology, Center Hospital Aristide Le Dantec, Dakar, Senegal

²Department of Internal Medicine, Center Hospital Aristide Le Dantec, Dakar, Senegal

³Department of Orthopaedics and Traumatology, Center Hospital Aristide Le Dantec, Dakar, Senegal

⁴Department of Radiology, Center Hospital Aristide Le Dantec, Dakar, Senegal

Article Information

Received date: Jan 28, 2019

Accepted date: Feb 15, 2019

Published date: Feb 19, 2019

*Corresponding author

Niasse Moustapha, Department of Rheumatology, Center Hospital Aristide Le Dantec, Dakar, Senegal; Tel: 00221775798892; Email: moustaphaniasse4@yahoo.fr

Distributed under Creative Commons CC-BY 4.0

Keywords Exostosis; Multiple exostosis disease; Osteochondroma

Article DOI 10.36876/smmd.1032

Abstract

Introduction: Multiple exostosis disease is rare. We report three familial forms of this disease found by a systematic screening of three cases.

Patients and Methods: Study carried out in the Rheumatology Department of the Aristide Le Dantec University Hospital in Dakar, between December 2015 and June 2018. We have collected patients from families with multiple exostosis disease.

Results: The family study included a total of 108 members, 15 of whom (13 male and 2 female) had multiple exostosis disease. The family prevalence was 13.88%. The average age was 6 years at the apparent onset of the disease and 21 years at diagnosis. The inbreeding rate was 55%. The average time to diagnosis was 15 years. The number of osteochondromas recorded in a patient varied between 4 and 17. Exostosis was localized to the limbs in 87.30% of cases and to the axial skeleton in 12.70% of cases. Standard radiographs showed sessile form in 14 patients and pedicular form in 2 patients. The evolution after the end of growth was marked by a recovery of activity. Osteo-articular complications and vascular compressions were noted in 5 and 3 cases respectively. No cases of malignant degeneration have been reported. Surgical treatment was performed in 3 cases.

Conclusion: Family character of the multiple exostosis disease in our patients is in favor of the implication of genetic factors in the determinism of the disease. We encourage systemic screening of the family for all cases of multiple exostosis disease.

Introduction

Exostosis is a benign tumour corresponding to a well-differentiated bone excrescence, produced by a germinal cartilage cap during growth [1,2]. It is most often sporadic, but it can also be part of an autosomal dominant, multiple exostosis disease known as Bessel-Hagen disease [1]. Exostosis, especially in its solitary form, represents the most frequent benign tumour (20 to 50% of benign bone tumours and 10 to 15% of all bone tumours) [1]. The multiple exostosis disease is a rare disease first described by Boyer in 1814 [3-5]. It is mainly reported in Western literature where its prevalence is estimated at 1/50,000 [3,5] and, to a lesser extent, in North Africa [6,7]. This prevalence has not been determined in the African population. However, work has been carried out on the disease in North Africa and sub-Saharan Africa [3-12]. Studies evaluating family forms of the disease were mainly carried out in the Western literature [12-18]. In sub-Saharan Africa, reported cases are apparently sporadic. The objective of this work was to study the epidemiological, diagnostic and therapeutic aspects of familial forms of multiple exostosis disease.

Patients and Methods

The present work was a retrospective transversal study in the Department of Rheumatology, Le Dantec Teaching Hospital of Dakar. We received three unrelated patients at consultation in December 2015, March 2016 and June 2018 for diffuse masses. The diagnosis of multiple exostosis disease was made in these patients on the basis of epidemiological, clinical, biological, radiological and histological arguments. The information provided by the index cases made it possible to create family trees. Then, a systematic screening for other family cases of multiple exostosis disease was carried out after obtaining consent.

Screening was performed on relatives: parents, brothers, sisters or children in the first degree; uncles, aunts or grandparents in the second degree; and first cousins in the third degree. The following data were specified for each patient: epidemiological data (age at the onset and diagnosis of the disease, sex, geographical origin); clinical data (the number of exostosis, their size, their topography, the painful or painless nature); biological data (absence of inflammatory syndrome,

OPEN ACCESS

ISSN: 2576-5442

absence of phosphocalcic metabolic disorder); radiological data (standard radiographic data, angioscanner data of the lower limbs); histological data (histological examination of biopsy parts or exostosis operations); and evolutionary data after the end of growth. In the evolutionary data, the following were recorded: stabilisation; resumption of activity (occurrence of pain or increase in volume of osteochondromas); malignant degeneration; occurrence of osteo-articular complications (bone deformation, shortening of a bone, fracture, joint deformation especially at the knees [genu varum, genu valgum, genu recurvatum, flessum of the knee]); occurrence of compression of adjacent structures (vascular [arterial and/or venous], nerve compression); and therapeutic data (symptomatic pain management [analgesics, non-steroidal anti-inflammatory drugs], surgical treatment [removal of exostoses]).

Results

Description of index case observations

The first index case: This was a 28-year-old man who had been seen for painless bony swelling since the age of 8 years. The swellings were located at the distal third of the right forearm, distal thirds of the thighs and proximal thirds of the legs. They were of variable size, between 2 and 12 cm (Figure 1). The examination also found a dilated and sinuous appearance of the superficial veins in the left lower limb (Figure 1). Peripheral arterial pulses were perceived, synchronous and symmetrical. The rest of the clinical examination was normal. Biological explorations did not find inflammatory syndrome, while calcaemia and phosphataemia were normal. Standard radiographs objectified multiple bone growths of sessile appearance. They were located at the metaphyses of the right radius, femurs, tibias and fibula. Moreover, the angio scanner of the lower limbs showed continuity of the spongy bone and the cortex between the osteochondromas and the supporting bones. It revealed vascular compressions in the veins (superficial and deep) and left popliteal artery (Figure 1). Thus, the diagnosis of multiple exostosis disease complicated by arteriovenous compression was retained. The patient was then referred to orthopaedic for surgical resection of the compressive osteochondromas.

The second index case: A 42-year-old male was observed for diffuse bone masses evolving since the age of 2 years (Figure 2). He had previous consultations at traditional practitioners but was assessed in our department because he had a painful bone mass. The clinical evaluation showed tumefactions with the bone mass between 3.5 and 6 cm in size. They were located at the distal ends of the upper limbs, at the left elbow and at the lower limbs (proximal and distal ends of the legs and distal end of the right thigh) (Figure 2). A painful mass was also felt on the left flank and was part of the iliac bone. There was a dysmorphic syndrome responsible for limb inequality, characterised by curvature of the forearms and a left genu valgum. There was no inflammatory syndrome or phosphocalcic metabolic disorder. Standard radiographs found multiple sessile-like bone growths in the limbs. They were located in the bone metaphyses and left iliac bone with a hypertrophic and heterogeneous appearance. They confirmed the deformations of the forearm bones with a shortening of the left radius associated with ulno-humeral dislocation on the homolateral side. Surgical removal of the left iliac mass was performed. Histological examination of the operating room eliminated a neoplastic process. He was in favour of an osteochondroma by finding bone and cartilage tissue casings. The bone tissue was compacted by regular bone that spans around the Haversian canal. The cartilage tissue contained medullary tissue with fibrous reworking. The diagnosis of a multiple exostosis disease was retained.

The third index case: A 31-year-old man had been consulted for diffuse bone masses since the age of 18. On examination, the bone masses at the lower end of the thighs and forearms, at the upper end of the legs and on the left scapula (Figure 3). Their diameters varied between 3 and 5 cm at the limbs and their evolution was stationary. The mass on the scapula was characterised by intermittent pain and measured 13 cm from the major axis. The forearms were deformed with a curved aspect (Figure 3). The thoracic tomodensitometry showed the exostosis developed on the scapula, and the diagnosis of multiple exostosis disease was retained (Figure 3).

Description of the Families

The three families had a total of 108 members. Fifteen of them had multiple exostosis disease. There were 13 men and 2 women (sex

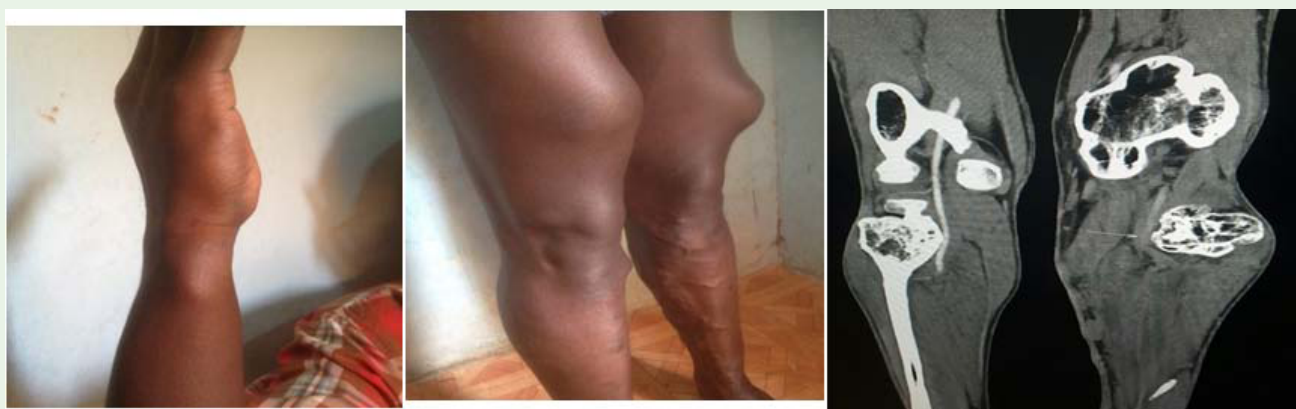

Figure 1: Bone swelling in the distal third of the right forearm and distal third of the thighs and proximal third of the legs. They are associated with varicose veins in the left leg. The angiography scan of the lower limbs shows a continuity between the spongy bone spans and the cortical spans of exostosis and carrier bones (green arrow). It shows close contact between an osteochondroma of the upper end of the left tibia and the left popliteal artery. The right leg tripod has contrasts hot unlike its left counterpart (blue arrows). There is also deep venous dilation and varicose veins of the superficial network (orange arrows).

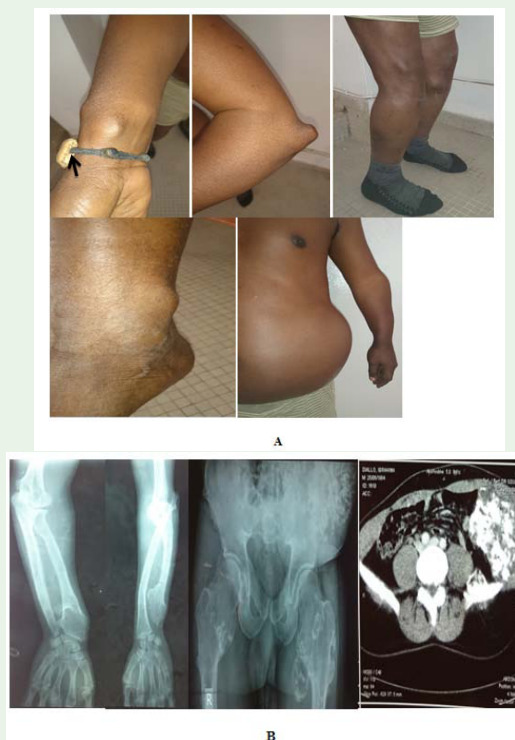

Figure 2A: Bone swelling in the upper limbs (distal extremities), left elbow, lower limbs (proximal and distal extremities of the legs) and left flank.

Figure 2B: Radiological images of exostoses corresponding to these swellings. Use of the traditional practitioner: amulet on the right forearm (black arrow).

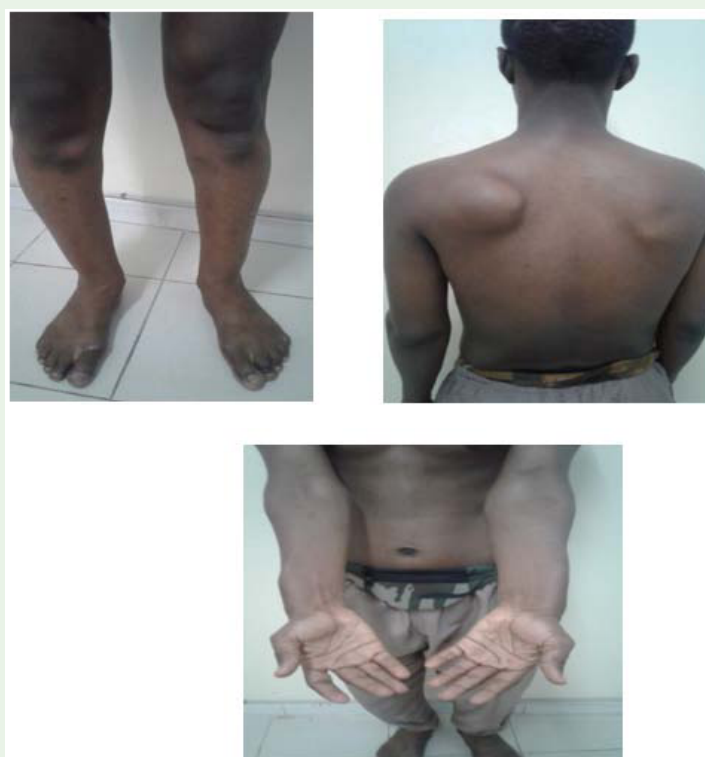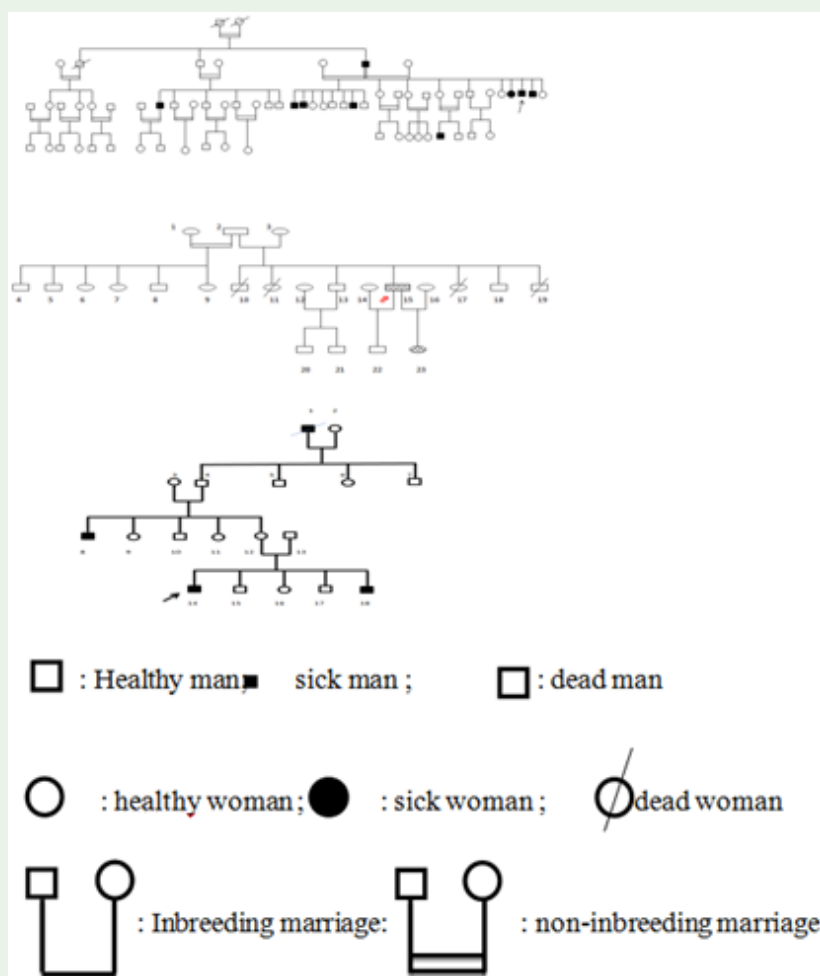


Figure 3: Bone swelling in the lower limbs and on the left scapula. Incurvation of the medially concaved forearms. The thoracic scan shows exostosis developed at the expense of the left scapula.

Table 1: Distribution of the disease according to the parental degree.

Parental degree	Number of cases	Frequency
First degree	11	10,18%
Second degree	4	3,70%
Third degree	0	0%

ratio: 6.5). Family prevalence was 13.88% (Figure 4). The degrees of kinship between the index cases and the other members are presented in Table 1. The average age was 6 years at the onset of the disease (extremes: 1 and 18 years) and 21 years (extremes: 9 and 31 years) at the time of diagnosis. The inbreeding rate was 55%, while the average age to diagnosis was 15 years (extremes: 8 and 18 years). Moreover, the number of osteochondromas recorded in a patient ranged from 4

**Figure 4:** Trees of families: the family tree of the 1st case index at the top, the familial tree of the 2nd case index in the middle and the familial tree of the 3rd case index below.**Table 2:** Distribution of exostosis at the peripheral skeleton level.

Humerus				Radius/Ulna					Femur	Tibia/Fibula		
	R	L	Total	R	L	Total	R	L	Total	R	L	Total
P	3	4	7	2	1	3	1	2	3	8	10	18
			(9,45 %)			-4%			-4%			
D	2	1	3 (4%)	5	3	8	7	9	16 (21,60%)	3	4	7(11,47%)
			(10,80%)									
Total	10			11 (14,86%)			19			25 (33,78%)		
	(13,50 %)						(25,67%)					

P: Proximal portion of the bone D: Distal portion of the bone R: Right, L: Left.

Citation: Niasse M, Kane BS, Garba MS, Sarr L, Diouf C, Akpo G, et al. Multiple Exostosis Disease: Study of Three Senegalese Families. SM Musculoskelet Disord. 2019; 4(1): 1032.
<https://dx.doi.org/10.36876/smmd.1032>

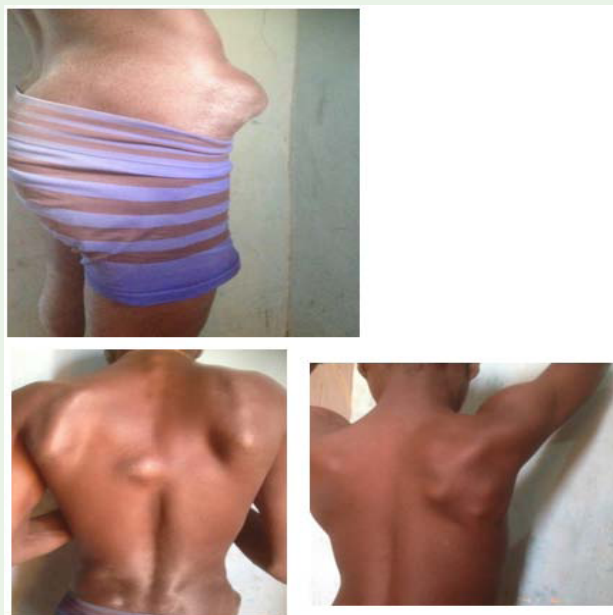


Figure 5: Exostosis localized at the axial skeleton level in relatives of the first case index.

Table 3: Distribution of exostoses at the axial skeleton level.

Ribs	2 (2,70%)
Clavicle	1 (1,35%)
Scapula	2 (4,05%)
Thoracispine	1 (1,35%)
Pelvi	2 (2,70%)
Total	9 (12,16%)

to 17. Exostoses were localized to the limbs in 87.30% of cases (upper limbs: 38.18%; lower limbs: 61.82%) and to the axial skeleton in 12.70% of cases (Figure 5). Their detailed topographical description is given in Tables 2 and 3. Additionally, they were all painless during the growing season.

Standard radiographs showed a sessile aspect of exostosis localized to the limbs in 14 patients and a pedicle aspect in 2 patients. There was a patient who had both aspects. After the end of the growth period, the trend was marked by a resumption of activity in

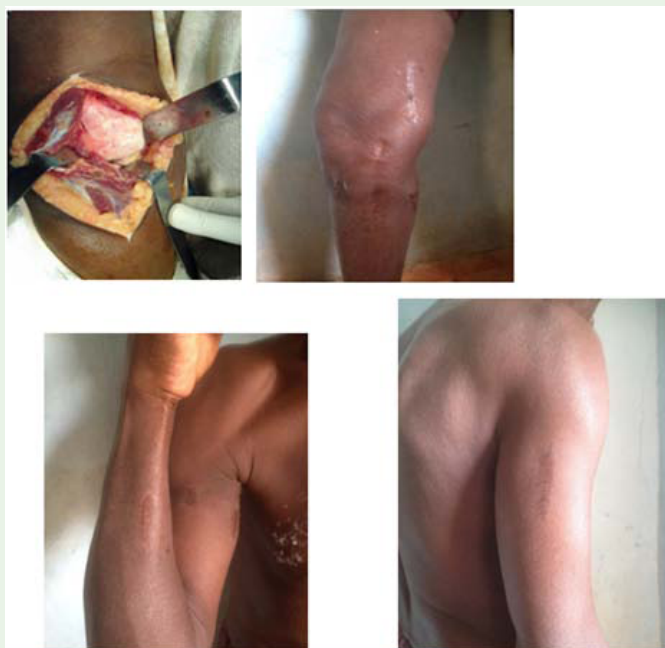

Figure 6: A. Surgical resection of the exostosis of the right humerus in one of our patient. B, C and D: Post-surgical scars in one of our patient.

6 cases. Osteo-articular complications and vascular compressions were noted. Osteo-articular involvement was in the form of forearm curvature in 3 cases and knee deformities in 2 cases (a valgum knee). Vascular compressions involved the lower limb veins (superficial in 2 cases and deep in 1 case) and the left popliteal artery in 1 case. Any compression of nerve structures had been objectified. We did not find any malignant degeneration. Moreover, treatment in patients with reactivated disease was based on the use of analgesics and non-steroidal anti-inflammatory drugs. Surgical resection of exostosis was carried out in three of these patients (Figure 6).

Discussion

We performed a familial screening from three index cases of multiple exostosis disease, and we report in this study three family forms of this disease. The disease is essentially reported in Western literature, where its prevalence is estimated at 1/50,000 [2,14,15] as well as its familial forms [15,18]. In North Africa, only one Tunisian study was interested in the family cases of the hereditary multiple exostoses [7]. In sub-Saharan Africa, reported cases are apparently sporadic. To our knowledge, they come from Congo (4 cases) [19], Senegal (3 cases) [8,20,21], Ivory Coast (1 case) [3] and Burkina (1 case) [11].

The family prevalence of multiple exostosis disease was 13.88% in our study, much higher than that reported in the Western population. This reflects an aggregation of the disease in our families [1,2,15,22]. A similar study conducted in India confirms the same findings, with a higher prevalence at 27% [15]. This suggests the involvement of genetic factors, although the involvement of epigenetic factors cannot be excluded [16]. The higher frequency among first degree relatives (10.18%), compared to second (3.70%) and third degree (0%), suggests both a multifactorial and polygenic character of this heredity [15].

The mode of transmission of the disease was difficult to establish in our study. Due to the insufficiency of our technical platform, genetic analysis could not be carried out on our patients. However, the literature data show a mutation of at least one of the three genes: EXT1, EXT2 and EXT3 found in 90% of cases with autosomal dominant transmission [2,14,23,24]. These tumour suppressor genes, located respectively on chromosomes 8q23-q24, 11p11-p12 and the short arm of chromosome 19, encode glycosyltransferases (exostosins), which are enzymes involved in the polymerisation of heparan sulphates. Heparan sulphates are proteoglycans located on the surface of cells and in the extracellular matrix [5,25]. A significant decrease in their levels or their poor quality (truncated chains) would disturb the growth plate and/or perichondrial function. Moreover, they are said to be responsible for the occurrence of exostosis [26, 27]. The mechanism involves signalling pathways through the Bone Morphogenetic Protein (BMP) and Hedgehog (Hh) family members: sonic hedgehog (SHH) and Indian hedgehog (IHH) receptors [26,27]. BMP and Hh are factors that promote stem cell differentiation to osteogenesis by decreasing adipogenesis [26,27]. However, 10 to 15% of multiple exostosis disease are sporadic, suggesting the involvement of other factors, particularly epigenetics [26,27]. These environmental factors can be traumatic, physical (radiation during childhood) or infectious (osteomyelitis) [1]. In our study, the existence of similar cases, mainly among first degree relatives, was in favor of a hereditary origin of the disease [15,20]. This hypothesis was reinforced by the high

inbreeding rate in families (55%) and the absence of environmental factors induced in our patients. The male predominance in our study patients is consistent with the data in the literature [1,2]. Exostoses are more frequently encountered in men, with a sex ratio varying from 1.6 to 3.4 [1]. The age at the apparent onset of the disease was on average 6 years in our study. Indeed, exostoses are the prerogative of a child where they develop during the growth period [1,2]. Thus, the diagnosis of multiple exostosis disease is often made early, in most cases before the age of 12 years due to the accessibility of bone masses [2]. In our study, the diagnosis was made at an older age with an average delay of 15 years after the onset of symptoms. This delay in consultation in our patients could be explained by the painless nature of the osteochondromas during the growth period. As such, index cases 2 and 3 only consulted after having presented painful exostoses after 40 and 13 years of evolution, respectively.

In our study, exostosis was mainly localised at the level of the limb metaphyses and predominant at the knees (including the lower extremities of the thighs and upper legs), then at the lower extremities of the forearms and finally at the upper arms and lower legs. This topographical distribution is in accordance with the literature [2,27]. The preferential localisation of exostoses reflects their pathogenesis: (i) they are absent from bones with membrane ossification, which directly give bone tissue without intermediate cartilage tissue (face, skull vault), and (ii) they are present essentially on bones with chondral ossification, which produce bone tissue via intermediate cartilage tissue (metaphyseal variant of long bones and some flat or short bones) [2,27]. However, more rarely described locations have been found in our patients, including spinal, iliac, scapular, clavicular and costal [7,15]. The diagnosis of exostosis is essentially radiological [13,28]. In the typical form, histology is not required [1]. The radiological forms of exostosis are multiple, but can be individualized into three types: (i) pedicle forms, which are narrow implantation and always inclined towards the diaphysis; (ii) sessile forms, which are those found in our patients and characterized by a wide implantation on the metaphysis and diaphysis; and (iii) cauliflower forms [13,28]. The pathognomonic radiological sign, easily identified on tomodensitometric images and detected in the first case index in our study, is the evidence of the continuity of the cancellous bone and the cortex between the osteochondroma and the carrier bone [1].

Depending on its location and volume, exostosis can be responsible for complications that may be frightening but rarely revealing, including osteo-articular complications (deformities, bone fractures, osteomyelitis) and compression of adjacent structures [3,13,15,29,30]. Thus, osteo-articular deformities responsible for limb inequality were identified in two cases in our study. In addition, arterial and venous compressions were noted in two cases. One of the most striking deformities observed in our patients is the short, curved forearm, which is found in up to 60% of cases [2]. The inequality in length of the lower limbs is often due to a knee deformity. According to Clement et al., this deformity is usually in the form of a valgum knee, as in our study [2,31].

Vascular complications are rare, observed in 11% of cases [5,21]. In a literature review from 1965 to 2013, we identified only 57 cases of vascular complications of osteochondromas of the lower limbs [5,13,21]. They include vessel compression, stenosis, thrombosis,

arteriovenous fistulas and pseudo-aneurysms [1,5]. These vascular complications are believed to result from the “trapping” of vascular structures by adjacent exostoses [5]. Damage to the popliteal artery, found in our study, is the most common vascular complication (91% of cases) due to the frequent location of osteochondromas at the lower end of the femur and upper end of the tibia [5,11]. The associated venous and arterial compressions were the originality of this observation [5,11]. Moreover, the most serious complication is malignant degeneration into chondrosarcoma in 90% of cases [2]. This possibility, not found in our study, is reported in about 2% of cases in more recent series [2,32]. The predictive signs of malignant degeneration include certain localisations (pelvic, upper extremities of the femur, shoulders), resumption of osteochondromal activity after the end of growth (onset of pain, increase in volume) and thickness of the cartilage cap greater than 2 cm [1,2,32]. Six patients had a resumption of exostosis activity leading to surgical resection in three cases. The surgical indication also arises in the face of compression of adjacent structures, including neurological and vascular structures (found in two of our patients) [1,32,33], or in order to correct bone deformities, particularly in the limbs [2,32]. As a result, regular monitoring has been established in all our patients.

Conclusion

The family forms of multiple exostosis disease were characterized in our study by an early onset and family aggregation of the disease. The attack was diffused, interestingly in both the peripheral and axial skeleton. We also noted orthopaedic and systemic complications (vascular compressions) and highlighted the importance of systematic family screening of all cases of multiple exostosis disease. This would reduce the diagnostic delay and the occurrence of complications.

References

- Moatassim Billaha N, Idrissia MM, Idrissi Kaitounib R, Faraja H, El Yaacoubib M, Bouklataa S. Imaging of solitary exostoses. *Feuillets de radiologie*. 2013; 53: 11-20.
- Rambeloarisoa J, El Guedja M, Legeai-Mallet L, Zagdanski AM, Délépine G, Le Merrer M, et al. Hereditary multiple exostoses with 40 years follow-up: case report. *Rev Méd Interne*. 2002; 23: 657-664.
- Bamba I, Sie-Essoh JB, AkaKacou D, Assi-Djebidje V, Kodo M, Dao A, et al. Multiple exostoses. Review of the literature. Apropos of a case disclosed during an injury. *Bull Soc Pathol Exot*. 2002; 95: 83-85.
- Sonne-Holm E, Wong C, Sonne-Holm S. Multiple cartilaginous exostoses and development of chondrosarcomas-a systematic review. *Dan Med J*. 2014; 61: A4895.
- Toumi S, Ghnaya H, Essid A, Braham A, Jerbi S, Mrad-Daly K, et al. Hereditary multiple exostosis revealed by deep vein and arterial popliteal thrombosis. *Rev Med Interne*. 2010; 31: e7-e10.
- Ameziane L, EL Bardouni A, Mahfoud M, Berrada MS, Ouazzani N, EL Yaacoubi M, et al. Exostosis of limbs. *Médecine du Maghreb*. 1999; 75: 33-35.
- Sfar S, Abid A, Mahfoudh W, Ouragini H, Ouechtati F, Abdelhak S, et al. Genetic analysis of hereditary multiple exostoses in Tunisian families: a novel frame-shift mutation in the EXT1 gene. *Mol Biol Rep*. 2009; 36: 661-667.
- Diallo S, Niasse M, Diallo R, Diouf C, Sané AD. Hereditary multiple exostoses: A case-report. *Joint Bone Spine*. 2016; 83: 455.
- Jacobson LS, Kirberger RM. Canine multiple cartilaginous exostoses: unusual manifestations and a review of the literature. *J Am Anim Hosp Assoc*. 1996; 32: 45-51.
- Volchansky A. Clinical study of mandibular exostoses in South African Caucasoids. *J Dent Assoc S Afr*. 1986; 41: 139-141.
- Dao F, Yonaba C, Diallo O, Traore O, Traore A, Ayereoue J, et al. Bessefhogen's disease or illness exostosis' disease with spinal cord compression: about a case in the service of the paediatric CHU Ouedraogo, Ouagadougou, BF. *Mali Médical*. 2013; 1: 47-48.
- Govender S, Parbhoo AH. Osteochondroma with compression of the spinal cord. A report of two cases. *J Bone Joint Surg Br*. 1999; 81: 667-669.
- Nasr B, Albert B, David CH, Marques da Fonseca P, Badra A, Gouny P. Exostoses and vascular complications in the lower limbs: two cases report and review of literature. *Ann Vasc Surg*. 2015; 29: 1315-1319.
- Cook A, Raskind WH, Blanton SH, Pauli RM, Gregg RG, Francomano CA, et al. Genetic Heterogeneity in Families with Hereditary Multiple Exostoses. *Am J Hum Genet*. 1993; 53: 71-79.
- Kalyani R, Prabhakar K, Gopinath B, SheikNaseer B, Krishnamurthy DS. Multiple Hereditary Exostoses in a Family for Three Generation of Indian Origin with Review of Literature. *Journal of Clinical and Diagnostic Research*. 2014; 8: LD01-LD03.
- Mota López A, García-Roméu García C, Sanjose Pacheco F, García Carlos E, Pedauye González JM, Caturla Such J. Review of exostosing disease apropos of the study of a family with 14 carriers of multiple exostoses. *Rev Clin Esp*. 1977; 15: 144: 350-360.
- Zhuang L, Gerber SD, Kuchen S, Villiger PM, Trueb B. Deletion of exon 8 from the EXT1 gene causes multiple osteochondromas (MO) in a family with three affected members. *SpringerPlus*. 2016; 5: 71.
- Raskind WH, Conrad EU, Matsushita M, Wijsman EM, Wells DE, Chapman N, et al. Evaluation of Locus Heterogeneity and EXT1 Mutations in 34 Families With Hereditary Multiple Exostoses. *Human Mutation*. 1998; 11: 231-239.
- Ntsiba H, Bazébis R. Multiple exostoses. The first 4 Congolese cases. *Bull Soc Pathol Exot*. 2002; 95: 20-22.
- Niasse M, Kane B.S, Mbodji M.M, Akpo G, Diallo S. Painless out growth bones: Multiple exostosis diseases. *Presse Med*. 2016; 45: 710-712.
- Kane BS, Niasse M, Akpo G, Mbodji MM, Ndongo S, Diémé C, Pouye A. Disseminated masses. *Rev Méd Interne*. 2017; 38: 562-563.
- Feingold J. Multifactorial diseases: a nightmare for the geneticist. *Med Sciences*. 2005; 21: 927-233.
- Xia P, Xu H, Shi Q, Li D. Identification of a novel frame shift mutation of the EXT2 gene in a family with multiple osteochondroma. *Oncology Letters*. 2016; 11: 105-110.
- Shieh YE, Wells DE, Sater AK. Zygotic expression of Exostosin1 (Ext1) is required for BMP signaling and establishment of dorsal-ventral pattern in *Xenopus*. *Int J Dev Biol*. 2014; 58: 27-34.
- Okada M, Nakanaka S, Shoji N, Tamura J, Kitagawa H. Biosynthesis of heparan sulfate in EXT1-deficient cells. *Biochem J*. 2010; 428: 463-471.
- Billings PC, Pacifici M. Interactions of signaling proteins, growth factors and other proteins with heparan sulfate: Mechanisms and mysteries. *Connect Tissue Res*. 2015; 56: 272-280.
- Jochmann K, Bachvarova V, Vortkamp A. Reprint of: Heparan sulfate as a regulator of endochondral ossification and osteochondroma development. *Matrix Biology*. 2014; 35: 239-247.
- Westhoff B, Stefanovska K, Krauspe R. Hereditary multiple exostoses. *Orthopäde*. 2014; 43: 725-732.
- Stieber JR, Dormans JP. Manifestations of hereditary multiple exostoses. *J Am Acad Orthop Surg*. 2005; 13: 110-120.
- Zaijun L, Xinhai Y, Zhipeng W, Wending H, Quan H, Zhenhua Z, et al. Outcome and prognosis of myelopathy and radiculopathy from osteochondroma in the mobile spine: a report on 14 patients. *J Spinal Disord Tech*. 2013; 26: 194-199.

Citation: Niasse M, Kane BS, Garba MS, Sarr L, Diouf C, Akpo G, et al. Multiple Exostosis Disease: Study of Three Senegalese Families. *SM Musculoskelet Disord*. 2019; 4(1): 1032.
<https://dx.doi.org/10.36876/smmd.1032>

31. Clement ND, Porter DE. Can deformity of the knee and longitudinal growth of the leg be predicted in patients with hereditary multiple exostoses? A cross-sectional study. *Knee*. 2014; 21: 299-303.
32. Czajka CM, DiCaprio MR. What is the Proportion of Patients with Multiple Hereditary. *Clin Orthop Relat Res*. 2015; 473: 2355-2361.
33. Marginean CO, Melit LE, Marginean MO. Daughter and mother diagnosed with hereditary multiple exostoses. A case report and a review of the literature. *Medicine*. 2017; 96: e5824.