

Ledderhose's Disease-What do We Know and What do We not know

Ingo Schmidt*

Department of Orthopaedics, Medical center in Wutha-Farnroda, Teaching Hospital of the Friedrich-Schiller University Jena, Germany

Article Information

Received date: Jan 28, 2019

Accepted date: Mar 05, 2019

Published date: Mar 08, 2019

*Corresponding author

Ingo Schmidt, Department of Orthopaedics, Medical center in Wutha-Farnroda, Teaching Hospital of the Friedrich-Schiller University Jena, Germany,
Email: schmidtingo62@googlemail.com

Distributed under Creative Commons CC-BY 4.0

Keywords Foot; Plantar aponeurosis; Ledderhose's disease

Article DOI 10.36876/smmd.1033

Abstract

Plantar fibromatosis of the foot (i.e. Ledderhose's disease) is a rare benign but local aggressive disease of the plantar aponeurosis (i.e. fascia) with unknown etiology. Histopathological findings in plantar fibromatosis reveal similar findings to those in palmar fibromatosis (i.e. Dupuytren's disease), and genetic factors (i.e. familial history) for its appearance seems to be of relevance. Treatment options include various non-surgical and surgical procedures; however, progression of disease after non-surgical treatment and recurrence after surgery is a concern. But in trend, total plantar fasciectomy seems to be superior compared to all other procedures. The aim of this short review article is to give practicable interdisciplinary insights on a surgeon's perspective for all clinicians who are confronted with this rare disease including various differential diagnoses related to chronic plantar foot pain, and possible complications after its treatment.

What is Ledderhose's disease?

Plantar fibromatosis of the foot is a rare benign, hyperproliferative, and local aggressive disease of the plantar aponeurosis (i.e. fascia) (Figure 1A) of unknown etiology and included among the extra-abdominal desmoids tumors, this entity was first described in 1894 by the German physician Georg Ledderhose (1855-1925), and it is accompanied by a high recurrence rate [1-3]. Regarding etiology, it has been described to be most frequent in patients with diabetes, low body weight, epilepsy, alcohol abuse, and smoking, and a familial history in up to 19.1% of cases is observed as well [2,4]. Occurrence is observed at all ages ranging from 2 to 83 years (N=178), but especially in the 4th and 5th decade of life in the absence of significant sex-related differences (51.7% male vs. 48.3% female in 178 patients), and bilateral involvement is reported to be 20-50% of cases [2,4]. It can be associated in 5-21.3% of cases with the palmar fibromatosis of the hand (Figure 2A-D) first described quite earlier in 1831 by the French physician Baron Guillaume Dupuytren (1777-1835) which can also be associated with the fibrous subcutaneous nodules (i.e. knuckle pads) upon the proximal interphalangeal finger joints (Figure 3) first described in 1904 by the British physician Sir Archibald Edward Garrod (1857-1936), and in 1-3% of cases with the penile fibromatosis first described substantial quite earlier in 1743 by the French physician François Gigot de la Peyronie (1678-1747) [2,5-12]. Histopathological findings in plantar fibromatosis reveal similar findings to those in palmar fibromatosis [13]. In the literature, it has been proposed for palmar fibromatosis that growth factors, such as platelet-derived growth factor and transforming growth factor-beta, free oxidized radicals, increased levels of plasminogen activator enzymes, and expression of Ki-67 antigen contribute the etiology, and it was found that the number of androgen receptors in specimens of palmar fibromatosis was considerably higher than in normal palmar fascia [14-19]. Noted that expression of the Ki-67 antigen plays an important role in detection of malignancies [20]. For the palmar fibromatosis, family history probably has the strongest influence on the age at time of first surgery compared to environmental factors, followed by male sex, and the percentage of familial cases decreased with age of onset from 55% in patients aged 40-49 years to 17% in patients aged 80 years and older, and men are up to 15 times more likely to suffer from this disease but during the 8th and 9th decade of life the ratio between affected men and women is equal [21,22]. Moreover, palmar fibromatosis is more frequently observed in the white Caucasian and Nordic race than in Africa or Asia [23]. Noted that the incidence of palmar fibromatosis in elderly men is reported to be up to 25.3% in Australia [24], up to 28.9% in Ireland [25], and up to 13.75% in England [26]. The differential diagnosis of plantar fibromatosis should include stenosing tenosynovitis, ganglion cyst of the ankle with medial plantar nerve entrapment (i.e. tarsal tunnel syndrome) (Figure 4A-B), other conditions leading to entrapment of plantar digital nerves such as the primary Morton's neuroma (Figure 5A-C) or secondary post-traumatic/post-operative neuroma (Figure 6A-C), plantar fasciitis or rupture with or without plantar calcaneal spurs (Figure 7 compared to Figure 8), heel bursitis with or without Haglund's exostosis (Figure 7 compared to Figure 8), aseptic osteonecrosis such as Köhler's disease (Figure 9), or other benign or malignant lesions (Figure 10), including fibrosarcoma [27,28].

OPEN ACCESS

ISSN: 2576-5442

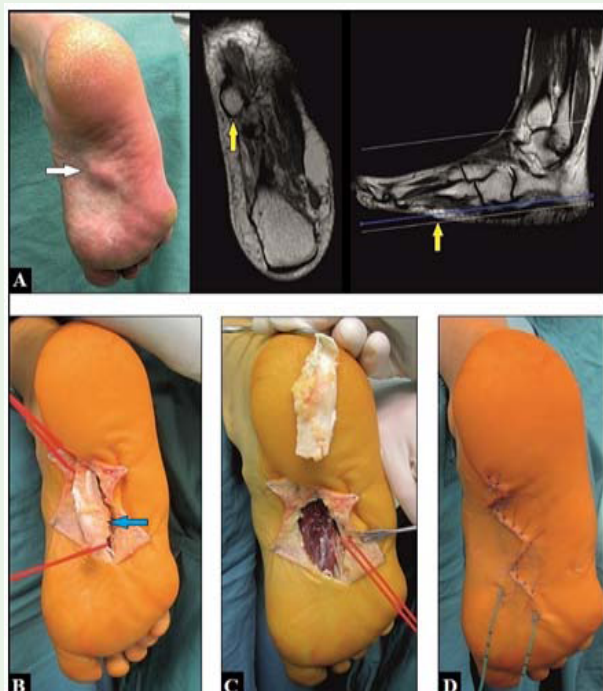


Figure 1: (54-year-old female, plantar fibromatosis, right foot): (A) Preoperative clinical findings and magnetic resonance imaging, the nodule is partially adherent to the skin (arrows). (B) Intraoperative, after careful dissection of the nodule (arrow) from the skin. (C) Intraoperative, after total fasciectomy. (D) Intraoperative, primary closure of wound, the further course was uneventful.

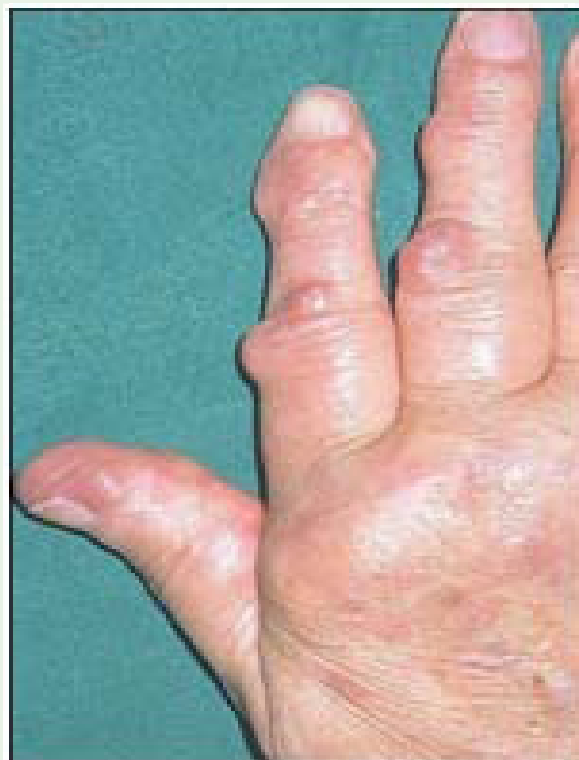

Figure 3: (67-year-old female, right hand): Palmar fibromatosis associated with the typical knuckle pads upon the proximal interphalangeal joints of the index and middle finger.

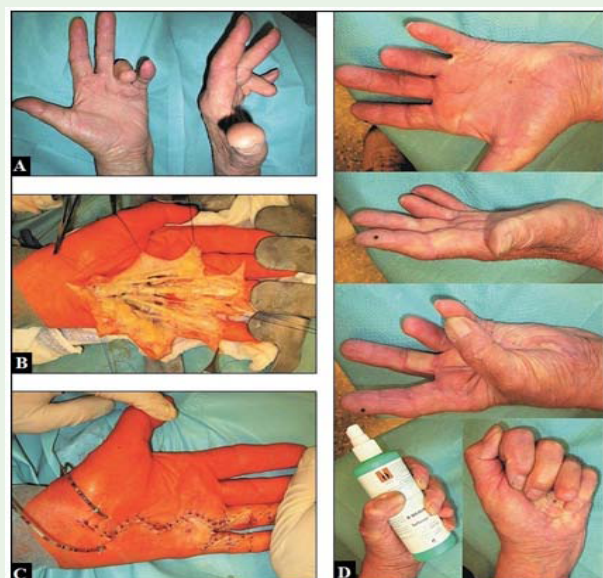


Figure 2: (57-year-old male, advanced stage of palmar fibromatosis, left hand): (A) Preoperative, passive fixed flexion contractures of the 4th and 5th finger. (B) Intraoperative, the total fasciectomy was performed; all neurovascular bundles and pulleys were safely spared. (C) Intraoperative, primary closure wound, the further course was partially complicated by delayed wound healing without the need of secondary coverage. (D) At the 1-year follow-up there was a good restoration of the overall hand function.

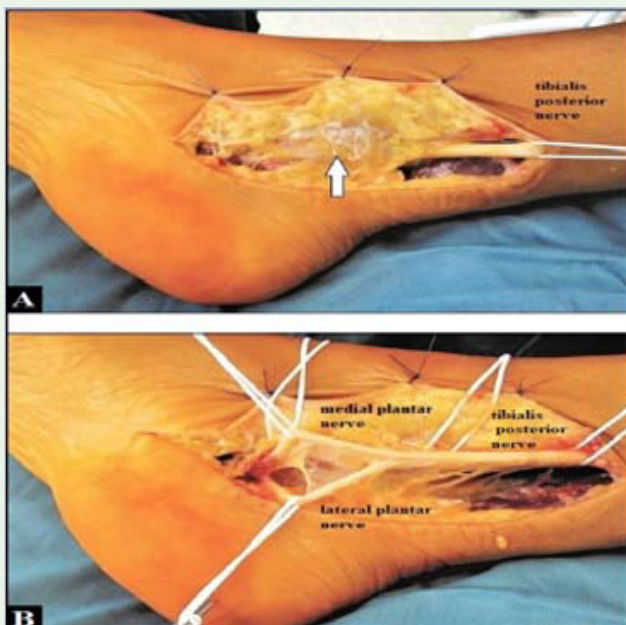


Figure 4: (29-year-old male, right ankle medial, tarsal tunnel syndrome): (A) Intraoperative, ganglion cyst led to entrapment of both plantar nerves at the bifurcation of the tibialis posterior nerve (arrow). (B) Intraoperative, after resection of ganglion cyst and decompression/neurolysis of both plantar nerves.

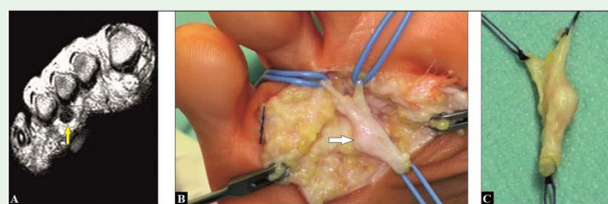


Figure 5: (53-year-old female, Morton's neuromas, left forefoot, plantar): (A) Preoperative magnetic resonance imaging showing the lesion between the metatarsophalangeal joints III and IV (arrow). (B) Intraoperative, dissection of the neuroma (arrow). (C) Intraoperative, after excision of the neuroma.

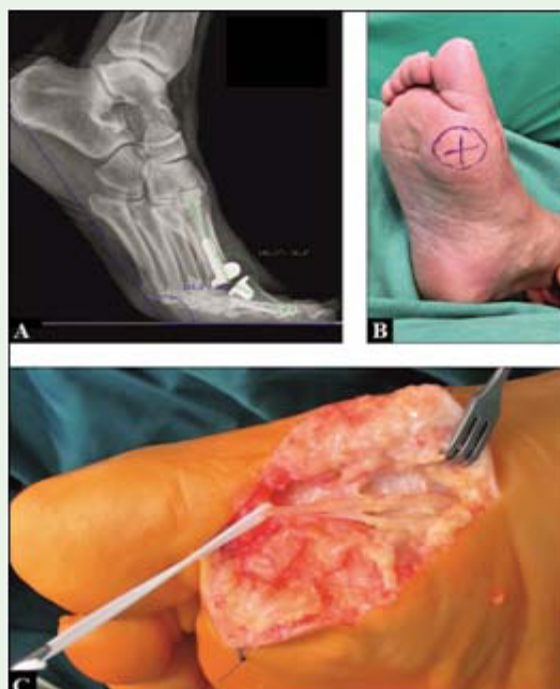

Figure 6: (59-year-old male, postoperative neuroma, right foot, plantar): (A) The patient sustained a total first metatarsophalangeal joint replacement for treatment of hallux rigidus with a good functional outcome for gait. (B) But postoperative, he reported progredient disability with loss of sensitivity of the great toe plantar-medial associated with a positive painful Hoffmann-Tinel sign (circle/cross) suggesting a partial lesion of the proper nerve branch and resulting in a neuroma that was confirmed intraoperatively. (C) Intraoperative, after interfascicular neurolysis of the proper nerve branch to the great toe. The further course was uneventful with a satisfactory pain relief and improvement of sensitivity.

Clinical presentation and diagnostic management of plantar fibromatosis

Plantar fibromatosis usually starting with 1 or more asymptomatic or painful subcutaneous nodules, most frequently at the longitudinal medial arc and/or central division of the plantar aponeurosis (Figure 1A) which can be adherent to the overlying skin and muscles, and potentially leading over time to entrapment of the proper digital nerve branch to the great toe (or others), and flexion contractures unless the slips to the toes are involved which are analogues of the palmar cords [1,29]. It can also additionally occurs in deep plantar fascia, or isolated at the distal aspect of the great toe [30,31]. Histopathological, the 1st

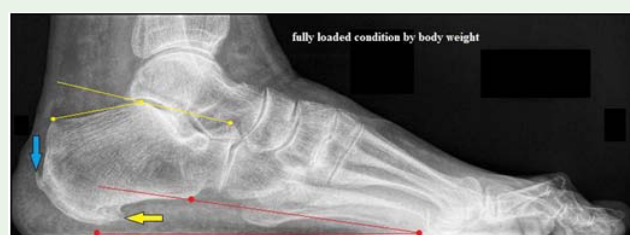

Figure 7: (69-year-old female, chronic heel and plantar foot pain, left): Typical flatfoot (i.e. pes planus) with a decreased calcaneal inclination angle to 10° (red lines and points) and a normal Böhler's angle with 25° (yellow lines and points) that means that the talocalcaneal joint is not involved in flat foot in this case. The flatfoot typically led to an overstretching-related plantar fasciitis that results in a periosteal reaction with occurrence of a plantar calcaneal spur at the origin of the plantar aponeurosis (yellow arrow). Moreover, the flatfoot is combined with a pes valgus that led to a decentralization of the achilles tendon, and resulting in a tendinitis and bursitis, and occurrence of a typical dorsal Haglund's exostosis at its insertion (light blue arrow) similar to the plantar calcaneal spur.

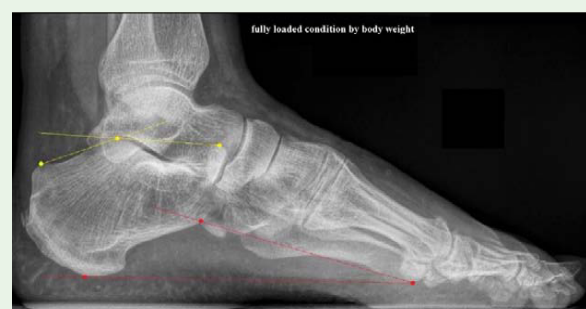

Figure 8: (43-year old male, normal sagittal static arc architecture of foot, left): Normal calcaneal inclination angle with 20 to 30° (red lines and points) that means that there is neither insufficiency of tibialis posterior tendon nor overstretching (or damage) of plantar aponeurosis, and normal Böhler's angle with 20 to 40° that means that there is neither misalignment nor instability in talonavicular joint.

stage is characterized by cellular proliferation (often associated with unspecific plantar foot pain only), the 2nd stage by nodule proliferation, and the 3rd stage by tissue contraction [32]. In order to reduce the risks of postoperative wound dehiscence and/or recurrence, an additional intraoperative staging is recommended that involves the extent of plantar fascial involvement, the presence of skin adherence, and the depth of tumor extension [32]. Plantar fibromatosis in childhood is very rare, nodules usually found in the anteromedial region of plantar aponeurosis, and unlike the adult presentation the nodules are mainly asymptomatic and not aggressive, and they have no association with palmar and penile fibromatosis [33-35].

In order to detection of nodule's infiltration into the overlying skin and into the deeper muscle layers, and especially to exclude malignancies such as the fibrosarcoma, ultrasound and/or magnetic resonance imaging (Figure 1A) should be done in every instance. With ultrasound, most of the plantar nodules are sagittally elongated, hypoechoic in the absence of intrinsic vascularity, and echogenicity does not correlate with the size of nodules and duration of symptoms [36,37]. The advantage of magnetic resonance imaging, which is

considered to be the gold standard technique for surgical planning, is that hypo- or hypercellular lesions can be assessed which are directly associated with early stages of disease or may define a more aggressive lesion [38-41]. Post-gadolinium T1 weighted magnetic resonance imaging of the nodules often showing enhancement with intravenous paramagnetic contrast fluid [2].

Treatment of plantar fibromatosis

Plantar fibromatosis can primarily treat non-surgically (stretching, orthotics, anti-inflammatory drugs, physical therapy, shockwave therapy, radiotherapy, intralesional injections of cortisone or collagenase) [12], however, there is large lack of information in the overall literature about regression vs. progression of disease over time. In the trend, intralesional cortisone injections are mostly used, radiotherapy showed good clinical outcomes but the benefits compared to the side effects are unclear, shockwave therapy reveals promising outcome in the absence of knowledge about possible complications, and intralesional collagenase injection is not already recommended recently [2].

Surgical treatment becomes necessary when in primarily non-surgically treated patients a satisfactory pain relief does not appear and the disease progresses. It includes total plantar fasciectomy

(Figure 1B-D), subtotal procedures with some inconsistencies in their methodological descriptions (marginal excision, local excision, wide local excision, staged excision, wide excision, subtotal fasciectomy, partial fasciectomy), and others such described as dermofasciectomy and surgery with or without radiotherapy; but due to the low number of patients and the heterogeneity of data of most published studies it is not possible to standardize the various procedures with its specific outcomes [2]. However, the overall recurrence rate including all procedures after first surgery is 74.3%, and 25.7% after recurrence surgery, but in trend, local excisions are associated with the highest recurrence rate and should not be recommended neither in primary nor in recurrent cases whereas procedures with wide operative margins (i.e. R0 resection) seems to be superior [2]. Noted that in recurrent cases a below-knee amputation becomes necessary as well in single cases [42]. The most important postoperative complication is delayed wound healing in up to 47.8% of cases accompanied by the necessity of additional skin grafting in 17.4% of them [35].

Problems after total plantar fasciectomy

The plantar aponeurosis (i.e. fascia) originates punctually at the plantar-medial aspect of calcaneus, then it passes the foot subcutaneously to distal creating a V-shaped divergent configuration, divides near the metatarsal heads into 5 sections, and inserts with its slips at the bases of all 5 proximal phalanges. It contributes to support of arch of the foot by acting as a tie-rod, where it undergoes tension when the foot bears weight (Figure 8). When the plantar aponeurosis was more than 50% removed, some degree of support to the foot is lost, potentially leading to increased peak pressures under the metatarsal heads which can followed by metatarsalgia, painful lateral column instability, sinus tarsiitis, medial arch pain and fatigue, collapse of the arc in the sagittal plane (flatfoot, i.e. pes planus) and subsequently followed by valgus and/or s play deformities at hind- and fore foot in frontal plane accompanied by hallux valgus and/or claw toe deformities at the forefoot in frontal plane as well (Figures 7 and 11-13), or by acquired serpentine foot (i.e. tarsus abductus/metatarsus adductus, skew foot) when the talonavicular and/or other intertalar joints become ligamentous unstable (Figure 14) with or without bone displacements or internal pressure-related skin ulceration upon the medial aspect of the head of talus (Figures 11, 13 and 14), secondary osteoarthritis in 1st metatarsophalangeal joint (Figure 11A-C), and with continued strain, stress fracture first described in Prussian soldiers in 1855 by the Prussian military physician Breithaupt may also arise particularly at the 2nd and/or 3rd metatarsal (Figure 15) [43-49]. In contrast, acquired varus deformity

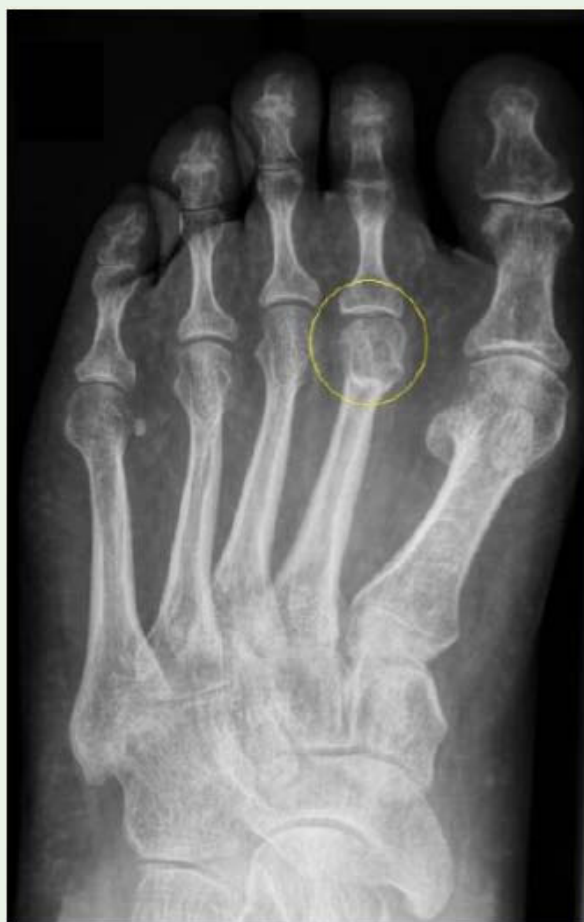

Figure 9: (36-year-old female, chronic plantar foot pain, left): Aseptic osteonecrosis of the 2nd metatarsal head (Köhler's disease II, yellow circle).

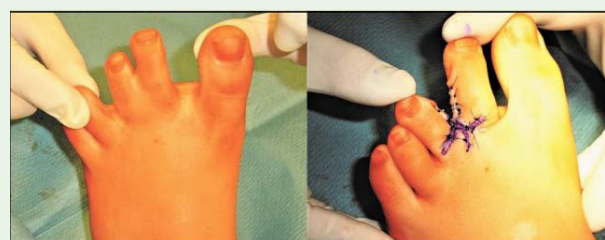

Figure 10: (16-year-old girl, chronic plantar metatarsalgia, left): Symptoms are based on hereditary syndactyly of the 2nd with the 3rd toe resulting in metatarsalgia due to impaired function in the 2nd and 3rd metatarsophalangeal joint, pre- and intraoperative after its microsurgical separation.

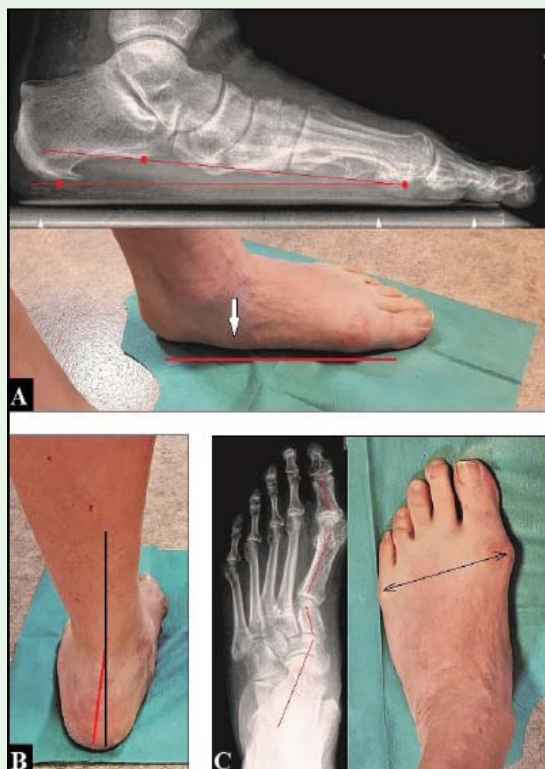

Figure 11: (67-year-old male, chronic plantar foot pain, combined deformities, left, all assessments under fully loaded conditions by body weight): (A) Severely collapsed flat foot in sagittal plane (red points and lines). Note the plantar calcaneal spur, and the prominent head of talus (white arrow). (B) Valgus deformity of the hindfoot in frontal plane (black and red lines). (C) Splay foot (black double arrow) and serpentine foot (red angled lines) in frontal plane. Note the advanced stage of secondary osteoarthritis in 1st metatarsophalangeal joint.

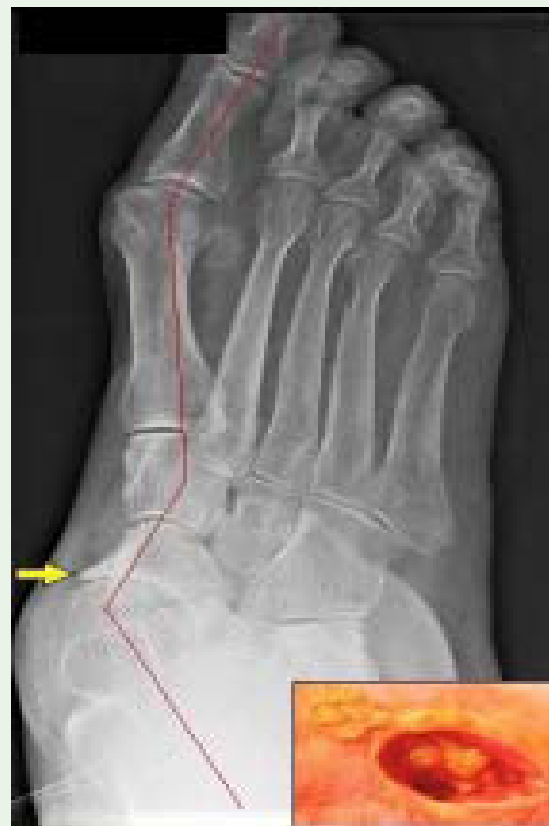

Figure 13: (63-year-old female, chronic plantar foot pain, flat foot, right): The flat foot led to a ligamentous insufficiency in talonavicular joint with its displacement (red angled lines, acquired serpentine foot), and secondarily to advanced stage of osteoarthritis (yellow arrow), and chronic hyperkeratotic skin ulceration upon the medial aspect of the head of talus.

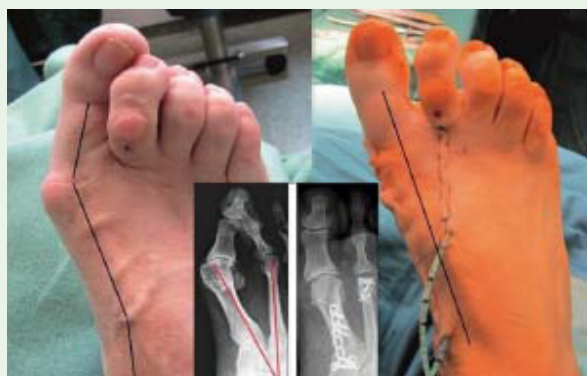

Figure 12: (57-year-old female, chronic plantar foot pain, flat foot, right): The flat foot typically led to a splay foot in frontal plane with pronounced widening of the intermetatarsal angle (red lines, normal $\leq 9^\circ$), and resulting in hallux valgus and claw toe deformities, and metatarsalgia due to displacements of the metatarsal heads II-IV plantarwards. It was surgically treated by corrective arthrodesis of the 1st tarsometatarsal joint, release of the lateral capsule of the 1st metatarsophalangeal joint, removal of medial exostosis at the 1st metatarsal head, and subcapital shortening osteotomy of the 2nd metatarsal bone. Intraoperatively, a correct alignment of the 1st ray could be achieved (3 angled black lines at the left side vs. 1 non-angled black line at the right side of Figure).

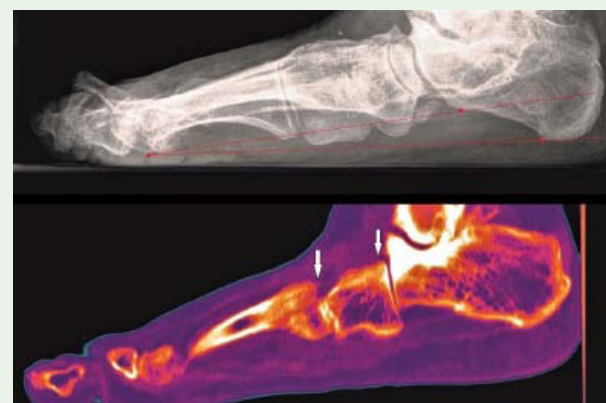

Figure 14: (73-year-old female, chronic plantar foot pain, right): Pronounced flat foot (red points and lines) subsequently leading to tarsal bone displacement plantarwards due to ligamentous insufficiencies (white arrows, computed tomography of the same patient).

of hind foot or flat foot with a decreased Böhler's angle appears to be more frequent in (post) traumatic condition (Figures 16A-C and 17A-B) [50]. It is recommended in postoperative care for the patients to use an orthotic device such as an insole with arch support (Figure

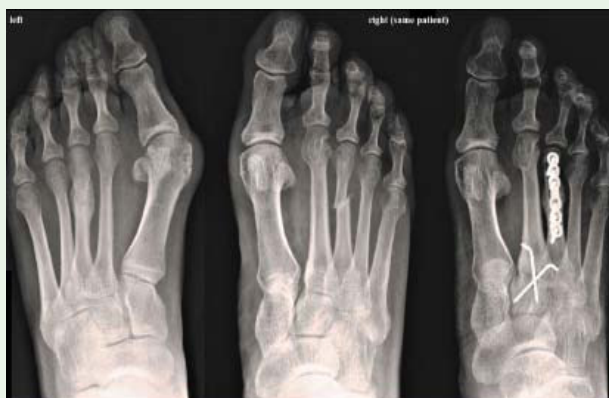

Figure 15: (59-year-old female, chronic plantar foot pain, flat and splay foot, both sides): Primarily undiagnosed stress fractures of the 3rd metatarsal bones that led to a non-union right whereas the left fracture was healed spontaneously with callus formation. The non-union right was treated by internal plate fixation without the need of additional bone grafting, and healed with callus formation as well. Note that there was an additional ligamentous instability at the 2nd tarsometatarsal joint right with displacement tendency of the 2nd metatarsal bone plantarwards (assessed intraoperatively) that was additionally treated by open reduction and Kirschner-wire transfixation.

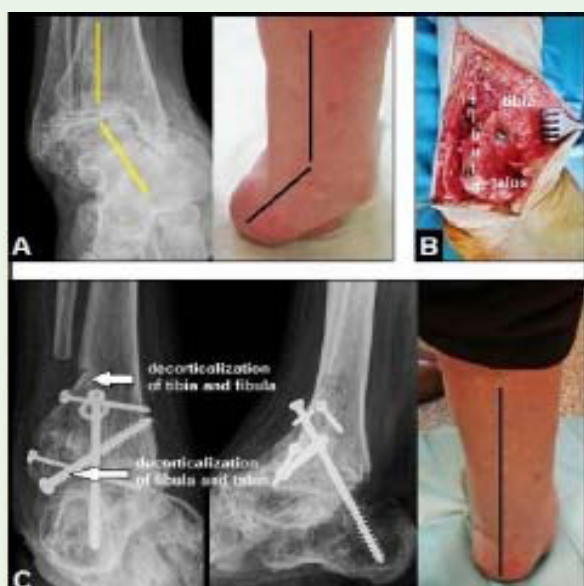

Figure 16: (68-year-old female, posttraumatic varus deformity right hind foot based on a previously sustained talus fracture that was treated conservatively [50]): (A) The talus fracture healed with misalignment that led to pronounced varus deformity of hind foot (yellow and black angled lines) accompanied by advanced posttraumatic osteoarthritis in ankle. (B) Intraoperatively, a corrective arthrodesis of the ankle was performed. (C) A satisfactory outcome with complete restoration of varus deformity could be achieved (black line).

18A-C), and the duration of its use is dependent on the patient's comfort level [1,51,52]. The second notable late complication after wide surgery can be painful plantar scarring, and difficulties with shoe wearing [12]. When bony architecture of foot is damaged, then total plantar fasciectomy should be avoided in order to obtain its sagittal arc (Figure 19A-C) [53]. Furthermore, when planning

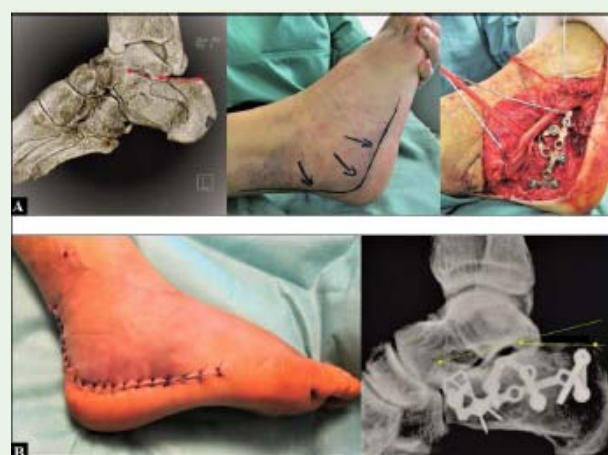

Figure 17: (54-year old male, calcaneal fracture, left): (A) Initial findings and open reduction and internal locking plate fixation, note the completely collapsed Böhler's angle in 3D computed tomography (red points and lines) that means that there is a traumatic fracture-related flat foot. (B) The Böhler's angle could be good restored (green points and lines).

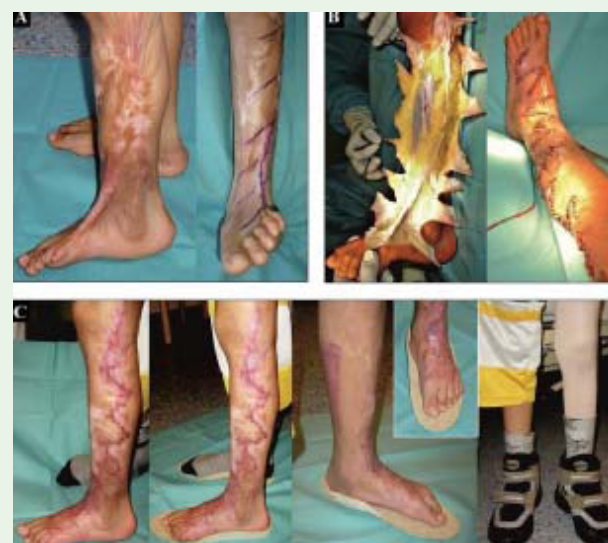

Figure 18: (8-year-old boy from Uzbekistan who sustained a burn trauma at his left lower leg and foot with age of 3 years that led to marked scar formation with talus verticalis and valgus contracture in ankle, and resulting in severely collapsed and fixed flat foot): (A) Preoperative situation with planning the large Z-plasties. (B) Intraoperative, performing the Z-plasties, lengthening procedures of the extensor tendons, and open reduction of talus verticalis with temporary Kirschner-wire transfixation. (C) Two months after surgery, uneventful wound healing, and in order to prevent recurrence of flat foot, insoles with arc support and orthopaedic shoes stabilizing the ankle were customized.

total plantar fasciectomy, pre-existent tears of tendons which play an important role for stabilizing and balancing the foot arc, such as the tibialis posterior tendon and the long peroneal tendon, should be reconstructed in every instance before performing total plantar fasciectomy (Figure 20A-C). Another main contraindication for total plantar fasciectomy is unstable soft tissue situation around the foot (Figure 21).

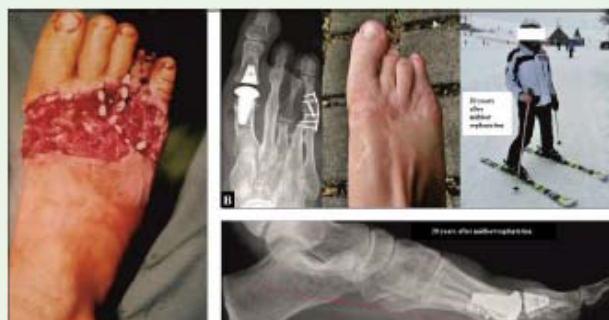

Figure 19: (28-year-old female who sustained a traumatic right midfoot amputation with age of 8 years [53]): (A) Primary midfoot replantation. (B) Despite some bony support of foot is lost, she is able to perform high-demand activities in her work and leisure. (C) There is no posttraumatic flat foot (red points and lines), however, in order to obtain the sagittal foot arc, plantar fasciectomy should be avoided.

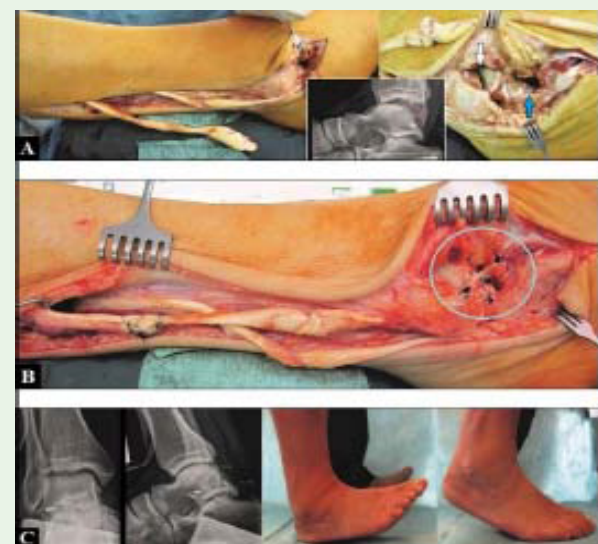


Figure 20: (73-year-old male, active runner, right chronic disruption of the long peroneal tendon accompanied by complete lateral ligamentous instability of the ankle): (A) Pre- and intraoperative, note the complete ligamentous instability both in upper and lower ankle (white and blue arrows). (B) Intraoperative, reconstruction of the long peroneal tendon and ligamentous complex in upper and lower ankle (light blue circle). (C) Six-months after surgery, a stable ankle was present, and the patient was able again to perform his runner's activities.

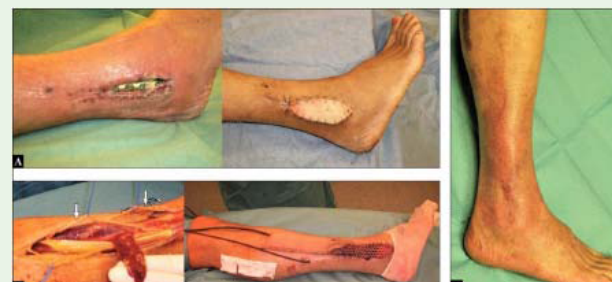

Figure 21: (57-year-old female, unstable soft tissue situation right ankle): (A) Wound dehiscence with exposure of osteosynthesis plate after open reduction of distal fibula fracture, primary treated by negative-pressure vacuum assisted closure therapy to control bacterial contamination. (B) Coverage of the exposed plate utilizing the distally pedicled peroneus brevis muscle flap and split-thickness skin grafts by preserving both peroneal nerves (white arrows). (C) Three months after coverage, uneventful wound healing.

References

- Zgonis T, Jolly GP, Polyzois V, Kanuck DM, Stamatis ED. Plantar fibromatosis. *Clin Podiatr Med Surg*. 2005; 22: 11-18.
- Fuiano M, Mosca M, Caravelli S, Massimi S, Benedetti MG, Di Caprio F, et al. Current concepts about treatment options of plantar fibromatosis: A systematic review of the literature. *Foot Ankle Surg*. 2018; pii: S1268-7731: 30230-30233.
- Ledderhose G. Ueber Zerreißen der Plantarfascie. *Langenbecks Arch KlinChir*. 1894; 48: 853-856.
- Graells Estrada J, Garcia Fernandez D, Badia Torroella F, Moreno Carazo A. Familial plantar fibromatosis. *Clin Exp Dermatol*. 2003; 28: 669-670.
- Dupuytren G. De la rétraction des doigts par suite d'une rétraction de l'aponévrose palmaire.-Description de la maladie.-Opération chirurgicale. *Compt Rendu de la Clinique Chirurgicale de l'Hôtel-Dieu par MM. les docteurs Alexandre Paillard et Marx*. J Universel Hebdomadaire Méd Chir Prat Inst Médicales. 1831; 5: 349-365.
- De le Peyronie F. Sur quelques obstacles qui s'opposent à l'éjaculation naturelle de la semence. *Mem Acad Roy Chir*. 1743, 1: 425-434.
- Chammas M, Bousquet P, Renard E, Poirier JL, Jaffiol C, Allieu Y. Dupuytren's disease, carpal tunnel syndrome, trigger finger, and diabetes mellitus. *J Hand Surg Am*. 1995; 20: 109-114.
- Bjekic M, Vlajinac HD, Sipetic SB, Marinkovic JM. Risk factors for Peyronie's disease: a case-control study. *BJU Int*. 2006; 97: 570-574.
- Biz C, Tagliavento G. Il trattamento chirurgico della malattia di Ledderhose. *LO SCALPELLO-OTODI Educ*. 2013; 27: 28-31.
- Garrod AE. Concerning Pads upon the Finger Joints and their Clinical Relationships. *Br Med J*. 1904; 2: 8.
- Tamborrini G, Gengenbacher M, Bianchi S. Knuckle pads-a rare finding. *J Ultrason*. 2012; 12: 493-498.
- Souza BG, de Souza Júnior GZ, Rodrigues RM, Dias DS, de Oliveira VM. Surgical Treatment of a Case of Ledderhose's Disease: A Safe Plantar Approach to Subtotal Fasciectomy. *Case Rep Orthop*. 2015; 2015: 509732.
- de Palma L, Santucci A, Gigante A, Di Giulio A, Carloni S. Plantar fibromatosis: an immunohistochemical and ultrastructural study. *Foot Ankle Int*. 1999; 20: 253-257.
- Alioto RJ, Rosier RN, Burton RI, Puzas JE. Comparative effects of growth factors on fibroblasts of Dupuytren's tissue and normal palmar fascia. *J Hand Surg Am*. 1994; 19: 442-452.
- Vande Berg JS, Gelberman RH, Rudolph R, Johnson D, Sicurello P. Dupuytren's disease: comparative growth dynamics and morphology between cultured myofibroblasts (nodule) and fibroblasts (cord). *J Orthop Res*. 1984; 2: 247-256.
- Badalamente MA, Sampson SP, Hurst LC, Dowd A, Miyasaka K. The role of transforming growth factor beta in Dupuytren's disease. *J Hand Surg Am*. 1996; 21: 210-215.
- Merlo G, Ambroggio GP, Mosca A, Oberto E. Possible role of plasminogen activator content of the palmar nodules in recurrence of Dupuytren's contracture. *J Hand Surg Am*. 1987; 12: 1017-1019.
- Pagnotta A, Specchia N, Greco F. Androgen receptors in Dupuytren's contracture. *J Orthop Res*. 2002; 20: 163-168.

Citation: Schmidt I. Ledderhose's Disease-What do We Know and What do We not know. *SM Musculoskelet Disord*. 2019; 4(1): 1033. <https://dx.doi.org/10.36876/smmd.1033>

19. Kosmehl H, Berndt A, Katenkamp D, Mandel U, Bohle R, Gabler U, Celeda D. Differential expression of fibronectin splice variants, oncofetal glycosylated fibronectin and laminin isoforms in nodular palmar fibromatosis. *Pathol Res Pract.* 1995; 191: 1105-1113.
20. Scholzen T, Gerdes J. The Ki-67 antigen: from the known to the unknown. *J Cell Physiol.* 2000; 182: 311-322.
21. Becker K, Tinschert S, Lienert A, Bleuler PE, Staub F, Meinel A, et al. The importance of genetic susceptibility in Dupuytren's disease. *Clin Genet.* 2015; 87: 483-487.
22. Ross DC. Epidemiology of Dupuytren's disease. *Hand Clin.* 1999; 15: 53-62.
23. International Dupuytren Society. Geographic distribution of Dupuytren's disease.
24. Hueston JT. Further studies on the incidence of Dupuytren's contracture. *Med J Aust.* 1962; 49: 586-588.
25. Ling RS. The genetic factor in Dupuytren's disease. *J Bone Joint Surg Br.* 1963; 45: 709-718.
26. Carson J, Clarke C. Dupuytren's contracture in pensioners at the Royal Hospital Chelsea. *J R Coll Physicians Lond.* 1993; 27: 25-27.
27. Robbin MR, Murphey MD, Temple HT, Kransdorf MJ, Choi JJ. Imaging of musculoskeletal fibromatosis. *Radiographics.* 2001; 21: 585-600.
28. Delgadillo LA, Arenson DJ. Plantar fibromatosis: surgical considerations with case histories. *J Foot Surg.* 1985; 24: 258-265.
29. Haedicke GJ, Sturim HS. Plantar fibromatosis: an isolated disease. *Plast Reconstr Surg.* 1989; 83: 296-300.
30. Fausto de Souza D, Micaelo L, Cuzzi T, Ramos-E-Silva M. Ledderhose disease: an unusual presentation. *J Clin Aesthet Dermatol.* 2010; 3: 45-47.
31. Reynolds JW, Bostrom CF. Plantar fibromatosis: an unusual location. *J Am Podiatry Assoc.* 1975; 65: 152-156.
32. Omor Y, Dhaene B, Grijseels S, Alard S. Ledderhose disease: Clinical, Radiological (Ultrasound and MRI), and Anatomopathological Findings. *Case Rep Orthop.* 2015; 2015: 741461.
33. Jacob CI, Kumm RC. Benign anteromedial plantar nodules of childhood: a distinct form of plantar fibromatosis. *Pediatr Dermatol.* 2000; 17: 4742-4744.
34. Pijnenburg MW, Thomasse JE, Odink RJ, Hoekstra HJ. Plantar fibromatosis in infants. *Ned Tijdschr Geneesk.* 1998; 142: 2638-2640.
35. Sammarco GJ, Mangone PG. Classification and treatment of plantar fibromatosis. *Foot Ankle Int.* 2000; 21: 563-569.
36. Bedi DG, Davidson DM. Plantar fibromatosis: most common sonographic appearance and variations. *J Clin Ultrasound.* 2001; 29: 499-505.
37. Griffith JF, Wong TY, Wong SM, Wong MW, Metreweli C. Sonography of plantar fibromatosis. *AJR Am J Roentgenol.* 2002; 179: 1167-1172.
38. Pasternack WA, Davison GA. Plantar fibromatosis: staging by magnetic resonance imaging. *J Foot Ankle Surg.* 1993; 32: 390-396.
39. Narvaez JA, Narvaez J, Ortega R, Aguilera C, Sanchez A, Andia E. Painful heel: MR imaging findings. *Radiographics.* 2000; 20: 333-352.
40. Yu JS. Pathologic and post-operative conditions of the plantar fascia: review of MR imaging appearances. *Skeletal Radiol.* 2000; 29: 491-501.
41. Recht MP, Donley BG. Magnetic resonance imaging of the foot and ankle. *J Am Acad Orthop Surg.* 2001; 9: 187-199.
42. de Bree E, Zoetmulder FA, Keus RB, Peterse HL, van Coevorden F. Incidence and treatment of recurrent plantar fibromatosis by surgery and postoperative radiotherapy. *Am J Surg.* 2004; 187: 33-38.
43. Tweed JL, Barnes MR, Allen MJ, Campbell JA. Biomechanical consequences of total plantar fasciotomy: a review of the literature. *J Am Podiatr Med Assoc.* 2009; 99: 422-430.
44. Sharkey NA, Ferris L, Donahue SW. Biomechanical consequences of plantar fascial release or rupture during gait: part I--disruptions in longitudinal arch conformation. *Foot Ankle Int.* 1998; 19: 812-820.
45. Sharkey NA, Donahue SW, Ferris L. Biomechanical consequences of plantar fascial release or rupture during gait. Part II: alterations in forefoot loading. *Foot Ankle Int.* 1999; 20: 86-96.
46. Kitaoka HB, Luo ZP, An KN. Effect on plantar fasciotomy on stability of arch of foot. *Clin Orthop Relat Res.* 1997; 344: 307-312.
47. Breithaupt MB. Zur Pathologie des menschlichen Fußes. *Med Z Berl.* 1855; 24: 169-171.
48. Wall J, Feller JF. Imaging of stress fractures in runners. *Clin Sports Med.* 2006; 25: 781-802.
49. Anderson RB, Hunt KJ, McCormick JJ. Management of common sports-related injuries about the foot and ankle. *J Am Acad Orthop Surg.* 2010; 18: 546-556.
50. Schmidt I, Schmieder A. Necessity of secondary Syme amputation of the foot after severely destroyed hind foot injury due to suicidal jump from height in a psychiatric patient: Case presentation and brief review of literature. *Trauma Emerg Care.* 2017; 2.
51. Zhai JN, Qiu YS, Wang J. Effects of orthotic insoles on adults with flexible flat foot under different walking conditions. *J Phys Ther Sci.* 2016; 28: 3078-3083.
52. Desmyttere G, Hajizadeh M, Bleau J, Begon M. Effect of foot orthosis design on lower limb joint kinematics and kinetics during walking in flexible pes planovalgus: A systematic review and meta-analysis. *Clin Biomech (Bristol, Avon).* 2018; 59: 117-129.
53. Schmidt I. A 20-year follow-up after replantation of the right mid foot in an eight-year-old child. *Int J Case Rep Images.* 2017; 8: 293-295.