



Accidental Transplantation of a Deceased Donor Kidney with a Large Calculus: Case Review and Management

Jigish B. Vyas¹, Randy K. Casals², Colin E. Kleinguetl², Bradley M. Swinson³, Christopher J. Webb¹, Alan C. Farney¹ and Robert Stratta^{1*}

¹Department of Surgery, Section of Transplantation, Atrium Health Wake Forest Baptist, USA

²Department of Urology, Atrium Health Wake Forest Baptist, USA

³Department of Radiology, Section of Interventional Radiology, Atrium Health Wake Forest Baptist, USA

Abstract

Historically, the presence of stones in a donor kidney has been a contraindication to kidney use for transplantation. However, favorable experiences transplanting living donor kidneys with isolated stones as well as successful management of de novo stone formation following living or deceased donor kidney transplantation have provided insights regarding the benefits and risks of this strategy. The limited supply of available donor kidneys has led to a reexamination of donor selection criteria to meet demand. This reevaluation is also influenced by medical advancements that have allowed for the safe management of allograft kidney stones without compromising outcomes. Herein we report the accidental transplantation of a kidney with a large pre-existing calculus from an otherwise acceptable deceased donor. Based on literature review and given the benefits of kidney transplantation versus dialysis in the setting of prolonged waiting times, expansion of the donor pool to include kidneys with large or multiple stones may be a feasible option to improve utilization and access without necessarily compromising subsequent outcomes.

Keywords: Donor-Gifted Stone; Donor Selection; Kidney Nonuse; Percutaneous Nephrolithotomy; Urolithiasis

Abbreviations: CT: Computerized Tomography; eGFR: Estimated Glomerular Filtration Rate; KDPI: Kidney Donor Profile Index.

INTRODUCTION

The critical shortage of donor organs is one of the most vexing issues in kidney transplantation today. Herein we report the accidental transplantation of a kidney with a large pre-existing calculus from an otherwise acceptable deceased donor and review the limited literature on this topic.

CASE PRESENTATION

The donor was a Caucasian male in his early forties, Kidney Donor Profile Index (KDPI) score 10%, who sustained a self-inflicted gunshot wound to the head and presented to the hospital with a severe irreversible brain injury. He was pronounced brain dead within 48 hours and multiple organ recovery was performed 72 hours later. Terminal serum creatinine level was 0.67 mg/dl with a calculated creatinine clearance of 119 ml/min. Both kidneys flushed well and appeared normal, biopsies exhibited minimal glomerulosclerosis with mild interstitial inflammation and mild

vascular changes. The left kidney was allocated high on the match run list, but the right kidney was still available at match run number 78. Although a pre-donation abdominal computed tomographic (CT) scan had demonstrated a large calculus in the right renal pelvis, this information was not included in the donor summary, nor was any history of kidney stones. The presence of the calculus was also not communicated with the kidney offer.

The recipient is a Caucasian male in his late thirties, Estimated Post-Transplant Survival score 10%, with end stage renal disease secondary to tuberous sclerosis. The recipient had been placed on our waiting list 5 months previously and had been receiving hemodialysis for 26 months. The virtual crossmatch was negative, and the transplant was initiated upon arrival of the organ to minimize cold ischemia time. During back bench ex vivo preparation of the kidney, the extrarenal pelvis was neither inspected nor palpated for the presence of a stone. The patient received a single intraoperative dose of alemtuzumab 30 mg subcutaneously for induction therapy. The dissection and kidney implantation into the right iliac fossa through an extraperitoneal approach were uneventful. The total cold ischemia time was 21.5 hours, operating time was 4 hours, and anastomosis time was 73 minutes. A double-J ureteral stent (6 x 12 cm Silicon, Boston Scientific, Marlborough, MA) and perinephric active sump drain were placed, and estimated blood loss was 200 ml. Maintenance immunosuppression consisted of tacrolimus (target 12-hour trough levels of 6-9 ng/ml initially), mycophenolic acid 720 mg twice daily, and a prednisone taper from 20 mg/d to 5 mg/d within the first month post-transplant.

The patient experienced delayed graft function and received six hemodialysis treatments in the first 18 days post-transplant; length of initial hospital stay was 4 days. Early post-transplant duplex ultrasonography (post-operative day one) revealed mild to moderate hydronephrosis with multiple renal calculi including a sizable calculus in the lower pole of the renal pelvis raising concern for obstruction despite the presence of the double-J ureteral stent. A CT scan of the abdomen

Submitted: 19 February 2025 | **Accepted:** 02 April 2026 | **Published:** 03 April 2026

***Corresponding author:** Robert Stratta, Department of Surgery, Section of Transplantation Atrium Health Wake Forest Baptist One Medical Center Blvd. Winston-Salem, NC, USA, Tel: (001) 336-716-0548. Fax: (001) 336-713-5055

Copyright: © 2026 Stratta R, et al. This is an open-access article distributed under the terms of the Creative Commons Attribution License, which permits unrestricted use, distribution, and reproduction in any medium, provided the original author and source are credited.

Citation: Vyas JB, Casals RK, Kleinguetl CE, Swinson BM, Webb CJ et al. (2026) Accidental Transplantation of a Deceased Donor Kidney with a Large Calculus: Case Review and Management. *J Nephrol Kidney Dis* 7(1): 4.



and pelvis without contrast on the following day demonstrated: 1. A large obstructing calculus resulting in moderate hydronephrosis in the lower pole; and 2. The upper pole of the transplant kidney appeared to be adequately drained by the ureteral stent (Figure 1a, coronal view; Figure 1b, axial view). Because the patient was experiencing good urine output and was immediately post-transplant, placement of a percutaneous nephrostomy tube was delayed. One month serum creatinine level was 3.16 mg/dl with an estimated glomerular filtration rate (eGFR) of 25 ml/min/1.73m². At 11 weeks post-transplant, he was re-admitted for definitive management of the large calculus.

An 8 French Flexima nephrostomy tube (Boston Scientific, Boston, MA) was placed using fluoroscopic guidance under moderate sedation and local anesthesia by the Interventional Radiology team. The following day, the patient was brought to the operating suite by Urology for percutaneous nephrolithotomy. Evaluation of the bladder and indwelling stent was performed cystoscopically with the distal curl of the ureteral stent noted to be in appropriate position within the bladder without significant encrustation. Antegrade nephrostogram was performed and demonstrated filling defects in the lower pole calyces, renal pelvis, and ureteropelvic junction, corresponding to the known large stone burden. The nephrostomy tract was dilated to 30 French, and an access sheath was placed. A 26 French nephroscope was advanced into the collecting system through the access sheath and the stones were visualized and estimated to be greater than 3 cm in total size, slightly larger than was estimated on initial imaging. A ShockPulse device (Olympus, Center Valley, PA) was used to fragment and remove the stones with residual fragments removed using the Perc NCircle Tipless Stone Extractor (Cook Medical, Bloomington, IN). A flexible ureteroscope was then advanced into the collecting system again through the access sheath. The upper pole calyces were examined,

and no stones were visualized. The ureteroscope was navigated distally into the transplant ureter and several small stones were removed using a 1.9 French Zero Tip stone retrieval basket (Boston Scientific, Boston, MA). All the stones that were retrieved were sent for compositional analysis. When there were no further stones seen, the access sheath was removed, leaving a wire in place over which a new 8 French Flexima nephrostomy tube was placed using fluoroscopic guidance, with good curl noted in the renal pelvis. The case was uncomplicated with an estimated blood loss of 150 ml, which the patient tolerated well.

The urethral catheter was removed on post-operative day one, repeat duplex ultrasonography revealed no evidence for residual stones or obstruction, and the patient was able to void appropriately prior to discharge. Cystoscopy with ureteral stent and nephrostomy tube removal was performed one week later in clinic. The stone composition was 100% calcium oxalate monohydrate. At three months post-transplant, serum creatinine levels were in the 1.9-2.1 mg/dl range with eGFR levels ranging from 41-47ml/min/1.73m². Despite multiple interventions involving the urinary tract, the patient has not had any urinary tract infection to date.

DISCUSSION

Previously, the acceptance of deceased donor kidneys with stones was a relative if not absolute contraindication to kidney transplantation [1,2]. However, favorable experience with transplanting living donor kidneys with isolated stones as well as successful management of de novo stone formation following living or deceased donor kidney transplantation have provided insights regarding the benefits and risks of this strategy [3-9]. The limited supply of available donor kidneys has led to a reexamination

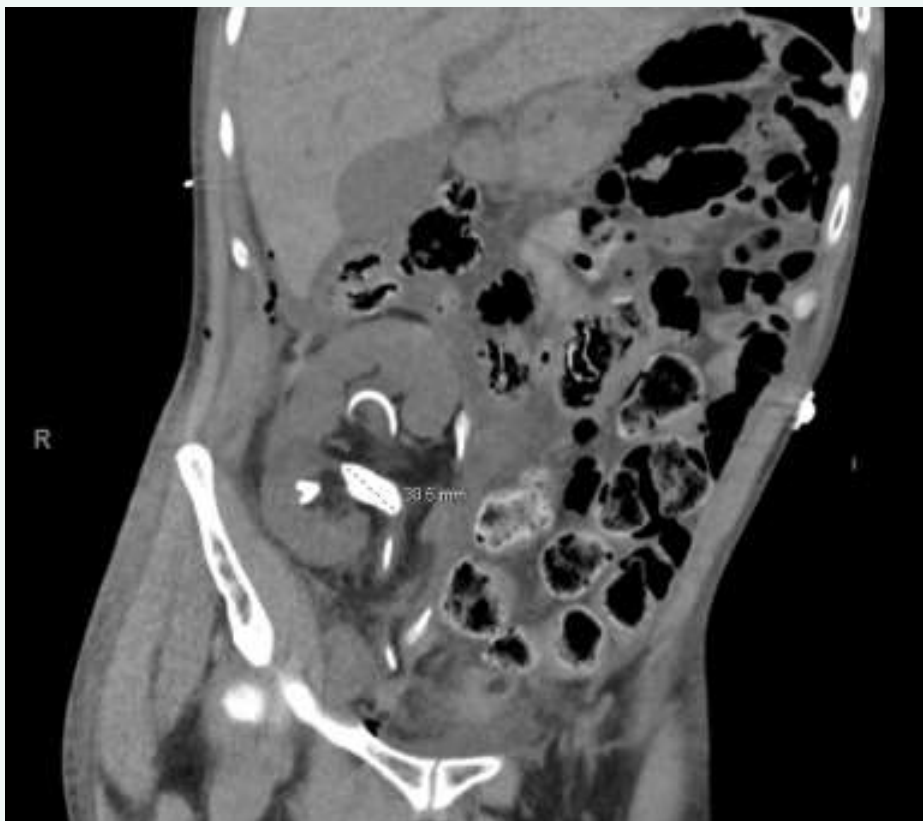

Figure 1a: CT scan coronal view post kidney transplant depicting a large donor-gifted calculus with moderate lower calyceal hydronephrosis and adequate drainage of upper pole by double-J ureteral stent

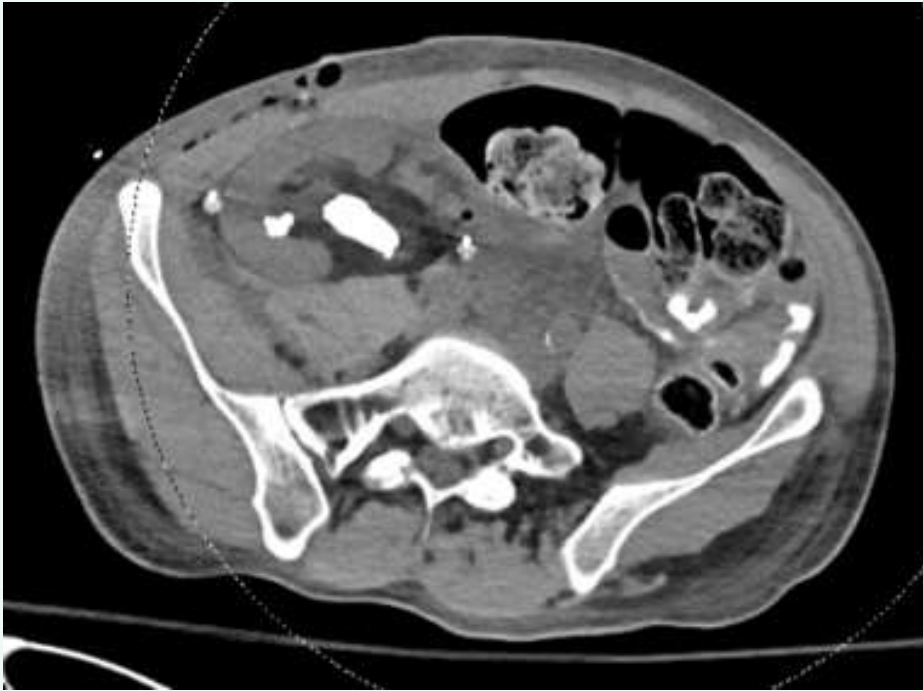


Figure 1b: CT scan axial view depicting a large donor-gifted calculus.

of donor selection criteria to meet demand. This reevaluation is also influenced by medical advancements that have allowed for the safe management of allograft kidney stones without compromising outcomes.

Urinary stones in the transplanted kidney are an extremely uncommon complication (ranging from 0.2-1.7% of cases) [3-8]. Presentation may be different from non-transplant scenarios because of allograft denervation, with most found incidentally on imaging. Urolithiasis in an allograft may impose the threat of short-term complications such as obstruction, anuria, acute kidney injury, need for urgent dialysis, and urinary tract infections. Long-term complications may include pyelonephritis and deterioration of graft function. Risk factors for urinary stones are hyperparathyroidism, chronic obstruction (ureteral or bladder), retained foreign body (suture, stent), or donor-gifted stone [10-12].

Intentional transplantation of a deceased donor kidney with a large calculus has been rarely reported [13-15]. At present, in the United States, most deceased donors have an abdominal and pelvic CT scan (with or without contrast) as part of the standard donor work-up. This case illustrates the importance of having the individual responsible for accepting the kidney offer on behalf of the transplant center review primary data in DonorNet to avoid any miscommunications or surprises. Evaluation of the CT scan can provide information pursuant to kidney size and morphology, parenchymal lesions, cortical atrophy, presence of stones with number/location/dimensions, and renovascular calcifications. Although the donor in this case would be considered high quality (KDPI 10%), it is interesting to speculate whether any center would have accepted this kidney with a known large calculus causing a partial urinary obstruction. In retrospect, we unintentionally accepted this kidney without knowledge of the large renal calculus.

Management of urinary stones in the transplanted kidney can become a complicated issue secondary to atypical presentation due to a denervated graft, the immunosuppressed status of the recipient, altered calyceal position for access, and in some cases borderline renal function. Risks

of bleeding and infection are feared complications. Any stone that is more than 4-6 mm in size in an allograft should be addressed because of the potential to cause complete urinary obstruction and anuria. The most common site of blockage is the ureterovesical junction. Treatment options include ureteroscopy, percutaneous nephrolithotomy, and/or extracorporeal shock wave lithotripsy [3-20]. In cases of anuria secondary to a completely obstructed ureter, initial percutaneous nephrostomy, or placement of a double J stent by cystoscopy may be required before definitive management is undertaken.

This case illustrates the extremes that sometimes are necessary to salvage a less-than-ideal donor kidney and raises the question as to whether presence of a large calculus in a deceased donor kidney should remain an absolute contraindication to kidney utilization. We have recently transplanted another donor kidney with a large missed nonobstructing calculus and plan to have the stone removed by percutaneous nephrolithotomy at 3 months post-transplant. Ideally, the treatment of choice for this condition is back bench pyelolithotomy and stone extraction. Alternatively, for smaller stones, ex vivo ureteroscopy with stone removal can be performed during back bench preparation of the kidney. This case highlights the importance of critically reviewing all donor information including direct inspection of any available imaging prior to organ acceptance and recipient selection. Given the benefits of kidney transplantation versus dialysis in the setting of prolonged waiting times, expansion of the donor pool to include kidneys with large or multiple stones may be an option to improve utilization and access without necessarily compromising subsequent outcomes.

AUTHOR CONTRIBUTIONS

Concept/design: JBV, RKC, RS

Data analysis/interpretation/collection: JBV, RKC, CEK, BMS, CW, ACF, RS

Drafting article: JBV, RKC, RS



Critical revision and approval of article: JBV, RKC, CEK, BMS, CW, ACF, RS

CONFLICT OF INTERESTS/DISCLOSURE

The authors do not have any conflicts of interest to disclose pursuant to this study. This study was approved by the Atrium Health Wake Forest Baptist Institutional Review Board under the auspices of the Cortex Study, Protocol Number 00084139.

DATA AVAILABILITY STATEMENT

Data available upon request from the authors.

REFERENCES

1. Mandelbrot DA, Pavlakis M, Danovitch GM, Johnson SR, Karp SJ, Khwaja K. The medical evaluation of living kidney donors: a survey of US transplant centers. *Am J Transplant.* 2007; 7: 2333-2343.
2. Tatapudi VS, Goldfarb DS. Differences in national and international guidelines regarding use of kidney stone formers as living kidney donors. *Curr Opin Nephrol Hypertens.* 2019; 28: 140-147.
3. Klingler HC, Kramer G, Lodde M, Marberger M. Urolithiasis in allograft kidneys. *Urology.* 2002; 59: 344-348.
4. Ferreira Cassini M, Cologna AJ, Ferreira Andrade M, Lima GJ, Medeiros Albuquerque U, Pereira Martins AC et al. Lithiasis in 1,313 kidney transplants: incidence, diagnosis, and management. *Transplant Proc.* 2012; 44: 2373-2375.
5. Kim IK, Tan JC, Lapasia J, Elihu A, Busque S, Melcher ML. Incidental kidney stones: a single center experience with kidney donor selection. *Clin Transplant.* 2012; 26: 558-563.
6. Stravodimos KG, Adamis S, Tyrantzis S, Georgios Z, Constantinides CA. Renal transplant lithiasis: analysis of our series and review of the literature. *J Endourol.* 2012; 26: 38-44.
7. Mamarelis G, Vernadakis S, Moris D, Altanis N, Perdikouli M, Stravodimos K, et al. Lithiasis of the renal allograft, a rare urological complication following renal transplantation: a single-center experience of 2,045 renal transplantations. *Transplant Proc.* 2014; 46: 3203-3205.
8. Cheungpasitporn W, Thongprayoon C, Mao MA, Kittanamongkolchai W, Jaffer Sathick IJ, Dhondup T, et al. Incidence of kidney stones in kidney transplant recipients: A systematic review and meta-analysis. *World J Transplant.* 2016; 6: 790-797.
9. Yin S, Zhou Z, Zhang F, Wu J, Lin T, Wang X. Treatment of donors' asymptomatic small kidney stones and post-transplant outcomes: a meta-analysis. *Urolithiasis.* 2023; 51: 104.
10. Lu HF, Shekarriz B, Stoller ML. Donor-gifted allograft urolithiasis: early percutaneous management. *Urology.* 2002; 59: 25-27.
11. Jan MY, Sharfuddin A, Mujtaba M, Adebisi O, Sundaram CP, Yaqub M, et al. Living Donor Gifted Lithiasis: Long-Term Outcomes in Recipients. *Transplant Proc.* 2021; 53: 1091-1094.
12. Sierra A, Castillo C, Carbonell E, Muní M, Martínez C, López JM, et al. Living donor-gifted allograft lithiasis: surgical experience after bench surgery stone removal and follow-up. *Urolithiasis.* 2023; 51: 91.
13. Rodriguez MV, Herrera O, Friedman B, Moya M, Olgin G. Donor-gifted allograft staghorn calculus managed via percutaneous nephrolithotomy. *Videourology.* 2023; 37: 1.
14. Jin Z, Lai J, Zhang J. A case of a transplanted kidney with an orthotopic kidney stone. *J Surg Case Rep.* 2024; 2024: rjae445.
15. Chen CB, Zhao L, Han M, Wang XP, Zhou J, Yuan XP, et al. Renal Transplantation Using Stone-bearing Deceased Donor Kidneys-Experience of a Transplant Center in China. *Urology.* 2017; 107: 251-256.
16. Ganpule A, Vyas JB, Sheladia C, Mishra S, Ganpule SA, Sabnis RB, Desai M. Management of urolithiasis in live-related kidney donors. *J Endourol.* 2013; 27: 245-250.
17. Bhadauria RP, Ahlawat R, Kumar RV, Srinadh ES, Banerjee GK, Bhandari M. Donor-gifted allograft lithiasis: extracorporeal shockwave lithotripsy with over table module using the Lithostar Plus. *Urol Int.* 1995; 55: 51-55.
18. Rifaioğlu MM, Berger AD, Pengune W, Stoller ML. Percutaneous management of stones in transplanted kidneys. *Urology.* 2008; 72: 508-512.
19. Oliveira M, Branco F, Martins L, Lima E. Percutaneous nephrolithotomy in renal transplants: a safe approach with a high stone-free rate. *Int Urol Nephrol.* 2011; 43: 329-335.
20. Cerrato C, Jahrreiss V, Nedbal C, Ripa F, De Marco V, Monga M, et al. Shockwave Lithotripsy for De-Novo Urolithiasis after Kidney Transplantation: A Systematic Review of the Literature. *J Clin Med.* 2023; 12: 4389.