



Pure Red Cell Aplasia: Where the Guidelines End

Marie Dirix^{1*}, Nikki Granacher², Eric Gheuens³, and Wendy Engelen³

¹Department of Nephrology, University hospital Antwerp, Belgium

²Department of Haematology, ZNA Antwerp, Belgium

³Department of Nephrology, ZNA Antwerp, Belgium

Abstract

Anaemia after renal transplant occurs frequently and is often found to be multifactorial. After excluding vitamin deficiencies and inadequate treatment with erythropoietin, PRCA (pure red cell aplasia) should be ruled out. PRCA can be caused by various medications (e.g. antibiotics) or can be associated with parvovirus B19 infection or reactivation in immunosuppressed patients. Parvovirus B19-associated PRCA is rare after renal transplantation but is believed to be underdiagnosed. Treatment consists of transfusion, reduction of immunosuppression and administration of intravenous immunoglobulin (IVIG). Patients should be closely monitored, as relapse is common.

We present a case of a young woman with PRCA due to parvovirus B19 infection two years after renal transplantation. She was successfully treated with IVIG but suffered two relapses despite a significant reduction in immunosuppression. Both relapses occurred after an attempt to stop or reduce the IVIG treatment. It is unclear when and how to stop chronic IVIG treatment in relapsing PRCA.

Keywords: Pure red cell aplasia; Human parvovirus B19; Kidney transplantation

Introduction

Anaemia is a frequent finding in renal transplant patients and is often multifactorial [1]. We present the case of a young renal transplant patient with an acute and severe erythropoietin-resistant anaemia that was caused by primary infection with human parvovirus B19. In immunosuppressed patients, parvovirus B19 infection can lead to a chronic pure red-cell aplasia (PRCA). Treatment consists of reducing immunosuppression and intravenous immunoglobulin (IVIG). Relapse remains common and in severe cases, like the case presented here, maintenance IVIG treatment is needed. When or how to stop this maintenance treatment is not known. We performed several attempts to withdraw the IVIG treatment, but they were all unsuccessful. Due to the rarity of this disease, there is no evidence-based guidance on how to treat these patients. International cooperation and pooling of available data is urgently needed to expand our knowledge on this disease and its optimal treatment.

Case Report

Case description

A 38-year old woman was referred to the haematology department because of progressive anaemia. She was of North-

African descent and her prior medical history consisted of hypertension, hypothyroidism, peptic ulcer disease and end-stage renal disease due to renal tuberculosis. She was treated with peritoneal dialysis for three years and haemodialysis for another two years after which she received a renal transplant from a deceased donor in December 2016. Her maintenance immunosuppressive regimen included 25 mg tacrolimus, 5 mg prednisolone and 2000 mg mycophenolate mofetil (MMF) daily. She was also treated with recombinant human erythropoietin (rhEpo), pantoprazole, levothyroxine and vitamin D supplements. She had a stable kidney function with a serum creatinine of 2.3 mg/dl corresponding with an eGFR of 26 ml/min/1.73 m² using the CKD-EPI equation.

The patient had been in her usual state of health until four weeks prior to admission, when profound fatigue, chest pain and dyspnoea upon mild exertion (NYHA class 3) developed. She reported no fever or diaphoresis and did not have any other physical complaints. On examination she had a mildly elevated body temperature of 37.4°C but otherwise normal vital signs. There was a noticeable pallor. Examination of heart, lungs and abdomen was normal. There was no peripheral oedema and no cutaneous abnormalities or enlarged lymph nodes. The haemoglobin level was 5.5 g/dL (reference range, 11 to 14.4 g/dL). Eight weeks earlier the level had been 11.5 g/dL. She was admitted to the haematology department and treated with packed red blood cell transfusions.

Additional tests revealed profound normocytic normochromic anaemia with severe reticulocytopenia (Table 1). The white blood cell count was mildly reduced. Differentiation showed a mild lymphopenia. The platelet count was normal. There were no arguments for either intra- or extravascular haemolysis. Iron stores were adequate and levels of folic acid and vitamin B12 were within normal range. There was no history of recent blood loss and a gastroscopy was normal. The patient reported to adhere to her treatment regimen including the rh-Epo injections, which was confirmed by a normal endogenous erythropoietin level. Through levels for tacrolimus were non-toxic. Serum creatinine

Submitted: 06 January 2020 | **Accepted:** 05 February, 2020 | **Published:** 07 February, 2020

***Corresponding author:** Marie Dirix, Department of Nephrology UZA, Wilrijksstraat 10, 2650 Edegem, Belgium, Tel: 32 -48524-2568; Email: marie.dirix@hotmail.com

Copyright: © 2020 Dirix M, et al. This is an open-access article distributed under the terms of the Creative Commons Attribution License, which permits unrestricted use, distribution, and reproduction in any medium, provided the original author and source are credited.

Citation: Dirix M, Granacher N, Gheuens E, Engelen W (2020) Pure Red Cell Aplasia: Where the Guidelines End. J Nephrol Kidney Dis 4: 5. doi: <https://dx.doi.org/10.36876/smjnk950816>



Table 1: Laboratory evaluation on admission.

Analysis	Unit	Value	Reference values
Haematology			
Haemoglobin	g/dl	5,5 --	11,0-14,4
Haematocrit	l/l	0,16 --	0,350-0,410
Reticulocytes	/1000 RBC	0,8 --	4,40-15,50
Reticulocytes (absolute count)	10 ⁹ /l	1,6 --	16-66
Leucocytes	10 ⁹ /l	2,59 -	3,45-9,76
Platelets	10 ⁹ /l	184	142-340
Direct Antiglobulin test IgG		Negative	
Direct Antiglobulin test C3-d		Negative	
Biochemistry			
Creatinine	mg/dl	2,30 +	0,52-1,04
eGFR (CKD-EPI equation)	ml/min/1,73m ²	26,0 -	90,0-120,0
C-reactive protein	mg/l	11,0	<10,0
Serum protein electrophoresis		Normal	
Albumin	g/l	38,2	35-50,0
Bilirubin	mg/dl	0,7	0,2-1,3
LDH	U/l	642 +	313-618
Tacrolimus through level	µg/l	5,7	5-20
Haptoglobin	g/l	1,29	0,26-1,85
Folic Acid	ng/ml	6,9	3,9-26,8
Vitamin B12	ng/l	336	197-771
Transferrin saturation	%	91,6 +	15-50
Ferritin	µg/l	418 +	6-137
Erythropoietin	UI/l	399,5	98-620 for Hct of 20%
Thyroid Stimulating Hormone	mU/l	<0,02 -	0,30-3,90
FT4	pmol/l	31,0 +	10,0-28,2
β-HCG	U/l	<2,4	
Serology			
EBV anti-VCA IgG		Positive	
EBV IgM EIA		Negative	
CMV IgG EIA		Positive	
CMV IgM EIA		Positive	High avidity of IgG-antibodies suggesting infection of more than 3 months old.
HIV 1 + 2		Negative	
Parvovirus B19 IgG		Negative	
Parvovirus B19 IgM		Negative	
Microbiology			
PCR Human herpes virus 6		Negative	
PCR EBV		Negative	
PCR CMV		Negative	
PCR Parvovirus B19		Positive. Threshold cycle: 15	

was unchanged and liver function tests were normal. Pregnancy was excluded and thyroid levels showed an over-substitution of levothyroxine (Table 1).

Further diagnostic work-up consisted of additional blood tests and a bone marrow examination. Results are shown in Table 1. The bone marrow biopsy showed a normal cellularity and maturation of the myeloid and megakaryocyte lineage. Erythroblasts were strikingly scarce. This pattern confirmed the diagnosis of pure red cell aplasia (PRCA). Several abnormal erythroid cells were seen with a fine granular eosinophilic

cytoplasm and a large nucleus containing eosinophilic viral inclusions that were surrounded by a clear halo (Figure 1). These giant pronormoblasts are pathognomonic for parvovirus B19 infection [2].

Viral assays on peripheral blood were also performed. Quantitative polymerase chain reaction (PCR) amplification testing revealed a high viral load of parvovirus B19 DNA with a threshold cycle (Ct) of 15. Ct-values below 29 indicate a strong positive reaction because of abundant DNA in the tested serum sample (Figure 1).

The patient was treated with blood transfusions and intravenous immunoglobulin (IVIG) at a total dose of 100 g (= 2g/kg) administered over three consecutive days. This resulted in a prompt increase of the reticulocyte count and a subsequent rise in haematocrit. The MMF was temporarily paused but was later re-administered at a reduced dose. Relapse was diagnosed three months later, upon which a second course of IVIG was administered. Because of the early relapse despite reducing the dose of MMF and a much higher viral load than at diagnosis, maintenance IVIG therapy was started at a dose of 0.4g/kg/day every 4 weeks and therapy with MMF was stopped. Laboratory results showed a subsequent stabilisation of the haemoglobin but persistently low Ct values indicating a high concentration of viral DNA (Figure 2).

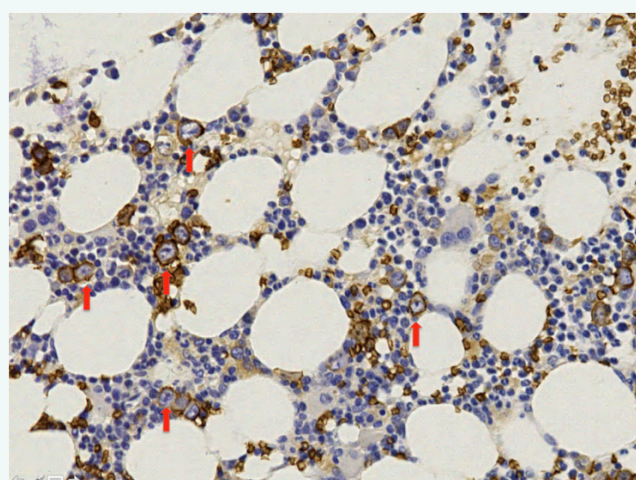


Figure 1 Bone marrow biopsy section. Glycophorin C staining revealed decreased erythroid precursor cells. Arrows point out the giant pronormoblasts.

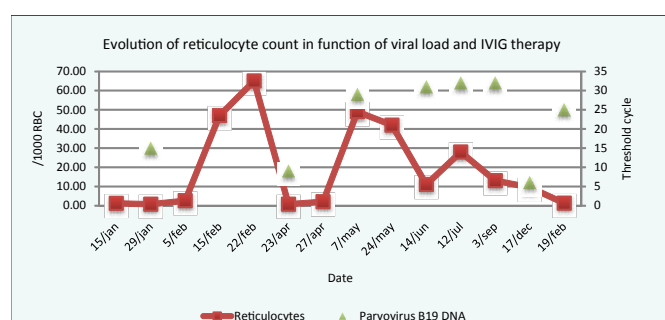


Figure 2 Evolution of haemoglobin, relative reticulocyte count and parvovirus viral load.

Viral load is expressed as the PCR threshold cycle Ct, which is inversely proportional to the amount of viral DNA copies in serum. IVIG therapy was started on the sixth of February. The second dose of IVIG was administered during 24 to 27 April. Because of the fast relapse despite reducing the dose of MMF, monthly IVIG therapy was started and therapy with MMF was definitely stopped. Subsequent doses of IVIG were administered

every month until 17 December, when the interval was prolonged to eight weeks. This immediately led to a second relapse.

After nine months of stable haemoglobin values and systematically decreasing viral load assays, the IVIG interval was gradually extended to eight weeks. The patient soon developed a second relapse. Further reduction in immune suppression was not possible and IVIG therapy was re-administered and again continued at monthly intervals. How and when IVIG therapy should ideally be discontinued, is not known. We will attempt a new reduction in the frequency of IVIG treatment once the viral load has substantially decreased.

Discussion

We present an elaborate case history of a patient presenting with a clinically symptomatic relapsing parvovirus B19 infection. The presenting sign was severe anaemia. Anaemia is a frequent finding after renal transplantation with a reported incidence of 30 to 38.6% [1,3]. The most common cause is thought to be erythropoietin deficiency from poor endocrine allograft function and several risk factors have been identified [1]. As in the case of our patient, the finding of reticulocytopenia without vitamin deficiencies and despite adequate erythropoietin treatment should prompt a bone marrow examination to rule out PRCA.

Pure red cell aplasia (PRCA) comprises hypoproliferative anaemia arising from the lack of red blood cell precursors in the bone marrow. Acquired PRCA can be primary or secondary. Primary acquired PRCA is characterized by an autoimmune destruction of the red blood cell precursors and is usually antibody-mediated. Secondary PRCA can be associated with underlying autoimmune diseases, certain infections, pregnancy, haematological malignancies, solid tumours and a number of drugs and toxic substances [4]. Patients usually present with a normocytic normochromic anaemia and an absolute reticulocyte count below 10.000/ μ L. The diagnosis is confirmed by normal cellularity and maturation of the myeloid and megakaryocyte lineage on bone marrow aspirate but an absence or near absence of erythroblasts. In parvovirus B19 infection giant pronormoblasts can be present. These are early red-cell progenitor cells in which the virus is actively replicating.

In our patient PRCA was secondary to primary infection with human parvovirus B19. Parvovirus B19 belongs to the *parvoviridae*, a family of small DNA viruses. It is usually transmitted via respiratory droplets but can also be transmitted through infected blood products. It is ubiquitous and infection is most common in childhood [5]. After entering the respiratory tract and replicating in the nasopharyngeal lymphatic tissue, the virions enter the bloodstream and infect erythroid progenitor cells. Viral replication in these cells leads to cell lysis and the resulting viremia causes fever, malaise and myalgia. Infection and replication in the red cell precursors leads to a drop in circulating reticulocytes, which lasts two to five days in patients with a normal immune system. In healthy adult individuals most cases of parvovirus B19 infection are asymptomatic and the short and mild drop in haematocrit is usually not clinically significant. Patients with chronic haemolytic anaemia however, who rely



on a chronic reticulocytosis to compensate for the increased haemolysis, develop a transient aplastic crisis after infection with parvovirus B19. Immune compromised patients develop a chronic or relapsing pure red cell aplasia due to the inability to mount a sufficient immune response and the subsequent persistent viral replication. Immune-mediated symptoms are not present until neutralising antibodies are formed or passively administered. This B19-associated PRCA is described not only in hematopoietic stem cell and solid organ transplant recipients [6-8], but also in oncologic and hematologic malignancies treated with immunosuppressive chemotherapy or rituximab [9,10], acquired immune deficiency syndrome (AIDS) and congenital immunodeficiency [11]. After establishing the diagnosis of PRCA, detection of B19 DNA in serum is the diagnostic test of choice. Treatment recommendations consist of immediate transfusion when needed, intravenous immunoglobulin therapy and a reduction or interruption of immune suppression whenever possible. IVIG therapy should be started without delay as it contains antibodies against parvovirus B19 and leads to a rapid decline in serum viral DNA. The optimal dose is unclear but the usual recommended dose is 2 g/kg divided over five consecutive days (400 mg/kg/d) [4]. It is advised to perform a baseline viral load assay following response to treatment. Patients should be closely monitored as relapse is common once passive immunity wanes and the host's defence has not significantly improved [12]. When the haematocrit starts to fall, a new viral load assay should be performed to confirm the increased parvovirus viremia and a second course of IVIG should be administered. In rare cases monthly maintenance therapy with IVIG is needed [11].

The true incidence of clinically significant parvovirus B19 infection in renal transplant patients is not entirely clear but is reported to be as high as 23% to 38% in patients with persistent anaemia [13,14]. Analysis of the available case reports and series by Eid et al showed a median onset of clinically significant parvovirus B19 infection 1.75 months after transplantation with a broad range of 1 week to 96 months. Anaemia was the most common clinical manifestation (98.8%) but leukopenia and thrombocytopenia were also observed in 37.5 and 21.0 % of patients. Organ-specific syndromes were present in 11% of patients, being myocarditis, hepatitis, pneumonitis, collapsing glomerulopathy and thrombotic microangiopathy. Allograft loss, rejection or dysfunction was seen in 10.4% of patients [8].

Data about recurrence rate and prognosis are scarce. In the previously mentioned study of Eid et al. there was a recurrence rate of 34% in the 53 renal transplant patients [8]. In 2012 Beckhoff et al. conducted a Medline search and identified 49 renal transplant patients with parvovirus B19-associated anaemia. They observed a similar relapse rate of 33% and relapse was more common in primary infection and patients who had received anti-thymocyte globulin [15]. Parvovirus B19-associated PRCA can be a true chronic disease with up to nine described recurrences over a four-year period [16].

The optimal treatment of this chronic parvovirus B19-associated PRCA is not known. It is unclear when to consider secondary prophylaxis with maintenance IVIG therapy, nor the optimal dosage or timing. When and how to subsequently stop or reduce this therapy, is even more unclear. Due to the very low

incidence of this disease, prospective data that could answer these questions are missing and almost impossible to acquire. International cooperation and pooling of available retrospective data is needed to expand our knowledge on this disease and its optimal treatment.

Conclusion

Anaemia is frequent after renal transplantation. We present the case of a young patient with a functioning kidney allograft, who developed an acute and severe erythropoietin-resistant anaemia. The diagnosis of pure red cell aplasia (PRCA) due to chronic parvovirus B19 infection was made based on the detection of viral DNA in peripheral blood and typical changes on bone marrow analysis.

Clinically significant parvovirus B19 infection and the associated PCRCA are generally considered a rare disease in the post-transplant period. The reported incidence is highly variable. Based on recent data suggesting higher incidence rates, it can be presumed to be under-diagnosed and treating physicians should have a high index of suspicion in acute or severe erythropoietin-resistant anaemia in the post-transplant period.

Treatment consists of transfusion, reduction of immunosuppression and administration of intravenous immunoglobulin (IVIG). Patients should be closely monitored, as relapse is common. If the reticulocyte count or the haemoglobin level starts to fall, a new viral load assay should be performed and patients should receive a second dose of IVIG and if possible, further reduction of immunosuppression.

Relapse of parvovirus B19-associated PRCA occurs in about one third of renal transplant patients. Our patient experienced two recurrences despite a significant reduction of immunosuppression. The optimal treatment of this chronic parvovirus B19-associated PRCA is not known. When and how prophylactic IVIG therapy should be initiated and discontinued, is unclear. More data are urgently needed.

References

1. Vanrenterghem Y. Anaemia after renal transplantation. *Nephrol Dial Transplant*. 2004; 19: 54-58.
2. Young NS, Brown KE. Parvovirus B19. *N Engl J Med*. 2004; 350: 586-597.
3. Yorgin PD, Scandling JD, Belson A, Sanchez J, Alexander SR, Andreoni KA. Late post-transplant anemia in adult renal transplant recipients. An under-recognized problem? *Am J Transplant*. 2002; 2: 429-435.
4. Means RT Jr. Pure red cell aplasia. *Blood*. 2016; 128: 2504-2509.
5. Centers for Disease C. Risks associated with human parvovirus B19 infection. *MMWR Morb Mortal Wkly Rep*. 1989; 38: 93-97.
6. Plentz A, Hahn J, Holler E, Jilg W, Modrow S. Long-term parvovirus B19 viraemia associated with pure red cell aplasia after allogeneic bone marrow transplantation. *J Clin Virol*. 2004; 31: 16-19.
7. Karrasch M, Schmidt V, Hammer A, Hochhaus A, Rosée P, Petersen I, et al. Chronic persistent parvovirus B19 bone marrow infection resulting in transfusion-dependent pure red cell aplasia in multiple myeloma after allogeneic haematopoietic stem cell transplantation and severe graft versus host disease. *Hematology*. 2017; 22: 93-98.



8. Eid AJ, Robert A. Brown, Robin Patel, Raymund R. Razonable. Parvovirus B19 infection after transplantation: a review of 98 cases. *Clin Infect Dis*. 2006; 43: 40-48.
9. Isobe Y, Sugimoto K, Shiraki Y, Nishitani M, Koike K, Oshimi K. Successful high-titer immunoglobulin therapy for persistent parvovirus B19 infection in a lymphoma patient treated with rituximab-combined chemotherapy. *Am J Hematol*. 2004; 77: 370-373.
10. Kuo SH, Lin LI, Chang CJ, Liu YR, Lin KS, Cheng AL. Increased risk of parvovirus B19 infection in young adult cancer patients receiving multiple courses of chemotherapy. *J Clin Microbiol*. 2002; 40: 3909-3912.
11. Landry ML. Parvovirus B19. *Microbiol Spectr*. 2016; 4.
12. Crabol Y, Terrier B, Rozenberg F, Pestre V, Legendre C, Hermine O, et al. Intravenous immunoglobulin therapy for pure red cell aplasia related to human parvovirus b19 infection: a retrospective study of 10 patients and review of the literature. *Clin Infect Dis*. 2013; 56: 968-977.
13. Egbuna O, Zand MS, Arhini A, Menegus M, Taylor J. A cluster of parvovirus B19 infections in renal transplant recipients: a prospective case series and review of the literature. *Am J Transplant*. 2006; 6: 225-231.
14. Cavallo R, Merlino C, Re D, Bollero C, Bergallo M, Lembo D, et al. B19 virus infection in renal transplant recipients. *J Clin Virol*. 2003; 26: 361-368.
15. Beckhoff A, Steffen I, Sandoz P, Hirsch HH, Schaub S. Relapsing severe anaemia due to primary parvovirus B19 infection after renal transplantation: a case report and review of the literature. *Nephrol Dial Transplant*. 2007; 22: 3660-3663.
16. Gosset C, Viglietti D, Hue K, Antoine C, Glotz D, Pillebout E. How many times can parvovirus B19-related anemia recur in solid organ transplant recipients? *Transpl Infect Dis*. 2012; 14: 64-70.