



# A novel wound closure technique for cesarean delivery

Jagat Prasad Deep<sup>1,2\*</sup>, Shweta Singh<sup>1</sup>, Renuka Tamrakar<sup>1</sup>

<sup>1</sup>Department of Obstetrics and Gynecology, CMC Teaching Hospital, Bharatpur-10, Nepal

<sup>2</sup>Department of Obstetrics and Gynecology NMC Teaching Hospital Birgunj Nepal

## Abstract

**Background:** Cesarean delivery method was conducted and a new surgical closure technique of wound was performed and cosmetic outcome was measured. Higher risk of maternal mortality and morbidity is associated with cesarean delivery than vaginal delivery particularly post-operative infection. It is important that the risks to the mother due to surgical procedure should be minimize by advancing the skill on preoperative skin preparation and wound closure methods as far as possible due to increase in caesarean section rate.

**Methods:** A retrospective study of eleven cases at two different university affiliated teaching hospitals of Nepal

**Results:** All eleven patients in this study had satisfaction for both post operative cosmetics outcome and post operative pain

**Conclusion:** This novel wound closure technique is valid alternative to gynecologists and patient satisfaction for post-operative scar appearance and post operative pain than traditional .

**Keywords:** Cosmetics cesarean section; Wound closure; Cesarean delivery

## INTRODUCTION

Cesarean section is one of most common major surgical procedure performed on women [1]. Cesarean section rate is increasing these days and need proper assessment of the patient, which may affect surgical outcome postoperatively [2]. One of the most frequently reported hospital acquired infection is surgical site infection particularly from those who are at higher risk of surgical site infection, such as malnourish, diabetes mellitus or obesity, or those who have an established infection before caesarean section. Cesarean section has ten times greater risk of wound infection than that of normal vaginal delivery [3]. Women who underwent cesarean section had high possibility of infection from their own and external or environmental sources. Proper preoperative and intraoperative preparation of an incision site with removal of surface dirt and oil by betadine scrub followed antimicrobial agent which reduce the bacterial population to a minimal level. Infection prevention with use of antiseptic has been practicing since 167 years. Antiseptic hand wash solution was first used in 1847 at the Vienna Maternity hospital to reduce maternal mortality due to puerperal sepsis [4]. The incidence varies from 3% to 15% of abdominal incisional infection following C-section.<sup>5</sup> Most common surgical incision

infection is a bacterial infection accompanied by temperature of 38.0°C (100.4°F) or higher on fourth postoperative day, lower abdominal pain [5,6] wound redness however in many cases there are preceded uterine infection and fever persists from first or second postoperative day and organism causing infection are usually from amniotic fluid [7]. It is not clear that which technique for skin closure during C- section should be used in order to get the best cosmetic result [8]. A Cochrane systematic review showed that there is no definitive evidence about how the C-section incision should be close [5]. Various types of techniques have been described for closing the wound after a Pfannenstiel incision [8].

The skin closure at C-section can be done by different techniques like mattress, interrupted, subcutaneous, staples or subcuticular stitches, in respect to cosmetic appearance [8]. Recently, several RCT addressing this issue have been published, with conflicting conclusion [9,10]. Some says a staple to be used while other says subcuticular stitches is superior choice [11,12].

## MATERIALS AND METHODS

Among eleven patients five were booked pregnant patients at CMCTH Bharatpur and six at NMCTH Birgunj between September 2012 and April 2017. All patient had given their informed consent to participate in this study.

### Patients

Exclusion criteria included the following: multigravida, diabetes, hypertension, preeclampsia, eclampsia, septicemia, high risk and impaired blood clotting pregnancy. Eleven pregnant women who were to undergo primary section were included in this study; all were primigravida, age less than 35years and all were of less than 35 BMI.

### Surgical technique and wound closure

This is a teaching hospitals case series. We did not use perioperative antibiotics. Shaving of the pubic hair was done by

**Submitted:** 24 June 2020 | **Accepted:** 18 July, 2020 | **Published:** 22 July, 2020

**\*Corresponding author:** Dr. Jagat Prasad Deep, Associate professor, Department of Obstetrics and Gynecology NMC Teaching Hospital Birgunj Nepal Cell: 977-9841331172, Email: jpdeep@hotmail.com

**Copyright:** © 2020 Deep JP, et al. This is an open-access article distributed under the terms of the Creative Commons Attribution License, which permits unrestricted use, distribution, and reproduction in any medium, provided the original author and source are credited.

**Citation:** Deep JP, Singh S, Tamrakar R (2020) A novel wound closure technique for cesarean delivery. SM Surg J 5: 3.

using a shaving machine. The skin was prepared by betadine, low transverse skin incision was given and C-section was done. We took three subsequent sutures, first at midline and two in either side. The suture was placed by inserting the needle at the junction of the dermis and the subcutis from lower edge of incision and then needle was inserted from subcutis and the dermis in upper edge of incision. The surgical technique entailed the placement of absorbable vicryl 2-0, deep sutures in the subcutaneous fat. The knot was buried. In addition, atraumatic skin handling technique with instrument like small forceps was used. No suture marks were visible (Figure 1).

## RESULTS

A total number of eleven women (Table 1) were taken for this new surgical closure technique. Nine women visited three times for their follow up at three weeks and at three months post operatively respectively while two women were lost at three months follow up but they presented on three weeks follow up schedule.

All patients in this study had their cesarean section performed by single experience gynecologist surgeon. On the surgery day, assessment of wound closure performance by the surgeon resulted as seen in figure 1. Wound closure was uneventful without any major complication and most of women showed high values of satisfaction for both cosmetic closure and post-operative pain of their first scar on their abdomen. No wound

dehiscence was seen in any case. No allergic reaction or infection was reported either.

Cesarean section is a common procedure performed on pregnant women globally, the wound closing methods of skin following a pfannenstiel incision remains controversial. The scar appearance is highly important to women that lead to surgeon to consider the important outcome of wound repair especially in cesarean section of primigravida. The Cosmetic appearance of the scar was evaluated at three weeks and three months post operatively (Figure 1) respectively. Evaluation was done by two gynecologists and patient herself. The digital picture was taken at closure of wound, at three weeks and at three months post-surgery respectively. This new method of surgical wound closure especially in primigravida was effective alternatives to the traditional wound closure methods.<sup>12</sup> A variety of materials and techniques are used for skin closure and there is still a need to identify which gives good cosmetics look postoperatively. Though several layers of women abdomen need to be cut and need to be closed again during cesarean section we used only vicryl no 2 cutting body and buried inside the wound. The cost of material used in surgical closure was also less because a single suture vicryl no. 2 was used in all cases however times consumed in this procedure was little more than convention method.

## DISCUSSION

We conducted a prospective study at two different university

Figure 1.

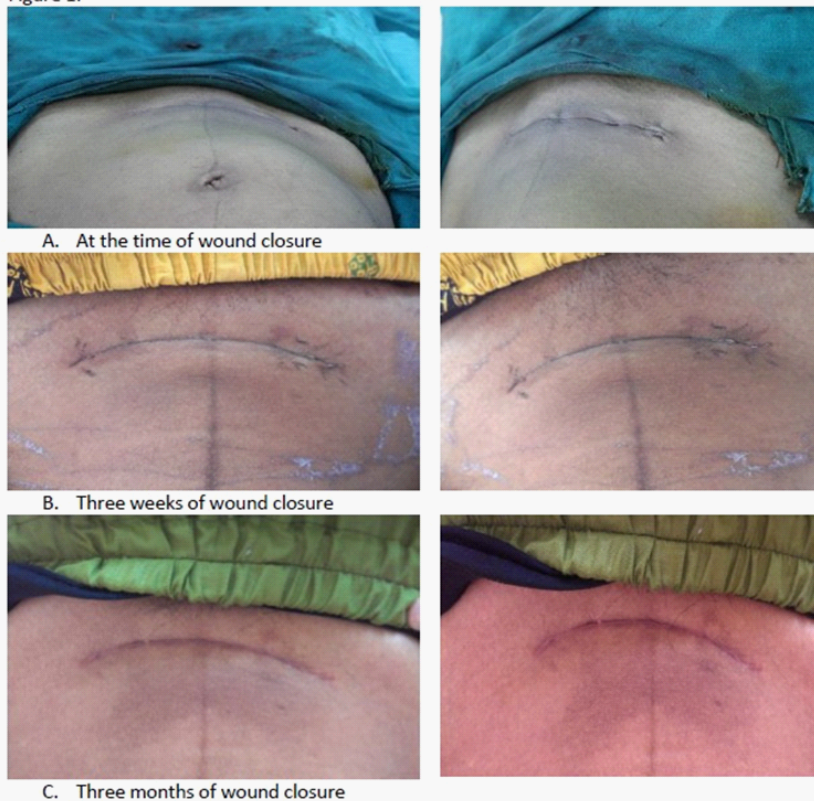


Figure 1



**Table 1:** Baseline characteristic of all eleven patients.

| IP No  | Age | Gravidity | Estimated Blood loss | BMI | Indication for C-Section   | Gestational Age   |
|--------|-----|-----------|----------------------|-----|----------------------------|-------------------|
| 72161  | 23  | Primi     | 300ml                | 31  | PROM                       | 40                |
| 80000  | 19  | Primi     | 250ml                | 28  | PROM +Mild meconium        | 39+ <sup>6</sup>  |
| 75272  | 25  | Primi     | 200ml                | 29  | PROM+ Oligohydramnios      | 39+ <sup>4</sup>  |
| 76228  | 24  | Primi     | 200ml                | 31  | Severe Oligohydramnios     | 29+ <sup>2</sup>  |
| 72101  | 30  | Primi     | 200ml                | 30  | IUGR+ Oligohydramnios      | 39                |
| 81102  | 21  | Primi     | 1000ml               | 34  | Oligo+ Breech Presentation | 39+ <sup>3</sup>  |
| 56685  | 24  | Primi     | 600 ml               | 33  | Breech Presentation        | 37                |
| 564037 | 22  | Primi     | 800ml                | 32  | TMSL                       | 37+ <sup>6</sup>  |
| 572954 | 21  | Primi     | 500ml                | 31  | Severe Oligohydramnios     | 36+ <sup>6</sup>  |
| 572289 | 21  | Primi     | 700ml                | 28  | Face Presentation          | 38+ <sup>2</sup>  |
| 13760  | 23  | Primi     | 300ml                | 29  | Precious Pregnancy         | 40 + <sup>4</sup> |

PROM: Premature rupture of membrane, IUGR: Intrauterine Growth Retardation, TMSL; Think Meconium stain liquor

affiliated teaching hospital of Nepal and post-operative outcome of new technique for wound closure after cesarean section in primigravida was assessed. There are several studies including randomized trial on cosmetics outcome after cesarean section, with conflicting result [11,12]. Most of study showed comparison of scar appearance outcome between subcuticular suture and staples while another study found no difference between staples or subcuticular suture on cosmetic appearance of the scar [9]. However our study shown better scar appearance. Comparing some meta-analysis focusing on wound complications [13,14] we found no wound complication in our study however all women underwent for surgery were less obese with less than 35 BMI. This study has several strong points as better cosmetics look post-operatively, less post-operative pain and high patient satisfaction though this study need longer follow up of patient at 6 months post-operative and double blinded observer to assess the scar appearance.

## CONCLUSION

Overall, this study clearly shows that the new cesarean section wound closure method in primigravida could represents a valid alternative to previous different methods for women demanding cosmetic surgery. Though the sample size is small outcome of this study is still valid for selected women in primigravida however randomized clinical trial is needed to strengthen this findings.

## REFERENCES

1. Tully L, Gates S, Brocklehurst P, McKenzie-McHarg K, Ayers S. Surgical techniques used during caesarean section operations: results of a national survey of practice in the UK. *European journal of obstetrics, gynecology, and reproductive biology*. 2002;102(2):120-6.
2. Thomas J, Callwood A, Brocklehurst P, Walker J. The National Sentinel Caesarean Section Audit. *BJOG : an international journal of obstetrics and gynaecology*. 2000;107(5):579-80.
3. Henderson E, Love EJ. Incidence of hospital-acquired infections associated with caesarean section. *The Journal of hospital infection*. 1995;29(4):245-55.
4. Noakes TD, Borresen J, Hew-Butler T, Lambert MI, Jordaan E. Semmelweis and the aetiology of puerperal sepsis 160 years on: an historical review. *Epidemiology and infection*. 2008;136(1):1-9.
5. Hadiati DR, Hakimi M, Nurdiani DS. Skin preparation for preventing infection following caesarean section. *The Cochrane database of systematic reviews*. 2012;9:CD007462.
6. Anderson BL. Puerperal group a streptococcal infection: beyond semmelweis. *Obstetrics and gynecology*. 2014;123(4):874-82.
7. Cunningham FG LK, Bloom SL, Hauth JC, Gilstrap III LC, Wenstrom KD, et al. Puerperal infection. *Williams Obstetrics 22nd Edition McGraw-Hill*. 2005.
8. de Graaf IM, Oude Rengerink K, Wiersma IC, Donker ME, Mol BW, Pajkrt E. Techniques for wound closure at caesarean section: a randomized clinical trial. *European journal of obstetrics, gynecology, and reproductive biology*. 2012;165(1):47-52.
9. Cromi A, Ghezzi F, Gottardi A, Cherubino M, Uccella S, Valdatta L. Cosmetic outcomes of various skin closure methods following caesarean delivery: a randomized trial. *American journal of obstetrics and gynecology*. 2010;203(1):36 e1-8.
10. Gaertner I, Burkhardt T, Beinder E. Scar appearance of different skin and subcutaneous tissue closure techniques in caesarean section: a randomized study. *European journal of obstetrics, gynecology, and reproductive biology*. 2008;138(1):29-33.
11. Rousseau JA, Girard K, Turcot-Lemay L, Thomas N. A randomized study comparing skin closure in caesarean sections: staples vs subcuticular sutures. *American journal of obstetrics and gynecology*. 2009;200(3):265 e1-4.
12. Frishman GN, Schwartz T, Hogan JW. Closure of Pfannenstiel skin incisions. Staples vs. subcuticular suture. *The Journal of reproductive medicine*. 1997;42(10):627-30.
13. Tuuli MG, Rampersad RM, Carbone JF, Stamilio D, Macones GA, Odibo AO. Staples compared with subcuticular suture for skin closure after caesarean delivery: a systematic review and meta-analysis. *Obstetrics and gynecology*. 2011;117(3):682-90.
14. Clay FS, Walsh CA, Walsh SR. Staples vs subcuticular sutures for skin closure at cesarean delivery: a metaanalysis of randomized controlled trials. *American journal of obstetrics and gynecology*. 2011;204(5):378-83.