

Mechanisms of Action of an  
Intraarticular 2.5% Polyacrylamide  
Hydrogel (Arthramid Vet) in a Goat  
Model of Osteoarthritis: Preliminary  
ObservationsAziz Tnibar<sup>1\*</sup>, Ann Britt Persson<sup>1</sup> and Henrik Elvang Jensen<sup>2</sup><sup>1</sup>Department of Large Animal Sciences, University of Copenhagen, Denmark<sup>2</sup>Department of Veterinary Disease Biology, University of Copenhagen, Denmark

## Article Information

Received date: Oct 13, 2017

Accepted date: Oct 24, 2017

Published date: Oct 27, 2017

## \*Corresponding author

Aziz Tnibar, Department of Large Animal Sciences, Faculty of Health and Medical Sciences, University of Copenhagen, Denmark, Tel: +212 614022722; Email: aztnibar@gmail.com

Distributed under Creative Commons  
CC-BY 4.0

**Keywords** 2.5% Polyacrylamide hydrogel; Osteoarthritis; Knee; Goat model; Treatment; Mechanisms of action; Observations

**Abbreviations** PAAG: 2.5% Polyacrylamide Hydrogel; OA: Osteoarthritis; MRI: Magnetic Resonance Imaging; OR: Odds Ratio; RL: Right Lateral (no OA joint); RM: Right Medial (no OA joint); LL: Left Lateral (OA joint); LM: Left Medial (OA joint); SD: Standard Deviation

## Abstract

A 2.5% Polyacrylamide Hydrogel (PAAG)<sup>a</sup> was tested for treatment of Osteoarthritis (OA) in a goat model (transection of medial collateral ligament, bisection of medial meniscus and partial-thickness cartilage incisions of medial tibial plateau) with highly encouraging results. The objective was to describe preliminary observations of the mechanisms of action of PAAG in OA joints, based on MRI, pathology and joint capsule elasticity investigations. A randomized controlled study was conducted on an OA knee model in goats: treatment group (intraarticular PAAG), control group (intraarticular saline). Magnetic Resonance Imaging (MRI) was performed prior to surgery, 3, 4, 5 and 7 months post-surgery. Seven months post-surgery, gross pathology and histopathology, including immunohistochemistry for nerve endings, were performed on both knees. Joint capsule elasticity of the knees was measured in both groups.

MRI showed reduction followed by stabilization of OA lesions after PAAG treatment. At gross pathology, PAAG was seen adhering to synovial membrane. Histopathology showed that intraarticular PAAG injection added to the thickness of the synovial membrane by allowing angiogenesis, collagen and synovial cell increase; PAAG was integrated into the synovial membrane. Nerve endings were intact with normal morphology and numbers. Joint capsule elasticity investigation showed that treated knees had a higher elasticity when compared to control knees. This study presents preliminary observations of the mechanisms of action of PAAG on OA joints: (1) Pathology and joint capsule elasticity suggest that PAAG by acting on synovial membrane may reduce overall joint capsule stiffness, a major source of pain in OA. (2) MRI and pathology revealed stabilization of OA lesions in PAAG treated goats, possibly caused by the high viscosupplementation of PAAG.

## Introduction

Osteoarthritis (OA) is a common clinical problem in animals [1,2], as well as the most common joint disease and one of the most frequent causes of physical impairment in humans [3]. As part of the OA-complex, elastoviscosity of the synovial fluid is abnormally low [4], and thus the use of viscosupplementation, for example intra-articular injections of high molecular-weight hyaluronic acid, has been implemented as part of the treatment for OA in humans [5,6], as well as animals (e.g. horses) [7].

2.5% Polyacrylamide hydrogel (PAAG) is a non-toxic and non-immunogenic biocompatible polymer gel consisting of 97.5% sterile water and 2.5% cross-linked polyacrylamide [8,9] (Arthramid<sup>®</sup> Vet, Contura International A/S, 2860, Søborg, Denmark), and its biocompatibility in soft tissues has been demonstrated [10-12]. Also, PAAG is a non-particulate homogenous gel similar to hyaluronic acid in overall structure and tissue compatibility [11], but with a longer-lasting viscous effect, as it is non-degradable [8]. PAAG has also proven to be safe in humans over more than 16 years of use for the augmentation of connective tissues [12,13], and in horses as well [14-16]. Experimental studies supported by histopathological observations have shown that PAAG exerts its effect via integration over time within the soft tissues, through a combination of vessel in-growth and molecular water exchange [8,11].

Recent clinical and experimental trials have investigated the effect of PAAG on improving clinical signs of OA in horses [14-16], and in a goat model [17]. Forty three horses, older than two years with OA located within only one joint were treated intraarticularly with PAAG and were followed-up at 1, 3, 6, 12 and 24 months. At 6 months, approximately 79% of horses were sound (non-lame) [15]. At 12 months, 81% of the horses from the same study population were sound [15]. At 24 months follow-up, 82.5% of horses were sound and no side effect was observed in the treated joints during the study period [15]. In this study, there was a significant decrease in lameness score

from baseline to 1, 3, 6, 12 and 24 months ( $p < 0.0001$ ) and a significant association with joint effusion ( $p < 0.0001$ ). Estimates for Odds Ratio (OR) showed that the effect of treatment increased over time (OR for lower lameness from month 1 to 24 relative to baseline increased from 20 to 58). A comparative prospective study has demonstrated that horses with OA treated with PAAG significantly improved their clinical signs when compared to horses with OA treated with Triamcinolone acetonide combined with hyaluronic acid [14]. Another report has shown that PAAG effectively relieved lameness in horses with distal interphalangeal joint OA [16]. A recent randomized controlled pilot study using an experimental OA model in goats has shown that PAAG was integrated into the synovial membranes of the injected joint, and significantly improved the lameness caused by OA, with 75% of the cases becoming sound at 4 months post treatment evaluation [17].

The purpose of this paper was to describe the preliminary observations of the mechanisms of action of a PAAG in OA joints. These observations were based on the results from MRI, joint pathology and joint capsule elasticity investigations.

## Methods

This experimental study was conducted between June 2011 and February 2013 and was approved by the Danish Council for Animal Experimentation. This randomized controlled study was conducted involving 6 goats with induced OA on the left knee joint. OA was surgically induced by the transection of the medial collateral ligament, the bisection of the medial meniscus at its midpoint and partial-thickness incisions of the cartilage of the medial tibial plateau [18]. Goats were allowed free exercise, and 3 months after surgery they were randomly divided into 2 groups: Treatment group ( $n=4$ ) which received PAAG and control group ( $n=2$ ) which received saline solution. PAAG and saline solution were injected intraarticularly (1 ml). All goats were videotaped on a treadmill for lameness examination.

### Magnetic resonance imaging investigation

MRI of the left knee was performed prior to surgery, at the time of joint injection (3 months) and 4, 5 and 7 months post-surgery. T1 (coronal and sagittal) T2/PD (coronal and transverse) and Stir (sagittal and coronal) weighted MRI images using a 0.2 T scanner<sup>b</sup> (Knee coil) were obtained to assess OA.

### Histopathological investigation

The goats were euthanized 7 months after surgery, then gross pathology and histopathology, including immunohistochemistry for nerve endings, was performed on both femorotibial joints and elbows. On the operated knee, special attention was given to the location of the gel, the surgical site (the medial meniscus and the articular cartilage of the medial tibia), the synovial membrane, and the articular cartilage. The macroscopic appearance of the articular cartilage was scored using a subjective grade (0: normal; 1: minimal cartilage fibrillations; 2: moderate cartilage fibrillations; 3: marked cartilage fibrillations; 4: cartilage erosion). At the macroscopic evaluation, the medial and lateral menisci were removed and placed in formalin along with a piece of the synovial membrane from the lateral and medial sides. This was done both from the right and left knee. The menisci and synovial membrane were sectioned and embedded in

paraffin for histological evaluation. After macroscopic evaluation, all joints were labeled, fixed in 10% neutral formalin for approximately one week and then placed in formic acid for decalcification. When the decalcification process was complete, all joints were rinsed in buffer, sagittally sectioned and embedded in paraffin. Specimens from the induced trauma site (the medial meniscus and the articular cartilage from the medial tibia and medial femoral condyle), controls from the lateral meniscus and the articular cartilage from the lateral tibia and the lateral femoral condyle, and the synovial membrane including areas containing gel were included in the 5  $\mu\text{m}$  sections of the joints. All specimens were stained with Haematoxylin and Eosin (H&E). Other stains like Safranin-O, PAS, Masson Tri-chrome, and GFAP for nerve fibers were also used. Macro- and micro photographs were taken all along, both during the joint dissection procedure and after histopathological processing (paraffin embedment, 5  $\mu\text{m}$  sectioning and staining).

### Nerve endings staining

Three methods were validated in order to identify the presence of nerves in the synovial membrane: GFAP (Glial Fibrillary Acidic Protein), S100, and anti-neurofilament. A normal looking synovial membrane was stained by the three methods. The GFAP stain stained nerve endings dark brown whereas the S100 also stained vessels and the neurofilament stain did not stain the nerve endings. Three goats were used for the nerve staining: 1 goat that was fully sound after PAAG treatment, 1 goat that was partly sound after PAAG treatment, and 1 control goat.

### Joint elasticity investigation

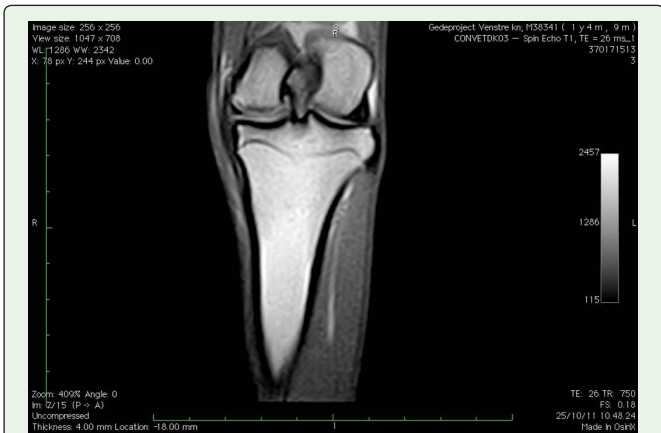**Definitions:** Elasticity is defined as maximum strain capacity of the tissue, without disruption.

Strain is the ratio of change in a certain length parameter, caused by deformation to the original value of the length parameter. It is measured in this study as percentage of true max strain (% true max strain). It is understood that tissue with higher strain without disruption has a higher elasticity; in other words it can be stretched more without disruption. For instance, a stiffer joint capsule has lower tissue elasticity and a lower % of true max strain.

Stress is the force causing the deformation, divided by the area to which the force is applied. In this study the true max stress of the tissue was measured, without disruption. It is delivered as true max stress in Megapascal (MPa). A tissue with higher true max stress data is one having a higher capacity for handling deformation. The elastic modulus of a tissue is defined as the slope of its stress-strain curve.

Following euthanasia, a small piece of the lateral and medial sides of the right and left knee joint of each of the 6 goats was removed for evaluation of joint capsule elasticity. The pieces were approximately 3x1 cm (length x width) each. The samples were cut out after removal of skin using a scalpel, and transported for measurement in a tube containing 0.9% saline. The elasticity of the samples was measured between 1 and 4 hours post-euthanasia, and the measurements were divided over 2 days: 4 goats on Day 1 and 2 goats on Day 2. The Instron 5564<sup>c</sup> was used to measure joint capsule elasticity.

The maximum values of joint capsule elasticity, corresponding to the start of rupture, were read off the stress-strain curves presented



**Figure 1:** Magnetic Resonance image of a goat treated with a 2.5% polyacrylamide hydrogel showing osteoarthritic changes at the medial femorotibialjoint (Knee).

according to the strain degree. These maximum values were compared with the control (i.e. comparison of the value for the treated joint with that of the non-treated joint).

This comparison was expressed as a relative deviation and given as a percentage. This allowed the effectiveness (positive percentage value) or ineffectiveness (negative percentage value) of the treatment to be measured.

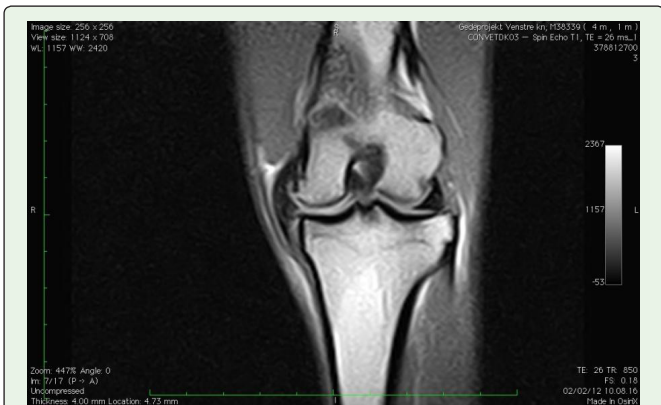The values expressed corresponded to the arithmetic average of these relative deviations, expressed as a %, and the standard deviation from this average for the same data.

**Results**

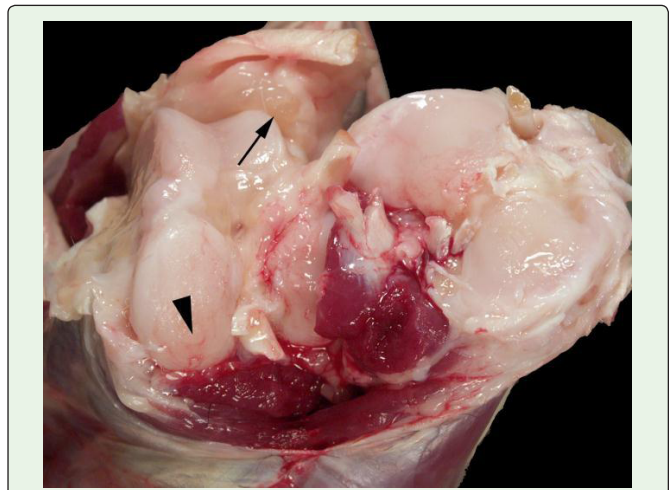
**Magnetic resonance imaging**

MRI showed reduction followed by stabilization of the OA lesions (intraarticular bony and cartilaginous lesions) after PAAG treatment in 3 goats in the treatment group (Figure 1), while one goat had a mild progression of the OA lesions.

In the control group, all goats had a mild or marked increase of the OA lesions (intraarticular bony and cartilaginous lesions) and periarticular lesions throughout the study period (Figure 2).



**Figure 2:** Magnetic Resonance image of a control goat showing marked periarticular and intraarticular changes at the medial femorotibialjoint (Knee).



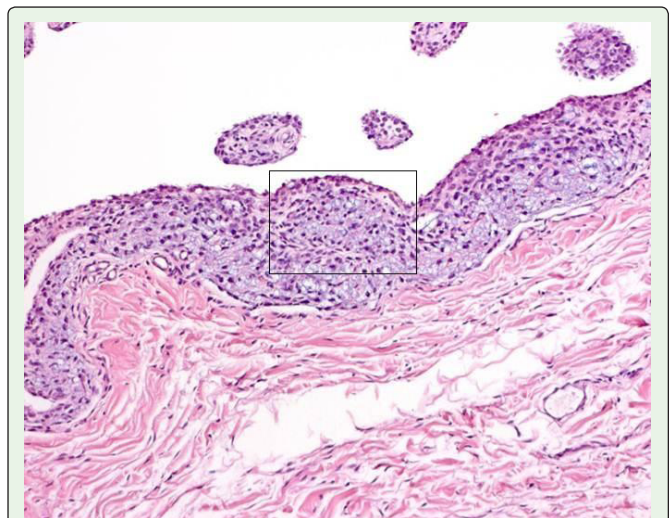
**Figure 3:** The 2.5% Polyacrylamide hydrogel is present into the joint space, adherent to the synovial membrane [Arrow]. Note the osteoarthritic lesion of the medial femoral condyle [Arrow head].

**Gross pathology inspection**

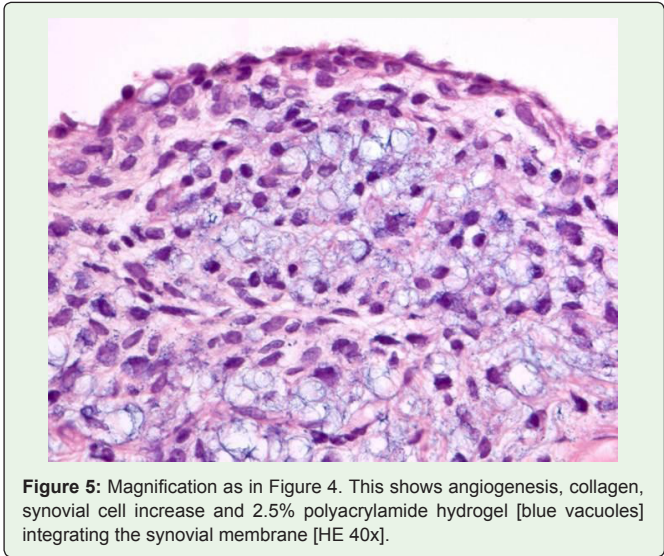
The left knees (operated knees) showed typical signs of OA. The inner synovial lining showed swelling and hyperplasia in all the goats, and there was also an uneven cartilage surface due to erosions in several foci in all cases (Figure 3). The gel was seen in various amounts adhering to the inner side of the joint capsule in all the treated goats (Figure 3). Gross inspection of the goats in the treatment group showed cartilage lesions and synovial thickening, but this was less prominent in this group than in the control group.

**Histopathology**

The hyperplasia of the inner capsule/synovial membrane that was seen at gross inspection was more significant in the treated goats than in the control goats. It comprised of angiogenesis, increased collagen and perivascular cell density and in the treated goats, also the presence of the gel.



**Figure 4:** Histopathology of the synovial membrane of a goat's knee 4 months after treatment with a 2.5% polyacrylamide hydrogel [HE 10x].



**Figure 5:** Magnification as in Figure 4. This shows angiogenesis, collagen, synovial cell increase and 2.5% polyacrylamide hydrogel [blue vacuoles] integrating the synovial membrane [HE 40x].

PAAG injection into the joint cavity added to the thickness of the synovial membrane by allowing angiogenesis, collagen and synovial cell increase. The gel was seen integrated into the synovial membrane (Figures 4 and 5).

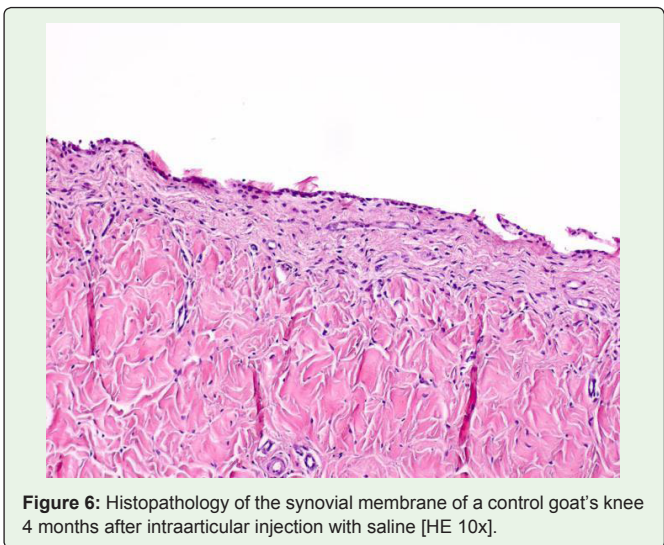
In the control goats, there was a minimal synovial membrane hyperplasia and an increased amount of collagen (Figures 6 and 7).

In the nerve endings investigation, the nerve endings were seen in a similar pattern, whether the goats had had good or minor clinical results from the PAAG gel injection or none at all (saline only). In all goats used for nerve staining, the nerves were intact with normal morphology and in normal numbers (Figure 8). No sign of neurotoxicity was observed.

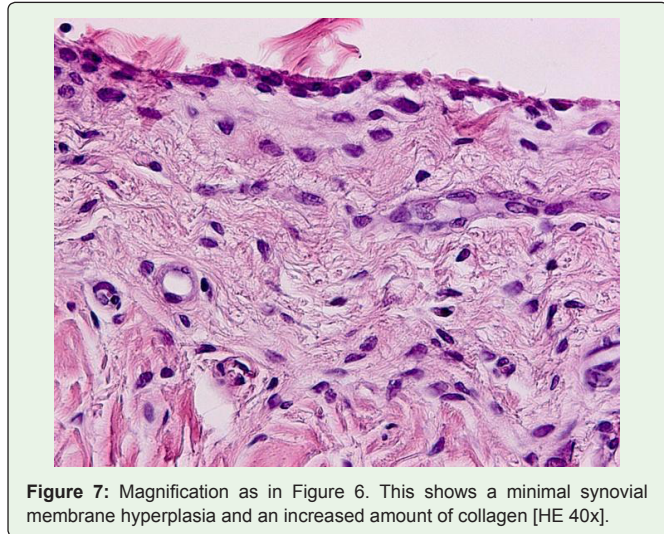
**Joint elasticity**

**Control group:**

**Lateral side of the joint capsule:** Figure 9 depicted the true max strain values of the lateral joint capsule from both right (non OA) and left (OA) knee joints of one of the control goats.



**Figure 6:** Histopathology of the synovial membrane of a control goat's knee 4 months after intraarticular injection with saline [HE 10x].



**Figure 7:** Magnification as in Figure 6. This shows a minimal synovial membrane hyperplasia and an increased amount of collagen [HE 40x].

The lateral side of the joint capsule from the OA left knee showed less elasticity (or more stiffness) than the right (non OA) knee with -10% on average (+/-5% of SD).

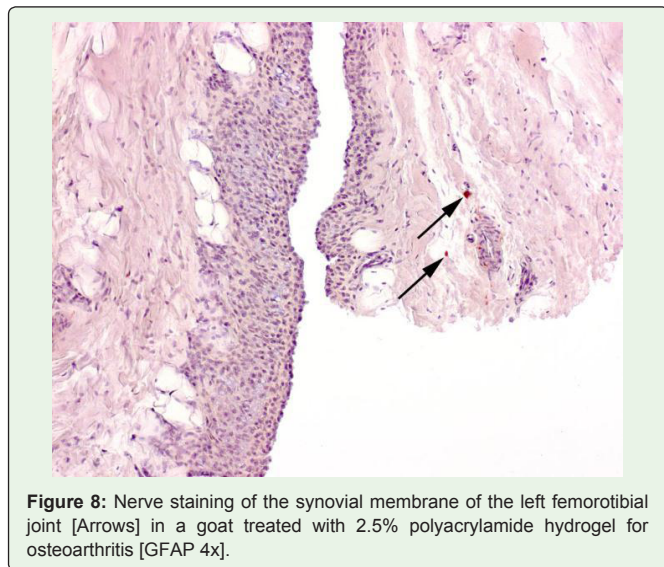
**Medial side of the joint capsule:** The OA left knee showed less elasticity (or more stiffness) than the right (non OA) knee with -20% difference.

In the control group, the lateral and medial sides of the joint capsule from the OA control left knee showed less elasticity (or more stiffness) than the right (non OA) knee with -10% of elasticity average (+/-5% of SD) and -20% on average, respectively.

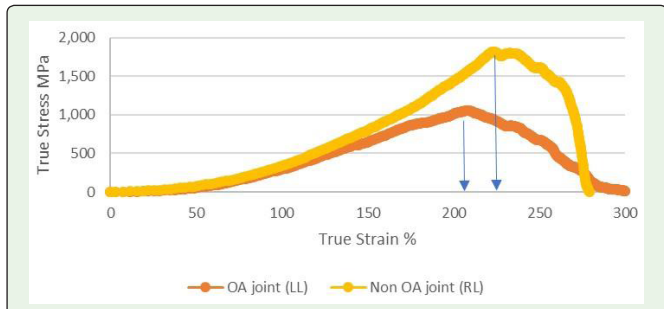
**Treated group:**

**Lateral side of the joint capsule:** Figure 10 showed the true max strain values of the lateral joint capsule from the right and left knee joint in one on the treated goats.

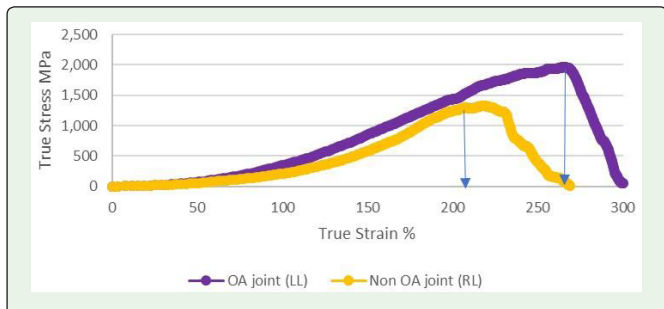
The lateral side of the joint capsule from the OA treated left knee showed more elasticity (or less stiffness) than the right (non OA) knee with +20% on average (+/-23% of SD).



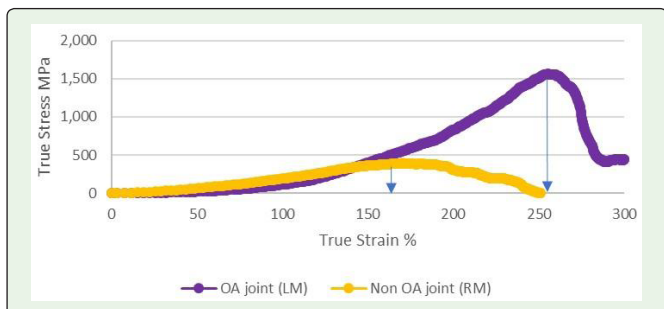
**Figure 8:** Nerve staining of the synovial membrane of the left femorotibial joint [Arrows] in a goat treated with 2.5% polyacrylamide hydrogel for osteoarthritis [GFAP 4x].



**Figure 9:** Comparison of joint capsule elasticity of an osteoarthritic knee (lateral) vs. non osteoarthritic knee (lateral) in one of the control goats.



**Figure 10:** Comparison of joint capsule elasticity of an osteoarthritic knee (lateral) vs. non osteoarthritic knee (lateral) in one of the treated goats.



**Figure 11:** Comparison of joint capsule elasticity of an osteoarthritic knee (medial) vs. non osteoarthritic knee (medial) in one of the treated goats.

**Medial side of the joint capsule:** Figure 11 showed the true max strain values of the medial joint capsule from the right and left knee joint from one of the treated goats.

The medial side of the joint capsule from the OA treated left knee showed more elasticity (or less stiffness) than the right (non OA) knee with +40% on average (+/-18% of SD).

In the treated goats, the lateral and medial side of the joint capsule from the OA treated left knee showed more elasticity (or less stiffness) than the right (non OA) knee with +20% of true max stress average (+/-23% of SD) and +40% on average (+/-18% SD), respectively.

No adverse effects associated with the treated joints were detected during the study period.

**Discussion**

The 2.5% PAAG is a novel and promising treatment for OA and its clinical efficacy was reported in horses [14-16] and in a goat model

[17]. No adverse effects were observed in the treated joints of goats 4 months after the injection of the PAAG [17], which is consistent with the safety of PAAG that has been described in horses in the 24 months follow-up clinical study of OA joints treated with PAAG [15].

In addition, intraarticular treatment with PAAG did not have any influence on haematology, biochemistry, or acute phase proteins [17].

PAAG (Arthramid Vet) is different from other described hydrogels which have different concentration of polyacrylamide, and may contain other components as well.

Precise characterization of the mechanism-of-action of PAAG on OA joints has not yet been established, but histopathological observations on joint tissue from the experimental study in goats [17], and from horses and rabbits [19], have demonstrated that a part of the PAAG, like in other soft tissues, becomes integrated within the synovial membrane. PAAG injected 4 months earlier into an experimentally induced OA joint induced a moderate synovial hyperplasia of the inner side of the joint capsule with integrated gel, angiogenesis and collagen production [17]. A similar tissue reaction was seen in horses with osteoarthritic joints that were injected with PAAG, including cases treated 2 years earlier with PAAG [19].

PAAG has been found to be present in the joint cavity in all the goats [17], as well as in horses treated with PAAG [19]. PAAG is a non-degradable and highly viscous product [8] and thus might contribute to protecting the articular surface of an osteoarthritic joint, and hence it could reduce and stabilize the OA lesions. Lack of joint lubrication is postulated to play a significant role in the pathogenesis of OA [20]. This emphasizes the role of viscosupplementation, and hence the improvement of lubrication within the joint, in protecting a joint suffering from OA, and reducing the resulting pain. Recently, a study supported the use of intra-articular lubricin as an adjunct to viscosupplementation for retarding cartilage degeneration and possibly the development of post-traumatic OA [21,22].

MRI follow-up showed reduction followed by stabilization of the OA lesions after PAAG treatment in goats

The joint capsule elasticity investigation has shown that the capsule of the joints injected with PAAG had a better elasticity when compared to the joint capsule of the control joints. OA joints typically show joint stiffness which is a major source of pain in OA. This is supported by a recent study on knee joint stiffness in humans, which has shown that stiffness co-efficient, was higher in individuals with painful OA [23].

By integrating the synovial membrane, which may probably decrease the joint capsule and the joint stiffness, PAAG might relieve pain of the OA joint. This theory is supported by clinical observations in the clinical trials in horses [14,15], where OA joint that responded well to PAAG are no more painful to joint flexion after having been painful to joint flexion before treatment.

Although conventional concepts of OA emphasize the direct and predominant involvement of cartilage and bone in OA development, it is increasingly recognized that the synovium also contributes to the central pathophysiological event of cartilage matrix depletion.

This study presents some preliminary observations of the mechanisms of action of PAAG on OA joints. Preliminary pathology

and joint capsule elasticity data suggest that PAAG by acting mainly on the soft tissue of the joint, in particular the synovial membrane may reduce the overall joint capsule stiffness, a major source of pain in the OA joint. On the other hand, MRI and pathology investigations have further revealed stabilization of the OA lesions in the PAAG treated goats, possibly caused by the high viscosupplementation, and thus protective effect of PAAG.

In addition, PAAG significantly alleviated lameness in OA joints, as assessed by clinical lameness evaluation (ground and treadmill evaluations) [17]. In the 24 months follow-up in horses, the largest reduction in lameness score appeared from baseline to month 1. Thus, the clinical improvement in lameness score was already present one month after PAAG treatment. This suggests that the effect of PAAG on OA might occur mainly during the first month after treatment and lasts and increases progressively until 6 months, with a stabilization between 6 and 24 months [15]. This 24 months follow up trial has also demonstrated that joint effusion score decreases significantly over time ( $p < 0.0001$ ). Although joint effusion was subjectively assessed in the horse study, PAAG induced a significant decrease in joint effusion in the OA joints. However, the mechanism-of-action of PAAG in reducing joint effusion in OA joints needs to be investigated. In the experimental OA model in goats [17], joint effusion was not observed, and thus not evaluated.

These preliminary observations of the mechanisms of action of PAAG emphasize the role of synovial membrane and joint capsule, as well as the role of the long acting viscosupplementation, in the treatment of OA. This certainly opens new horizons in the understanding of OA and its treatment.

Further studies are needed to understand more the mechanisms of action of PAAG in improving clinical signs of OA and in stabilizing its progression.

### Ethics Approval of Research on Animals

The study was approved by the Danish Council for Animal Experimentation.

Authorization number: 2011/561-2021.

### Acknowledgement

This study was financed by Contura International A/S, 2860, Søborg, Denmark. The study was independently designed by the study investigator (AT).

The authors would like to thank B. Brünner for helping with the study and C. Calleja for the help with the elasticity study data.

### Endnotes

<sup>a</sup>Arthramid<sup>®</sup> Vet, Contura International A/S, 2860, Søborg, Denmark.

<sup>b</sup>Vetscan (Knee coil), Esaote, Genova, Italy.

<sup>c</sup>Instron<sup>®</sup> 5564 Testing system. HIS GlobalSpec, MA, USA.

### References

- United States Department of Agriculture. Lameness and laminitis in US horses. National Animal Health Monitoring System. 2017.
- Caron JP. Osteoarthritis: Diagnosis and management of lameness in the horse. 2<sup>nd</sup> edn. St Louis: WB Saunders Company. 2011.
- Buckwalter JA, Saltzman C, Brown T. The impact of osteoarthritis: implications for research. *Clin Orthop Relat Res*. 2004; 427: 6-15.
- Balazs EA. The physical properties of synovial fluid and the special role of hyaluronan acid: Disorders of the knee. Philadelphia: T.B. Lippincott Company. 1982; 63-75.
- Altman RD. Intra-articular sodium hyaluronate in osteoarthritis of the knee. *Semin Arthritis Rheum*. 2000; 30: 11-18.
- Balazs EA. Viscosupplementation for the treatment of osteoarthritis: from initial discovery to current status and results. *Surg Technol Int*. 2004; 12: 278-289.
- Frisbie DD, Kawcak CE, McIlwraith CW, Werpy NM. Evaluation of polysulphated glucosaminoglycan or sodium hyaluronan administered intra-articularly for treatment of horses with experimentally induced osteoarthritis. *Am J Vet Res*. 2009; 70: 203-209.
- Christensen LH, Breiting VB, Aasted A, Jørgensen A, Kebuladze I. Long term effects of polyacrylamide hydrogel in human breast tissue. *Plast Reconstr Surg*. 2003; 111: 1883-1889.
- Zarini E, Supino R, Pratesi G, Laccabue D, Tortoreto M, Scanziani E, et al. Biocompatibility and tissue interactions of a new filler material for medical use. *Plast Reconstr Surg*. 2004; 114: 934-942.
- Lloyd AW, Faragher RG, Denyer SP. Ocular biomaterials and implants. *Biomaterials*. 2001; 22: 769-785.
- Fernández-Cossío S, Castaño-Oreja MT. Biocompatibility of two novel dermal fillers: Histological evaluation of implants of a hyaluronic acid filler and a polyacrylamide filler. *Plast Reconstr Surg*. 2006; 117: 1789-1796.
- Christensen LH, Nielsen J, Mouritsen L, Sørensen M, Lose G. Tissue integration of polyacrylamide hydrogel: An experimental study of periurethral, perivesical, and mammary gland tissue in the pig. *Dermatol Surg*. 2008; 34: 68-77.
- Lose G, Mouritsen L, Nielsen J. A new bulking agent (polyacrylamide hydrogel) for treating stress urinary incontinence in women. *BJU Int*. 2006; 98: 100-104.
- Tnibar A, Schougaard H, Koene M, Christensen LH, Markussen B. A Controlled Clinical Trial on the Efficacy of an Intra-articular Polyacrylamide Hydrogel in Horses with Osteoarthritis [abstract]. *Vet Surg*. 2014; 43: s138.
- Tnibar A, Schougaard H, Camitz L, Rasmussen J, Koene M, Jahn W et al. An international multi-centre prospective study on the efficacy of an intraarticular polyacrylamide hydrogel in horses with osteoarthritis: a 24 months follow-up. *Acta Vet Scand*. 2015; 57: 20-27.
- Janssen I, Koene M, Lischer L. Intraartikuläre Applikation von Polyacrylamid Hydrogel zur Behandlung von Osteoarthritis des Hufgelenkes: Fallserie von 12 Pferden. *Pferdheilkunde*. 2012; 28: 650-656.
- Tnibar A, Persson A, Jensen HE, Svalastoga E, Westrup U, McEvoy F, et al. Evaluation of a polyacrylamide hydrogel in the treatment of induced osteoarthritis in a goat model: A pilot randomized controlled Study [abstract]. *Osteoarthritis and Cartilage*. 2014; 22: 477.
- Didier L, O'Byrne E, Wasvary J, Pellas T. In vivo MRI of cartilage pathogenesis in surgical models of osteoarthritis. *Skeletal Radiol*. 2006; 35: 555-564.
- Christensen LH, Camitz L, Illigen KE, Hansen M, Sarvaa R, Conaghan PG, et al. The effects of polyacrylamide hydrogel in normal and osteoarthritic animal joints. *Osteoarthritis and Cartilage*. 2016; 24: 449-450.
- Elsaid KA, Fleming BC, Oksendahl HL, Machan JT, Fadale PD, Hulstyn MJ, et al. Decreased lubricin concentrations and markers of joint inflammation in the synovial fluid of patients with anterior cruciate ligament injury. *Arthritis Rheum*. 2008; 58: 1707-1715.
- Flannery CR, Zollner R, Corcoran C, Jones AR, Root A, Rivera-Bermúdez MA, et al. Prevention of cartilage degeneration in a rat model of osteoarthritis by intraarticular treatment with recombinant lubricin. *Arthritis Rheum*. 2009; 60: 840-847.

22. Jay GD, Elsaid KA, Kelly KA, Anderson SC, Zhang L, Teeple E, et al. Prevention of cartilage degeneration and gait asymmetry by lubricin tribosupplementation in the rat following anterior cruciate ligament transection. *Arthritis Rheum.* 2012; 64: 1162-1171.
23. Hall MC, Doherty S, Zhang W, Doherty M. Knee joint stiffness and its relationship to severity of radiographic osteoarthritis, pain and self-reported stiffness [abstract]. *Osteoarthritis and cartilage.* 2014; 22: 92.