

Punctate Palmoplantar Keratoderma (Brauer-Buschke-Fisher Syndrome) - Report of a Case and Review of the Literature

Alexander KC Leung^{1*} and Benjamin Barankin²

¹University of Calgary, Canada

²Toronto Dermatology Centre, Canada

Article Information

Received date: Jun 08, 2015

Accepted date: Jul 20, 2015

Published date: Aug 19, 2015

*Corresponding author

Alexander KC Leung, #200, 233-16th
Avenue NW, Calgary, Alberta T2M 0H5,
Canada, Fax: 403-230-3322;
Email: aleung@ucalgary.ca

Distributed under Creative Commons
CC-BY 4.0

Key words Punctate; Hyperkeratotic
papules; Palms; Soles; Autosomal
dominant.

Abstract

We report a 47-year-old Caucasian man, a construction worker, with multiple asymptomatic hyperkeratotic lesions on the palms and soles. The lesions developed after puberty and slowly increased in size and number thereafter. His father, sister, and son had similar lesions on the palms and soles. Examination revealed numerous yellowish brown hyperkeratotic papules varying in size from 1 to 3 mm irregularly distributed on his palms, fingers, and soles. Central depressions were observed in some of the larger lesions. Some of the papules were coalesced to form larger hyperkeratotic plaques on the weight-bearing areas of his soles. A diagnosis of punctate palmoplantar keratoderma type 1 was made based on a positive family history, typical lesions (punctate hyperkeratotic papules), typical locations (palms and soles), and typical course (lesions increased in size and number with time).

Introduction

Punctate palmoplantar keratoderma type 1, also known as Brauer-Buschke-Fisher syndrome, is an autosomal dominant inherited disorder with variable penetrance. The disorder is characterized by multiple punctate hyperkeratotic papules on the palms and soles. Although it is a clinical rarity, a spot diagnosis can usually be made provided one is familiar with the condition thereby unnecessary diagnostic procedures can be avoided. A review of the topic is therefore in order and is the purpose of the present article.

Illustrative Case

A 47-year-old Caucasian man, a construction worker, presented with multiple asymptomatic hyperkeratotic lesions on the palms and soles; he had always assumed that these were warts. The lesions developed after puberty and slowly increased in size and number thereafter. The lesions were unaffected after immersion in water. There was no history of exposure to arsenic. The patient had a family history of the disorder. The pedigree of this family is shown in Figure 1.

On examination, there were numerous yellowish brown punctate hyperkeratotic papules varying in size from 1 to 3 mm irregularly distributed on his palms, fingers (Figure 2), and soles. Central depressions were observed in some of the larger lesions. Some of the papules were coalesced to form larger hyperkeratotic plaques on the weight-bearing areas of his soles. A diagnosis of punctate palmoplantar keratoderma type 1 was made. Lesions were pared, sprayed gently with liquid nitrogen, and the patient was encouraged to use a topical retinoid at night-time to minimize recurrence of the lesions. He was satisfied to find out that the lesions were not contagious. He was unfortunately lost in follow-up.

Discussion

Palmoplantar keratodermas are a heterogeneous group of cornification disorders characterized by hyperkeratotic lesions on the palms and soles [1]. Clinically, they can be classified according to the pattern of the lesions into four main categories: diffuse, focal, striate, and punctate [1]. Three distinct types of punctate palmoplantar keratoderma (PPKP) have been recognized, namely, punctate palmoplantar keratoderma type 1 (PPKP1), punctate palmoplantar keratoderma type 2 (PPKP2) (porokeratotic type or porokeratosis punctata palmaris et plantaris), and punctate palmoplantar keratoderma type 3 (PPKP3) (focal acrohyperkeratosis or acrokeratoelastoidosis lichenoides) [1]. PPKP1 was first described in 1910 by Buschke and Fisher [2]. Brauer confirmed the hereditary nature of this condition in 1913 [3]. Hence, the disease is also referred to as Brauer-Buschke-Fisher syndrome.

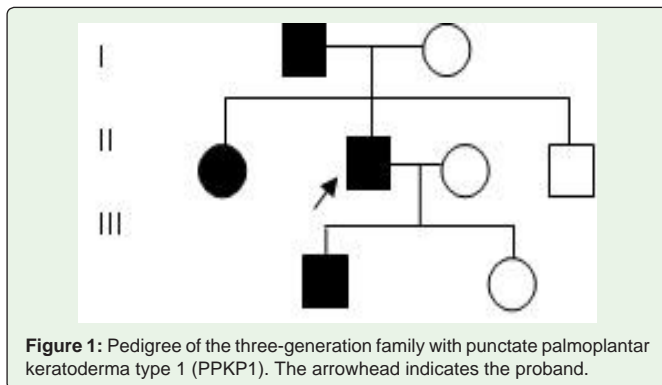


Figure 1: Pedigree of the three-generation family with punctate palmoplantar keratoderma type 1 (PPKP1). The arrowhead indicates the proband.

Epidemiology

The overall prevalence is estimated at 1.17 to 3.3 per 100,000 [4]. The onset is usually during adolescence to early adulthood, but may also start to appear up to the fifth decade of life [5]. The condition is more common in males, manual laborers, and dark-skinned individuals [5].

Etiopathogenesis

PPKP1 has an autosomal dominant mode of inheritance with variable penetrance [6,7]. Using whole-exome sequencing and linkage analysis, the causative gene *AAGAB* has been mapped to chromosome 15q22-24 [8,9]. *AAGAB* encodes α - and γ -adaplin binding protein p34. The protein is involved in clathrin-mediated vesicle transport and plays a pivotal role in the endocytosis and recycling of receptor tyrosine kinases such as epidermal growth factor [1,8,10]. As such, loss-of-function mutations in *AAGAB* leads to increased half-life of several receptor tyrosine kinases in basal keratinocytes with resultant hyperproliferative hyperkeratosis on the palmoplantar areas [10]. It has been shown that *COL14A1* mapped at 8q24.13-8q24.21 is also a causal gene [4]. Environmental factors are operative which account for the delayed onset of the lesions. Physical trauma plays an important role in exacerbating the abnormal localized hyperproliferative response [7]. This may account for the male predominance as males are more often engaged in manual labor work compared with females.

Histopathology

Histological findings include thickening of stratum corneum, flattening of structures below the thickened stratum corneum, hyperkeratosis, acanthosis, and hypergranulosis associated with a well-defined central epidermal depression [7,10]. The dermis is usually normal.

Clinical Manifestations

Clinically, PPKP1 is characterized by multiple, minute, discrete, yellow, punctate hyperkeratotic papules with central indentation. The papules are irregularly distributed on the palms and soles [5,9]. Involvement is typically bilateral. Lesions usually start in adolescence and increase in size and number with time. Some of the lesions may coalesce to form diffuse, hyperkeratotic plaques in mechanically irritated or pressure-bearing areas such as the soles of the feet [9]. Although the lesions are usually asymptomatic, pain upon blunt pressure on the lesions or walking may occasionally be encountered

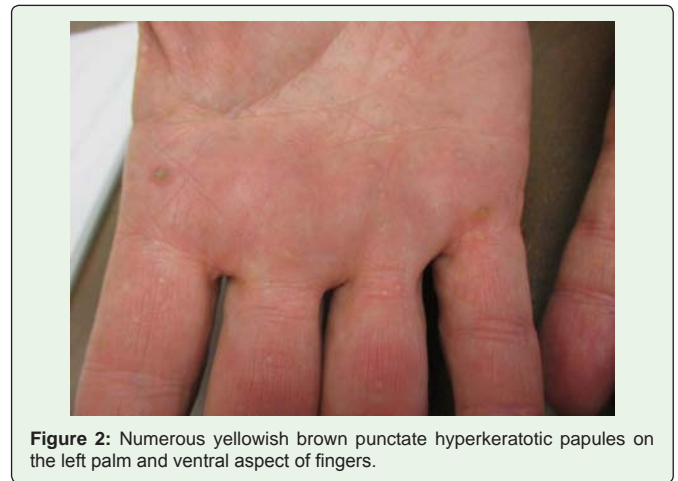


Figure 2: Numerous yellowish brown punctate hyperkeratotic papules on the left palm and ventral aspect of fingers.

[6]. The papules, when removed, often leave behind crateriform pits, but will eventually reform [7].

PPKP1 is usually an isolated finding. Rarely, it may be associated with psoriasis, lentigo simplex, and guttate hypopigmentation [6,11,12]. Guttate hypopigmentation and PPKP1 are parts of the constellation of clinical features of Darier disease and epidermolysis bullosa simplex with mottled pigmentation [12].

Diagnosis

The diagnosis is usually clinical, based on a positive family history, typical lesions (punctate hyperkeratotic papules), typical locations (palms and soles), and typical course (increase in size and number of lesions with time). Dermoscopy may reveal yellow-gray crater-like hyperkeratotic papules on the palms and soles.

Differential Diagnosis

PPKP1 should be differentiated from verruca vulgaris, callosities, porokeratosis, aquagenic palmar keratoderma, hereditary papulotranslucent acrokeratoderma, punctate keratosis of palmar creases, and arsenical keratosis.

Typically, verruca vulgaris presents as a painless, well-circumscribed, papule with a verrucous surface. Sites of predilection include the fingers, dorsum surfaces of hands, toes, elbows, and knees. The lesion is usually yellow or flesh-colored. Tiny black dots may be visible at the surface of the lesion. These black dots represent thrombosed, dilated capillaries. Trimming the surface keratin makes the capillaries more prominent.

A callus or callosity refers to a diffuse thickening of the stratum corneum in response to repeated or chronic friction or pressure. Clinically, a callus presents as a yellow plaque of hyperkeratotic tissue over an area that is subjected to friction, trauma, or pressure. The plantar surface of the metatarsophalangeal joints is particularly susceptible. A callus is a broad-based, superficial lesion with poorly demarcated borders. Paring of a callus reveals layers of yellowish keratin.

Porokeratosis is a disorder of keratinization characterized clinically by centrifugally enlarging macules or patches with central atrophy and raised hyperkeratotic borders.

Aquagenic palmar keratoderma is characterized by transient appearance of translucent white papules or plaques on the palms shortly after brief exposure to water and disappears after drying within minutes to an hour [13]. The diagnostic “hand-in-the bucket” sign refers to the fact that the skin changes are not or barely visible until the hand is submerged in water.

Hereditary papulotranslucent acrokeratoderma, an autosomal dominant inherited disorder, typically presents with bilateral, symmetric, asymptomatic yellow-white translucent papules mainly along the margins and pressure points of the hands and feet. Although papules and plaques occur without water exposure, increased prominence of papules with water exposure is typical.

In punctate keratosis of palmar creases, the lesions are confined to palmar creases. The condition is most common in black patients.

Arsenical keratosis typically present as punctate, hyperkeratotic, hard, heaped-up papules often at sites subject to friction or trauma. The papules, when removed, do not leave behind pits [7]. A history of environmental exposure to arsenic is helpful in the diagnosis.

Complications

PPKP1 can be painful and socially debilitating. It may have an adverse effect on the quality of life. Rarely, affected patients may develop squamous cell carcinoma, Hodgkin disease, breast cancer, lung cancer, prostatic carcinoma, renal carcinoma, and colonic adenocarcinoma [4,9].

Prognosis

PPKP1 tends to run a chronic course with a progressive increase in size and number of lesions with time. Spontaneous remissions are unusual [6].

Management

Treatment may not be necessary for asymptomatic lesions other than reassurance of the benign nature of the condition and watchful observation. For those patients who prefer treatment, treatment options include topical keratolytics (e.g., salicylic acid, lactic acid, propylene glycol, urea), topical retinoids (e.g., tretinoin), systemic retinoids (e.g., acitretin, alitretinoin), and surgery (e.g., mechanical debridement, excision) [5,9,10]. Treatment should be individualized,

taking into consideration the age of the patient, extent of the lesions, response to previous treatment, preference of the patient, and adverse effect of the medication.

References

1. Eytan O, Sarig O, Israeli S, Mevorah B, Basel-Vanagaite L. A novel splice-site mutation in the AAGAB gene segregates with hereditary punctate palmoplantar keratoderma and congenital dysplasia of the hip in a large family. *Clin Exp Dermatol*. 2014; 39: 182-186.
2. Buschke A, Fischer W. Keratoderma maculosa dissiminata symmetrica et plantaris. *Ikonographia Dermatologica*. 1910; 5: 183-192.
3. Brauer A. Über eine besondere Form des hereditären Keratoms (keratoderma disseminatum hereditarium palmare et plantare). *Arch Dermatol Syph*. 1913; 114: 211-236.
4. Guo BR, Zhang X, Chen G, Zhang JG, Sun LD. Exome sequencing identifies a COL14A1 mutation in a large Chinese pedigree with punctate palmoplantar keratoderma. *J Med Genet*. 2012; 49: 563-568.
5. Zur R, Shapero H, Shapero J. Dermacase. Can you identify this condition? Punctate palmoplantar keratoderma. *Can Fam Physician*. 2013; 59: 748, 752.
6. Erkek E, Ayva S. Wood's light excites white fluorescence of type I hereditary punctate keratoderma. *J Eur Acad Dermatol Venereol*. 2007; 21: 993-994.
7. Gupta R, Mehta S, Pandhi D, Singal A. Hereditary Punctate Palmoplantar Keratoderma (PPK) (Brauer-Buschke-Fischer Syndrome). *J Dermatol*. 2004; 31: 398-402.
8. Li M, Dai X, Cheng R, Yang L, Yao Z. A novel 5-bp deletion mutation in AAGAB gene in a Chinese family with punctate palmoplantar keratoderma. *Acta Derm Venereol*. 2014; 94: 339-340.
9. Furniss M, Higgins CA, Martinez-Mir A, Horev L, Petukhova L. Identification of distinct mutations in AAGAB in families with type 1 punctate palmoplantar keratoderma. *J Invest Dermatol*. 2014; 134: 1749-1752.
10. Nomura T, Yoneta A, Pohler E, Suzuki S, Osawa R. Punctate palmoplantar keratoderma type 1: a novel AAGAB mutation and efficacy of etretinate. *Acta Derm Venereol*. 2015; 95: 110-111.
11. Al-Mutairi N, Joshi A, Nour-Eldin O. Punctate palmoplantar keratoderma (Buschke-Fischer-Brauer disease) with psoriasis: a rare association showing excellent response to acitretin. *J Drugs Dermatol*. 2005; 4: 627-634.
12. Moore MM, Orlow SJ, Kamino H, Wang N, Schaffer JV. Cole disease: guttate hypopigmentation and punctate palmoplantar keratoderma. *Arch Dermatol*. 2009; 145: 495-497.
13. Leung AK, Barankin B. Aquagenic palmar keratoderma. *Pediatr Rev*. [in press].