

# Déjerine-Roussy-Like Syndrome in a Patient with an Ischemic Lesion of the Right Dorsal Protuberance: A Different Cause of Central Neuropathic Pain

Alvarez-Perez FJ\*

*Department of Medicine, Health Sciences Research Center, Beira Interior University, Covilha, Portugal*

## Article Information

Received date: Feb 29, 2016

Accepted date: Mar 28, 2016

Published date: Mar 29, 2016

### \*Corresponding author

Alvarez-Perez FJ, Department of Medicine, Health Sciences Research Center, Beira Interior University, Covilha, Portugal, Email: franciscoplus@hotmail.com

Distributed under Creative Commons CC-BY 4.0

## Abstract

**Background:** The thalamic syndrome was described in 1906 by Déjerine and Roussy. It is characterized by transient hemiparesis, hemianaesthesia, allodynia, mild hemiataxia and severe pain on the affected side. The syndrome is related to lesions in the posterior nuclei of the thalamus, usually of vascular aetiology. The aim of this work is to report a patient with a central pain Déjerine-Roussy-like syndrome due to an ischemic lesion in the dorsal pons.

**Case report:** A 69-year-old hypertense male was admitted in May 2015 with mild left hemiparesis and hemihypoesthesia. The brain Computed Tomography (CT) scan showed a small hypodense lesion in the tegmentum of the right hemipons. Seven months later, the patient was admitted again due to intense painful paresthesias on the left side of the body, including the face. A new brain CT scan showed the same pontine infarct. The patient was successfully treated with pregabalin (75 mg twice a day).

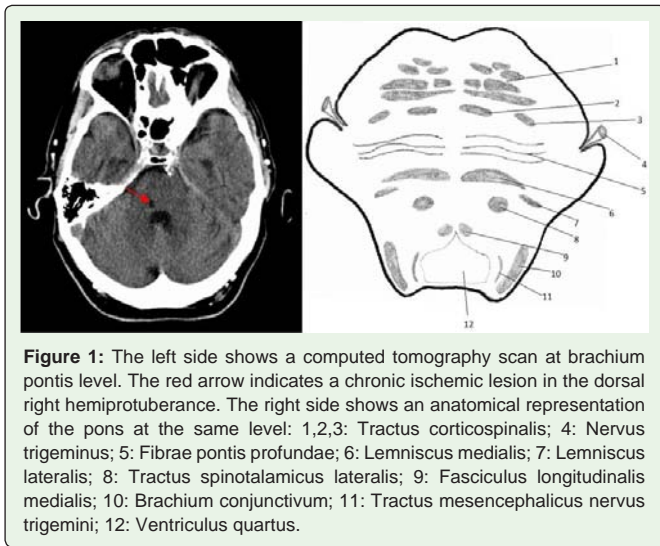
**Discussion:** The reported patient presented a Déjerine-Roussy like syndrome with a pontine topography of the vascular lesion. It is probable that the ischemic damage partially affected the medial lemniscus and the lateral spinothalamic tract. The diagnosis of the central neuropathic pain is fundamental to select the most adequate treatment.

## Background

In 1906 Déjerine and Roussy described the thalamic syndrome. This syndrome is characterized by transient mild hemiparesis, superficial hemianaesthesia (which can be replaced by cutaneous hyperaesthesia and is always accompanied by persistent disturbances of deep sensation), allodynia, mild hemiataxia, astereognosia, severe and paroxysmal pain on the hemiparetic side, and choreoathetoid movements in the limbs on the paralyzed side. The sensory disorder involves both superficial (touch, pain and temperature) and deep (position, vibration) modalities and is associated with a sensation of pain on the affected side which may start a few months after the first clinical manifestations. The pain is continuous, with paroxysmal exacerbations, and it is not suppressed by conventional analgesic treatment. The Déjerine-Roussy syndrome is caused by lesions in the posterior nuclei of the thalamus, which usually have a vascular aetiology [1,2]. The aim of this work is to report a case of a patient with a Déjerine-Roussy like syndrome secondary to an ischemic lesion in the dorsal pons.

## Case Report

A 69-year-old hypertense male was admitted in the Stroke Unit in May 2015 with a left side mild hemiparesis and hemihypoesthesia affecting all sensory modalities. Both deficits spared the face and the patient had no cranial nerve disturbances or cognitive impairment. The brain Computed Tomography (CT) scan performed 24 hours after clinical onset showed a small hypodense lesion in the tegmentum of the right hemipons. Figure 1 represents the CT scan and its anatomic correlation [3]. The patient underwent an exhaustive study to determine the aetiology of stroke, including transthoracic echocardiography, Holter-electrocardiography, transcranial Doppler, and carotid ultrasound. These tests showed non-specific findings and the patient was treated with antihypertensive drugs and aspirine as secondary prevention. After seven months, the patient was admitted again due to intense painful paresthesias on the left side of the body, including the homolateral hemiface. The examination of cognitive functions, cranial nerves, muscle strength and coordination was normal. As in the previous examination, the testing of sensibility showed hypoesthesia (affecting all modalities) and allodynia on the left side of body and the left extremities, but the sensory examination of the face was normal. A new brain CT scan showed the same small lacunar lesion in the dorsal right hemipons. After the diagnosis of central pain the patient was treated with 25 mg of pregabalin, twice a day. Because the response was partial and the tolerability was



**Figure 1:** The left side shows a computed tomography scan at brachium pontis level. The red arrow indicates a chronic ischemic lesion in the dorsal right hemipons. The right side shows an anatomical representation of the pons at the same level: 1,2,3: Tractus corticospinalis; 4: Nervus trigeminus; 5: Fibrae pontis profundae; 6: Lemniscus medialis; 7: Lemniscus lateralis; 8: Tractus spinothalamicus lateralis; 9: Fasciculus longitudinalis medialis; 10: Brachium conjunctivum; 11: Tractus mesencephalicus nervus trigemini; 12: Ventriculus quartus.

excellent, the dose of the drug was raised to 50 mg/12 hours on the second day and to 75 mg/12 hours on the third day. On discharge the patient presented only mild painless paresthesias and short periods of drowsiness after the administration of the antiepileptic drug.

## Discussion

The Déjerine-Roussy syndrome is related to lesions in the posterior thalamic nuclei. Since its first description, several cases have been reported to remark definite clinical characteristics of the patients [4,5] or the positive response to specific treatments, like combinations of antiepileptic drugs or deep brain stimulation [6,7]. The patient reported in this paper presented a Déjerine-Roussy like syndrome which had 3 main differences in relation to the classically described. First, the topography of the vascular lesion was pontine and not thalamic. The damage was located in the dorsal right hemipons and affected partially the medial lemniscus and the lateral spinothalamic tract, but respected the trigeminal nucleus and the trigeminal lemniscus. The preservation of the trigeminal pathways explains that the patient had all sensory modalities impaired on the left side of the body but not on the face. Secondly, the patient had no severe motor weakness or hemiataxia during acute phase of stroke. This finding may be explained by the incomplete damage of the proprioceptive pathway and the preservation of the corticospinal tract, which is

located more ventrally in the protuberance. Thirdly, the patient had a relatively moderate neuropathic pain syndrome, which was well controlled with a medium dose of pregabalin. It is possible that the nuclear thalamic damage, as described in the classical Déjerine-Roussy syndrome, causes more intense symptoms than a lesion in the afferent tract to thalamus (medial lemniscus). Because the lesion is located in the lemniscus, the posterior nuclei are preserved and they probably have a reduction of their functional activity only. Indeed, fibrosis in the medial lemniscus may cause abnormal afferent activity which may contribute to a milder painful disorder. The topographical representation of the complete left hemibody and hemiface in the right thalamus may explain that the neuropathic pain affects both contralateral hemibody and hemiface without objective hypoesthesia in the face. Probably, this is due to the sparing of trigeminal nucleus and trigemino-thalamic pathways in the pons.

## Conclusion

The reported patient presents a partial form of Déjerine-Roussy syndrome related to an ischemic lesion in a different topography of the one described in the classical syndrome. The correct diagnosis of the central neuropathic painful syndrome and the knowledge of the different topographies which may cause this disorder are fundamental to select the most adequate treatment for the affected patients.

## References

1. Déjerine J, Roussy G. Le syndrome thalamique. *Rev Neurol (Paris)*. 1906; 14: 521-532.
2. Pearce JM. The thalamic syndrome of Déjerine and Roussy. *J Neurosurg Psychiatry*. 1988; 51: 676.
3. Villiger E, Ludwig E, Rasmussen AT. Atlas of cross section anatomy of the brain. Mc Graw-Hill, New York. 1951.
4. Cosme CDLA, Martínez MM, Cueto OH, Bailón IR, Pérez JAH, Acebal MR. Déjerine-Roussy syndrome of an ischaemic origin in an adolescent with patent foramen ovale. *Rev Neurol*. 2009; 49: 21-24.
5. Kumral E, Celebisoy N. Visually evoked hyperpathia due to thalamic hemorrhage: a variant of Déjerine-Roussy syndrome. *Stroke*. 1996; 27: 774-775.
6. Ramachandran VS, McGeoch PD, Williams L. Can vestibular caloric stimulation be used to treat Déjerine-Roussy Syndrome? *Med Hypotheses*. 2007; 69: 486-488.
7. Alves RV, Asfora WT. Deep brain stimulation for Déjerine-Roussy syndrome: case report. *Minim Invasive Neurosurg*. 2011; 54: 183-186.