

Acrokeratosis Verruciformis of Hopf Associated With Epidermolytic Hyperkeratosis - A Rare Case Report

R.G.Sharada¹ and Jayakar Thomas^{1*}

¹Department of Dermatology, Sree Balaji Medical College & Bharath University, Chennai 600044, India

Article Information

Received date: Nov 05, 2016

Accepted date: Jan 05, 2017

Published date: Jan 13, 2017

***Corresponding author**

Jayakar Thomas, Department of Dermatology, Sree Balaji Medical College & Bharath University, Chennai 600044, India, Email: jayakarthomas@gmail.com

Distributed under Creative Commons CC-BY 4.0

Keywords Jayakar Thomas, Department of Dermatology, Sree Balaji Medical College & Bharath University, Chennai 600044, India, Email: jayakarthomas@gmail.com

Abstract

Acrokeratosis verruciformis of Hopf is a rare genetic disorder with autosomal dominant inheritance. It is characterized by the presence of multiple lightly pigmented or flesh colored papules on the dorsum of the hands, feet, knees and elbows. Lesions consistent with acrokeratosis verruciformis are been associated with Hailey-Hailey, hypertrophic lichen planus, naevoid basal cell carcinoma, multiple keratoacanthoma. We report a case of acrokeratosis verruciformis in a 65 years old patient who came with complaints of itchy skin lesions over both the legs and dorsum of the right hand for the past 2 years and histologically with features of epidermolytic hyperkeratosis.

Introduction

Acrokeratosis verruciformis was first described by Hopf in the year 1931. It usually presents at birth or in early childhood; onset can however be delayed till fifth decade of life. It affects both the sexes but males are affected than females with a ratio of 5:1.3. Clinically, it presents as multiple, small, flat, skin colored warty papules resembling plane warts typically located in dorsum of hands and feet. The lesions may present as finely granular to lichenified polygonal papules.

Case Report

A 65 years old man presented to our OPD with complaints of itchy skin lesions over both the legs and right hand for the past 2 years. There was no history of fluid filled lesions. There was no history of dental caries. No history of fever, jaundice. There was no history of drug intake prior to the onset of lesions. There was no history of seasonal variation. No history of loss of weight or appetite. There was no history of similar complaints in the family.

Dermatological examination revealed multiple, pigmented, verrucous papules and plaques present over the extensor aspect of the right leg (Figure 1) and dorsum of the right hand (Figure 2). Multiple pits were present over the both the palms (Figure 3). Scalp, oral mucosa, soles, nail and

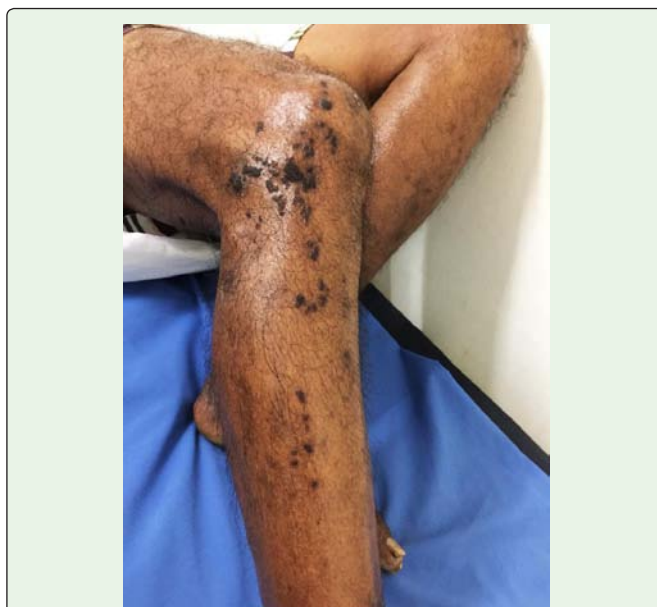

Figure 1: Clinical photograph showing multiple, pigmented, verrucous papules and plaques present over the extensor aspect of the right leg.

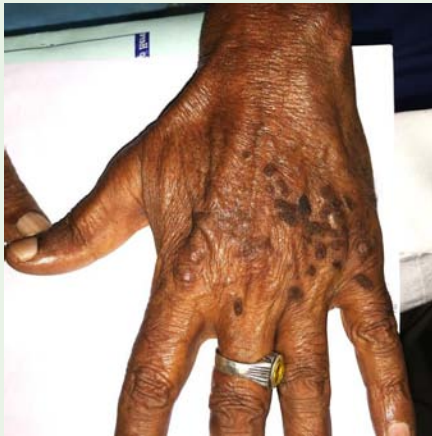

Figure 2: Clinical photograph showing multiple, pigmented, verrucous papules present over the dorsum of the right hand.

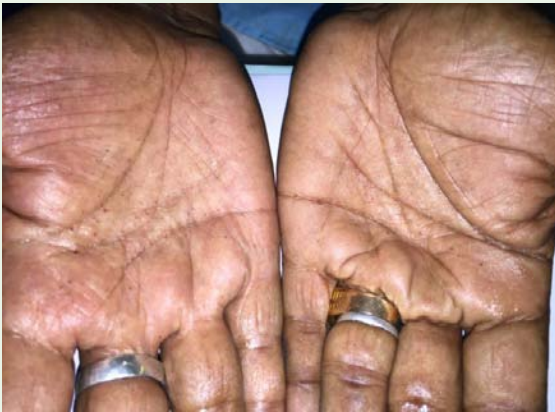

Figure 3: Clinical photograph showing multiple pits present over the palms.

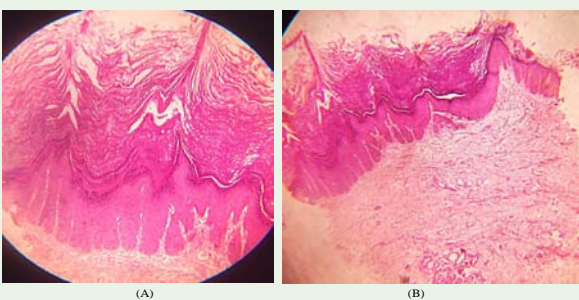


Figure 4: Haematoxylin and eosin (H&E) section of the skin photograph showing hyperkeratotic, papillomatous epidermis with a church spire appearance overlying fibrocollagenous dermis. There is prominence of the granular layer and focal basal cell vacuolar degeneration. Superficial dermis shows moderate lymphocytic infiltration. A. (Magnification x 40) and B. (Magnification x 10).

genitalia were normal. Systemic examination was normal. Complete blood counts done were normal. X ray of both the hands was normal. Ultrasound of the abdomen done was normal. Two skin biopsies taken from the right leg and from the pits showed hyperkeratotic, papillomatous epidermis with a church spire appearance overlying fibrocollagenous dermis. There is prominence of the granular layer

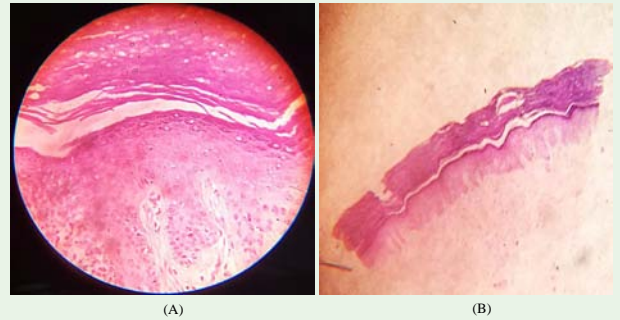


Figure 5: Haematoxylin and eosin (H&E) section of the skin photograph showing epidermolytic hyperkeratosis. A. (Magnification x 40) and B. (Magnification x 10).

and focal basal cell vacuolar degeneration. Superficial dermis shows moderate lymphocytic infiltration (Figure 4). Biopsy taken from the pits showed features of epidermolytic hyperkeratosis (Figure 5).

Discussion

Acrokeratosis verruciformis of Hopf is a rare autosomal dominant disorder which shares some of the features of the acral variety of Darier’s disease. It may appear spontaneously or be inherited in an autosomal dominant pattern. The causative mutation implicated in Darier’s disease is in the gene ATP2A2 [1] which encodes for SERCA2 [i.e. sarco-endoplasmic reticulum Ca^{2+} ATPase, an intracellular calcium pump which replenishes endoplasmic reticulum Ca^{2+}] has also been found in Acrokeratosis verruciformis. It is better to view acrokeratosis verruciformis as an independent disorder, than considering the two diseases as a single dominant defect with variable expressivity [2].

Clinically, this condition is characterized by hyperkeratotic, flesh colored, flat verrucous papules occurring on the dorsum of hands, feet, extensor aspect of forearms, lower legs, wrists and face [3]. The papules may either be discrete or in small groups, usually sparing the scalp, forehead, oral mucosa and flexures. Friction may cause blistering of papules. Palmar and nail involvement may suggest the diagnosis of Darier’s disease, even in the absence of rash in seborrhoeic areas. Pits and punctate keratosis interrupting the dermal ridges are seen in palms and soles [4]. Splitting, subungual hyperkeratosis and longitudinal striations are seen in nail involvement [5]. The skin lesions remain throughout the lifetime, but can progress in number and size with prolonged exposure to sun. The complications that are likely to occur are squamous cell carcinoma [6] and rarely dilated cardiomyopathy [7].

The term epidermolytic hyperkeratosis described by Ackerman [8] is characterized by compact hyperkeratosis, hypergranulosis, and presence of keratohyaline granules in the granular layer and perinuclear halo. It is seen in variety of disorders such as ichthyosis bullosa of Siemens [9], linear epidermal naevus [10], solar keratosis [11], melanocytic nevus [12], progressive systemic sclerosis [13], squamous and basal cell carcinoma [14] and nevus comedonicus [15].

The diagnosis of acrokeratosis verruciformis is made from tissue biopsy. Histopathological examination reveals hyperkeratosis, prominent granular layer, acanthosis and papillomatosis, which are frequently accompanied by circumscribed pointed elevations of

epidermis which resemble church spire. Slight elongation of the rete ridges may also be seen. This condition is distinguished from Darier's disease by the absence of suprabasal clefts.

Lesions of acrokeratosis verruciformis has been reported to be in association with nevoid basal cell carcinoma syndrome, steatocystoma multiplex, Hailey-Hailey disease, multiple keratoacanthomas, hypertrophic lichen planus and congenital poikiloderma [16].

The differential diagnosis such as plane warts, seborrheic keratosis, epidermodysplasia verruciformis can be distinguished from acrokeratosis histologically, while hard nevus of Unna can be differentiated clinically.

The most effective treatment for acrokeratosis verruciformis is superficial ablation. Topical application of retinoic acid, cryotherapy with liquid nitrogen or usage of destructive lasers such as Nd: YAG or CO₂ lasers [17].

This case is reported because of its rare association with epidermolytic hyperkeratosis.

References

- Dhitavat J, Macfarlane S, Dode L, Leslie N, Sakuntabhai A, MacSween R, et al. Acrokeratosis verruciformis of Hopf is caused by Mutation in ATP2A2: Evidence that it is Allelic to Darier's Disease. *J Invest Dermatol*. 2003; 120: 229-232.
- Johnson BL, Yan AC. Congenital diseases (Genodermatoses). *Lever's histopathology of skin*, 10th edition. 2009; Chapter 6: 152.
- Patel N, Diwan N, Nair PA. Non familial acrokeratosis verruciformis of Hopf. *Indian Dermatol Online J*. 2015; 62: 110-112.
- Hovnanian A. Acantholytic disorders of skin: Darier white disease, Acrokeratosis verruciformis, Grover's disease and Hailey-Hailey disease. *Fitzpatrick's dermatology in medicine* 7th edition, chapter 49(436).
- Rallis E, Economidi A, Papadakis P, Verros C. Acrokeratosis verruciformis of Hopf (Hopf disease): case report and review of the literature. *Dermatol Online J*. 2005; 11:10.
- Dogliotti M, Schmaman A. Acrokeratosis verruciformis: Malignant transformation. *Dermatologica*. 1971; 143: 95-99.
- Kaliyadan F, Manoj J, Venkitakrishnan S. Acrokeratosis verruciformis of Hopf associated with dilated cardiomyopathy. *Indian J Dermatol*. 2009; 54: 296-297.
- Ackerman AB. Histopathologic concept of epidermolytic hyperkeratosis. *Arch Dermatol*. 1970; 102: 253-259.
- Traupe H, Kolde G, Hamm H, Happle R. Ichthyosis bullosa of Siemens: a unique type of epidermolytic hyperkeratosis. *J Am Acad Dermatol*. 1986; 14: 1000-1005.
- Sarifakioglu E, Yenidunya S. Linear epidermolytic verrucous epidermal nevus of the male genitalia. *Pediatr Dermatol*. 2007; 24: 447-448.
- Ackerman AB, Reed RJ. Epidermolytic variant of solar keratosis. *Arch Dermatol*. 1973; 107: 104-106.
- Conlin PA, Rapini RP. Epidermolytic hyperkeratosis associated with melanocytic nevi: a report of 53 cases. *Am J Dermatopathol*. 2002; 24: 23-25.
- Sasaki T, Nakajima H. Incidental epidermolytic hyperkeratosis in progressive systemic sclerosis. *J Dermatol*. 1993; 20: 178-179.
- González SB. Epidermolytic hyperkeratosis associated with superficial basal cell carcinoma. *Arch Dermatol*. 1983; 119: 186-187.
- Barsky S, Doyle JA, Winkelmann RK. Nevus comedonicus with epidermolytic hyperkeratosis. A report of four cases. *Arch Dermatol*. 1981; 117: 86-88.
- Judge MR, McLean WHI, Munro CS. Disorders of keratinisation. *Rooks text book of Dermatology*, 8th edition, 2010; chapter 19 (19.88).
- Salman H, Osman W. Acrokeratosis verruciformis of Hopf (Hopf disease). *J Infect Dis Ther*. 2014; 2: 1.