

Presenting of Pregnant Woman with
Atrioventricular BlockTarik Kivrak^{1*}, Volkan Kivrak², Yasemin Yazar Kivrak³ and Ilgın Karaca¹¹Department of Cardiology, Firat University, Turkey²Department of Anaesthesia, Medical Park Hospital, Turkey³Department of Gynaecology, Kocaeli State Hospital, Turkey

Article Information

Received date: Aug 02, 2017

Accepted date: Aug 18, 2017

Published date: Aug 22, 2017

*Corresponding author

Tarik Kivrak, Department of Cardiology,
Firat University, Turkey,
Tel: +9005053729945;
Email: tarikivrak@gmail.com

Distributed under Creative Commons
CC-BY 4.0

Keywords Atrioventricular block;
Pregnancy; Pacemaker

Abstract

Atrioventricular Block (AVB) during pregnancy is a rare disease that a disorder of the cardiac conduction system. AVB could be asymptomatic. It is typical of permanent bradycardia and may cause to weakness, dizziness, dyspnea, syncope or heartfailure. Patient with AVB must evaluate with somenon-invasive techniques such as transthoracic echocardiography, treadmill test, and holter monitorization because of determining the prognosis of the disease. The reareno established guidelines for clinical management of the AVB in pregnancy. Although it is asymptomatic if a patient with AVB has complaints such as recurrent syncope and heartfailure, permanent pacemaker recommend. In ourcase, we presented pregnant women with AVB that was not need a permanent pacemaker.

Introduction

AVB during pregnancy is a rare disease; its incidence is 1/20000 [1]. There is mostly sporadic transition but can rarely be seen the familial transition. It has a high risk of mortality and morbidity. Morguio described it in 1901 [2]. The disease may be considered in the normal heart as well as with the structural heartdisease. It can be seen more often with atrioventricular septal defect, left atrialisomerism, atrioventricular canal defect and total return anomaly [3]. It can be seen with neonatal lupus [4]. The mortality rate of patients with congenital AVB is 30%; the permanent heart rate requirement is 67% in these patients [5].

Case Presentation

Our patient was 27 years old, had no complaint. There was no feature in resume and family history. She has been followed by bradycardia for three years. Heart rate was 42/min, and blood pressure was 135/75 mmHg. The patient's cardiac examination was normal. Heart rate was 34/min in her electrocardiography, and it had a second-degree atrioventricular block (Figure1). LVEF was 65%, and function of the valve was normal. Maximal heart rate was 55/min, minimum was 32/min, and average heart rate was 45/min in her Holter ECG. There was no distinct pathology in laboratory results. However, anti-Ro-La antibody and Borrelia serology were negative. We thought it might be CAVB. The patient was fitted with a temporary pacemaker, and the procedure was uneventful. Following 40 weeks of gestation, she delivered a healthy daughter. However, we did not need to active pacemaker during delivery.

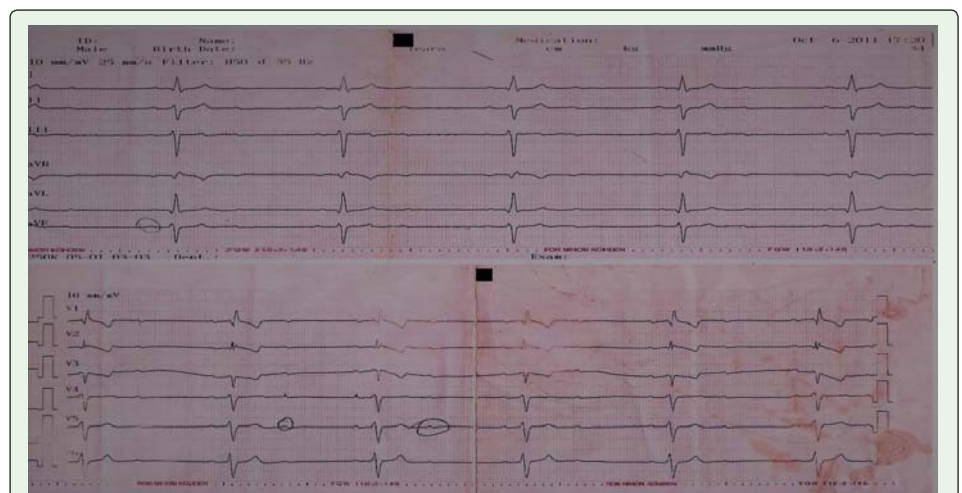


Figure 1: Electrocardiography of Pregnant Patient.

Discussion

The finding of AVB is rare in pregnancy. If present, it is generally pertained to a congenital heart block; in fact, 30% of the cases of congenital complete heart block survive unexplored until adulthood and may, therefore, present during pregnancy [6]. The bradyarrhythmia was very likely based on an acquired atrioventricular block, although progression of pre-existing low-grade or congenital intermittent block can not be entirely excluded in our patient. Since no data of the patient's heart rate between the previous pregnancy and the current presentation were available, we can not draw definite conclusions regarding a causal relationship between the pregnancy and the conduction disturbance; it is possible that the complete AV block became clinically evince during pregnancy because of altered hemodynamics. Acquired AV conduction blocks can be referred to ischaemic heart disease, to fibrosis and sclerosis of the conduction system, the use of negative chronotropic drugs, valvular disease, increased vagal tone, cardiomyopathies, electrolyte disturbances, congenitally corrected transposition of the great arteries, autoimmune diseases, systemic diseases such as sarcoidosis or infectious diseases such as Lyme disease [7,8]. Our patient was not taking any medication. We do not take stock ischaemic heart disease very likely given the medical history and absence of angina. Laboratory examinations were normal, including electrolytes, Borrelia serology and thyroid-stimulating hormone. Transthoracic ultrasonography showed a structurally normal heart, virtually excluding any cardiomyopathy. As well as valvular disease and congenitally corrected transposition of the great arteries. We were not able to offer an explanation for the conduction disturbance in our patient. Once high-degree AV block is seen in pregnancy term, it is hard to constitute the requirement of implanting a pacemaker in asymptomatic patients [9]. Hidaka et al. showed in six asymptomatic patients with complete atrioventricular conduction block and structurally normal hearts that artificial cardiac pacing. However, our patient suffered from fatigue, and although there were no syncope, we judged her symptoms to be pertained to the conduction disturbance and decided to implant a dual chamber pacemaker. Pacemaker can be done safely during pregnancy [10,11]. Succeeding the procedure, our patient felt much better. Both the remaining gestation period and delivery were uneventful. AVB may be asymptomatic and may present with various symptoms such as weakness, dizziness, exercise intolerance and heartfailure. ECG finding of AVB can give information about the process of disease. Especially if QT interval is over 450 msn, sudden cardiac death is more visible in these patients [12]. The exercise test is necessary for risk assessment, 90% of patients without structural heart disease are usually detectable. 50-70% of patients can detect ventricular ectopic, but it is not associated with mortality. However, if target heart rate is below 125/min, it should be considered as risk for sudden cardiac death and permanent pacemaker [13]. It has been shown that the

risk of syncope and sudden cardiac death increased in patients have below 50/min [14]. They are mostly asymptomatic, but in some cases, permanent heart pills are required. In Vukomanovic et al, if there are congestive heartfailure, recurrent fainting, effort dyspnea, fatigue, ectopic ventricular and supraventricular beats in the effort test, mitral insufficiency, a permanent pacemaker may be required in pregnant women [15]. Permanent cardiac pacing is not recommended for protection in asymptomatic patients, but it is recommended for treatment in first and second trimester in symptomatic patients.

References

1. Michaelsson M, Engle MA. Congenital complete heart block: an international study of the natural history. *Cardiovasc Clin.* 1972; 4: 85-98.
2. Morquio L. Sur Une maladies infantile et familial caractérisée et la Portesuite. *Arch Med Enfants.* 1901; 4: 467.
3. Jaeggi ET, Hornberger LK, Smallhorn JF, Fouron JC. Prenatal diagnosis of complete A-V associated with structural heart disease. *Ultrasound Obstet Gynecol.* 2005; 26: 16-21.
4. Laxor RM, Roberts EA, Gross KR, Britton JR, Cutz E, Dimmick J, et al. Liver disease in neonatal lupus erythematosus. *J Pediatr.* 1990;116: 238-242.
5. Waltuck J, Buyon JP. Autoantibody-associated congenital heart block: outcome in mothers and children. *Ann Intern Med.* 1994; 120: 544-551.
6. Reid J, Coleman E, Doig W. Complete congenital heart block. Report of 35 cases. *Br Heart J.* 1982; 42: 236-239.
7. Zoob M, Smith KS. Aetiology of Complete Heart-block. *Br Med J.* 1963; 2: 1149-1153.
8. Mukherji J, DiGrazia J, Galetta D, Vetrovec GW. Lyme carditis. Severe conduction disorder. *Mo Med.* 1990; 87: 86-88.
9. Dalvi B, Chaudhuri A, Kulkarni HL, Kale PA. Therapeutic guidelines for congenital complete heart block are presenting in pregnancy. *Obstet Gynecol.* 1992; 79: 802-804.
10. Sharma J, Malhotra M, Pundir P. Successful pregnancy outcome with a cardiac pacemaker after complete heart block. *Int J Gynecol Obstet.* 2000; 68: 145-146.
11. Ginns HM, Hollinrake K. Complete heart block in pregnancy treated with an internal cardiac pacemaker. *J Obstet Gynaecol Br Commonw.* 1970; 77: 710-712.
12. Esscher EB. Congenital complete heart block in adolescence and adult life: a follow-up study. *Eur Heart J.* 1981; 2: 281-288.
13. Gobeil F, Labbe AC, LePage S. Congenital complete atrioventricular block: asymptomatic at 38 years. *Can J Cardiol.* 1996; 12: 297-299.
14. Kertesz NJ, Fenrich AL, Friedman RA. Congenital complete atrioventricular block. *Tex Heart Inst J.* 1997; 24: 301-307.
15. Vukomanovic V, Stajevic M, Kosutic J, Stojanov P, Rakic S, Velinovic M, et al. Age-related role of ambulatory electro cardiographic monitoring in risk stratification of patients with the complete congenital atrioventricular block. *Europace.* 2007; 9: 88-93.