

# Total Laparoscopic Anterior Resection and L/Adrenalectomy for Rectal Adenocarcinoma with Concurrent Adrenal Adenoma Mimicking Metastasis: Decision Making Process in an Unusual Case and Brief Review of Literature

Duminda Subasinghe<sup>1\*</sup>, Sonali Gunatilake<sup>2</sup>, Suchintha Tilakarathana<sup>1</sup>, Amarabandu PN<sup>3</sup> and Amal Priyantha TG<sup>4</sup>

<sup>1</sup>Senior Registrar in Gastrointestinal Surgery, Gastrointestinal Surgical Unit, Colombo South Teaching Hospital, Sri Lanka

<sup>2</sup>Senior Registrar in Endocrinology, Endocrinology Unit, Colombo South Teaching Hospital, Sri Lanka

<sup>3</sup>Consultant Pathologist, Department of Pathology, Colombo South Teaching Hospital, Sri Lanka

<sup>4</sup>Senior Consultant Gastrointestinal Surgeon, Gastrointestinal Surgical Unit, Colombo South Teaching Hospital, Sri Lanka

## Article Information

Received date: Jan 23, 2018

Accepted date: Feb 05, 2018

Published date: Feb 09, 2018

### \*Corresponding author

Duminda Subasinghe, Senior Registrar in Gastrointestinal Surgery, Gastrointestinal Surgical Unit, Colombo South Teaching Hospital, Colombo, Sri Lanka, Tel: 094716862656; Email: dumindas1982@yahoo.com

**Distributed under** Creative Commons CC-BY 4.0

**Keywords** Colorectal; Adrenal metastasis; Laparoscopic anterior resection

## Abstract

The most common sites of metastasis of the Colorectal Cancer (CRC) are liver and lung. Though Adrenal metastasis is a relatively frequent finding during autopsy, clinically significant adrenal metastasis is rare. Adrenal adenoma mimicking colorectal metastasis is extremely rare and poses significant challenge in the diagnosis. Simultaneous adrenal adenoma mimicking colorectal metastasis and colorectal carcinoma has not been described in literature. We describe a 62-year-old Sri Lankan male with adenocarcinoma of recto-sigmoid junction and a solitary lesion in the left adrenal gland which was found incidentally on Computed tomography. Since the possibility of an adrenal metastasis could not be ruled out he underwent total laparoscopic anterior resection and left adrenalectomy. His histology revealed an adenocarcinoma of upper rectum with L/adrenal cortical adenoma. A review in the literature showed that synchronous solitary adrenal adenoma with atypical features suggesting a metastasis coexisting with colorectal carcinoma is very rare.

## Introduction

Incidentally found tumors of the adrenal gland (incidentalomas) are found in 0.4-4.4% of all abdominal CT scans and the prevalence in autopsy series is about 1.4-8.7% [1,2]. The reported incidence of adrenal lesions in patients with history of malignancy is 0.6-4.4% [3]. In non-oncological population benign adrenal adenoma represent 36 to 94% of incidentalomas whereas 2.5% of them are due to metastatic deposits. Patients with extra adrenal malignancy, reported rate of adrenal metastases vary between 25% to 72% depending on the size and type of the primary tumor [4-6]. The adrenal metastases are mostly from malignancies of lung, breast and kidney. Incidence of adrenal metastases from colorectal malignant lesion ranges between 1.9% and 17.4% [7]. Therefore when an adrenal mass was found on imaging during the staging, possibility of a tumor metastasis has to be excluded [8]. Generally, adrenal metastasis indicates widespread disease and with poor prognosis and solitary and clinically curable adrenal metastasis from colorectal carcinoma is very rare [9]. Adrenal adenoma mimicking metastasis from colorectal cancer is a challenge since it has not been reported previously in literature. We report an unusual case of non-functioning solitary adrenal adenoma mimicking metastasis from rectal carcinoma with review of the relevant literature.

## Case Report

A 62-year-old male presented with incomplete evacuation of bowels associated with mucous stools of 1 year duration. He never had bleeding per rectum or abdominal pain. He had no features of metastatic disease related to colorectal malignancies. He was a hypertensive for 20 years which was under control with medications. There were no episodic palpitations, sweating and headache suggestive of pheochromocytoma. He had not experienced any significant muscle cramps or proximal muscle weakness. In his family there were no first or second degree relatives with a history

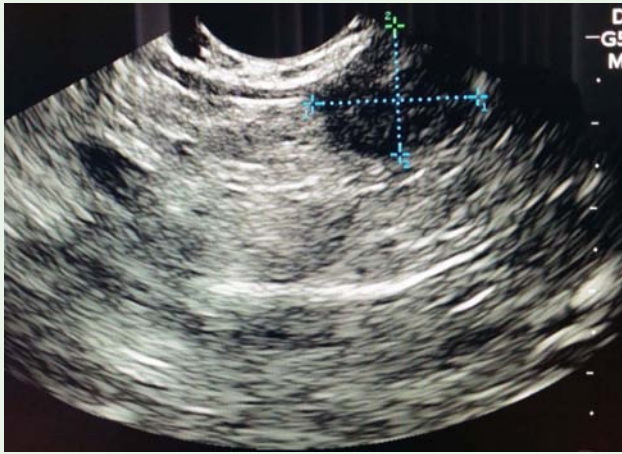


Figure 1: CECT Abdomen showing L/adrenal mass.

of colorectal malignancies. Physical examination including digital rectal examination was unremarkable. He did not have any features suggestive of Cushing’s syndrome either. Colonoscopy revealed a circumferential polypoidal growth at recto-sigmoid junction and histology revealed moderately differentiated adenocarcinoma. Serum Carcinoembryonic Antigen (CEA) level was normal (1.34 ng/mL). The initial assessment with Contrast Enhanced Computed Tomography (CECT) of the abdomen and pelvis showed rectal adenocarcinoma (T3N0M0) without any evidence of metastatic disease. However repeat assessment after neo-adjuvant therapy CECT (Figure 1) of the thorax and the abdomen revealed a (1.3 x 1.6 cm) well-defined

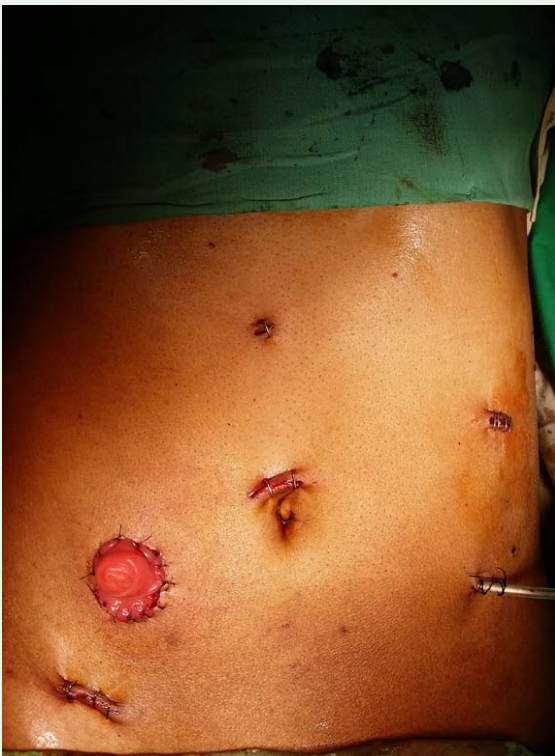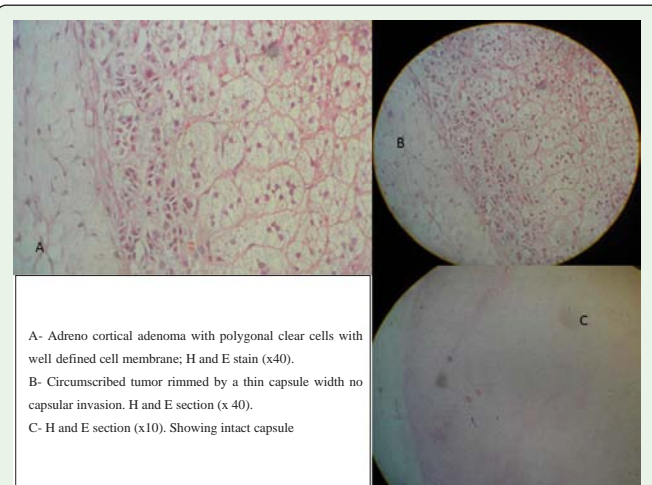


Figure 2: Endosonography showing L/adrenal mass.

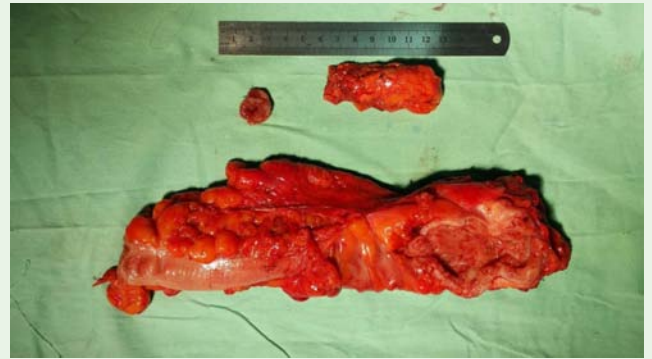

Figure 3: Patients abdomen showing Laparoscopic port sites and ileostomy.

hypodense non enhancing lesion in the L/adrenal (density of 20 HU) with suspicious imaging characteristics (without rapid washout) (Figure 1) and 3 mm lesion in the segment IV of the liver. Biochemical assessment for hormonal hyper-secretion revealed normal results for urine Vanillylmandelic Acid (VMA), overnight dexamethasone suppression test, 9 am testosterone and Aldosterone Rennin Ratio (ARR). Subsequently the lesion was assessed with Endosonography (EUS) to delineate left adrenal lesion (Figure 2) which showed a 1.5 x 2 cm solitary heterogeneous mass lesion in the left adrenal. A metastatic deposit of the left adrenal was suspected since it appeared within 4 months of the initial CECT (together with a new liver lesion) and because of the higher density and heterogeneity of the adrenal lesion on EUS examination. He underwent total laparoscopic high anterior resection with a defunctioning ileostomy and left adrenalectomy (Figure 3). His post-operative recovery was uneventful and patient was discharged on postoperative day 4. Pathological examination of the anterior resection specimen (Figure 4) revealed residual invasive adenocarcinoma of the rectum and the lymph nodes were negative for metastatic disease. His adrenal gland showed a well circumscribed lesion with a thick capsule without evidence of invasion. Tumour composed of cords and nests of polygonal cells with clear to fine granular cytoplasm suggestive of benign adrenal adenoma with a thick surrounding capsule.



A- Adreno cortical adenoma with polygonal clear cells with well defined cell membrane; H and E stain (x40).  
 B- Circumscribed tumor rimmed by a thin capsule with no capsular invasion. H and E section (x 40).  
 C- H and E section (x10). Showing intact capsule

Figure 4: Anterior resection specimen with adrenalectomy specimen and distal doughnut.

## Discussion

### Adrenal incidentaloma in a patient with extra adrenal malignancy

Adrenal incidentalomas are lesions discovered serendipitously on a radiological examination that has been performed for reasons other than suspected adrenal disease [8,10]. Detection of adrenal incidentalomas has increased owing to the wide use of advanced imaging modalities in evaluation of disease. Its incidence increase with age and therefore the probability of finding an adrenal incidentaloma in a patient between 20 and 29 years of age is 0.2%, compared to 7% in a patient over 70 years of age [9]. Although adrenal gland is a common site for metastasis, it frequently harbors benign adenomas in the general population. Among the patients with a history of extra adrenal malignancy, the prevalence of metastatic deposits in adrenal glands representing an adrenal incidentaloma is much higher than the general population (25-72% versus 2.5% respectively) [5,6]. It is also commoner than the benign primary adrenal adenomas in this group of patients. Lenert et al. [11] found that 52% of adrenal masses in 91 patients with extra-adrenal malignancy were metastatic, whereas 48% were primary adrenal lesions. Mean time for detection of adrenal metastasis in patients with a past history of malignant disease is 2.5 years. On the other hand synchronous metastatic lesions are usually associated with disseminated malignancy. They represent a major cause of anxiety for the patients and a diagnostic and management challenge for the physicians. With the background colorectal malignancy, our patient also had a higher probability of the adrenal lesion being secondary deposit. However the possibility of the lesion being a benign mass could not be completely ruled out at his age.

### Colorectal adrenal metastasis

Adrenal metastases from colorectal carcinomas are less frequent [12,13] and solitary synchronous metastasis is extremely rare. On the other hand incidence could also be underestimated because an adrenal mass can be misinterpreted as a lombo-aortic node [12]. The incidence of silent adrenal metastasis has increased because of the increased use of cross sectional abdominal imaging modalities. According to the study by Lam et al. [14] the prevalence of colorectal cancer in silent adrenal metastases in both autopsy and biopsy series was around 5% in an Asian series. Patients with adrenal metastases are usually asymptomatic especially when they are solitary and unilateral. These metastatic lesions are not easily distinguished from primary non-functional adrenal tumors either [12]. In the presence of a metastasis, serum CEA levels are usually elevated and therefore can be used for the diagnosis of an adrenal metastasis after surgery for CRC [15]. Though serum level of CEA in our patient was normal, concomitant appearance of the adrenal mass together with a new liver lesion within 4 months of the initial CT was highly suspicious of metastatic deposit of the colorectal malignancy.

### Role of imaging

The abdominal cross sectional imaging has a key role in the diagnosis of the adrenal metastases. In fact, because of improved imaging and diagnostic techniques, many adrenal metastases are now discovered on imaging [16]. CT scan allows the diagnosis of the adrenal masses with accuracy to sub-centimetric lesions.

Differentiation of benign versus malignant lesions are based on the characteristics of the lesion detected on CT. Benign adenomas usually are lipid rich as opposed to malignant lesions (Primary adrenal or metastatic), which are lipid poor. They are detected on CT/MRI based on the densities of the lesions. Lipid rich benign lesions have a lower density on CT with an attenuation value < 10 Hounsfield units (HU) which has a specificity of more than 95% and a sensitivity of nearly 80% [19]. Contrast washout values in CT are also used in lesions with higher densities where absolute contrast washout >60% and relative >40% indicate benign nature. Chemical-shift MRI identifies benign adenomas by different resonance frequency peaks for the hydrogen atom in water and lipid molecules. It has a sensitivity of 89% for differentiating benign and malignant lesions, with 99% specificity [20]. PET-CT scanning has a 95-100% sensitivity and 80-100% specificity in detecting benign versus malignant lesions of the adrenal gland [21-23].

### Biopsy of adrenal lesions

Although CT/ MRI features can differentiate benign and malignant lesions of the adrenal gland, histological confirmation is needed in patients with history of extra adrenal malignancy especially in the absence of other metastatic lesions. It has a positive predictive value of 100% and a negative predictive value for malignancy of 92% [24,25]. It should be established that the lesion is non secretory, especially not a pheochromocytoma by hormonal evaluation prior to attempting the biopsy to minimize the adverse complications. Although the cytology has a high accuracy (>90%), in differentiating adenoma from metastasis the histologic distinction between benign adenoma and primary adrenal carcinoma is difficult (sensitivity of 54 -86%) [15]. A study done by Martinez et al. showed that EUS and biopsy had 9.5% non-diagnostic biopsies and 11% of the benign lesions. EUS-biopsy had revealed malignancy on follow-up among a patient cohort of 94, with a sensitivity of 86% and a specificity of 97% [26]. Several other studies revealed similar findings with the lowest specificity of 43% reported by Bodtger et al. [27].

EUS guided fine-needle aspiration of L/adrenal was not planned in our patient since the clinical history, CT characteristics and endosonographic finding favored the diagnosis of the adrenal metastases.

### Management of solitary adrenal metastasis

Although successful resection of hepatic and pulmonary metastasis from colorectal cancer has a survival benefit [16,17], place of the resection of an isolated adrenal metastasis remains controversial to date. The only series where 8 patients were treated for isolated adrenal metastases from colorectal carcinoma reported a median survival of 32 months [13]. A disease-free survival of more than six months has been shown to be an independent and significant predictor of improved survival in patients following adrenal metastatectomy [18]. Therefore resection of the isolated adrenal metastases from colorectal cancer seems to be appropriate for the patients in whom adrenal metastasis appear 6 months after primary surgery [13].

### Management dilemma in a resource limited setting

Metastasis to the adrenal gland is a more likely cause of an adrenal mass in this patient with a history of colorectal carcinoma. In our patient the appearance of a lesion on 2nd CT was more suspicious of



a metastatic lesion. EUS in this patient showed a heterogeneous mass suggestive of a metastasis which was compatible with the clinical diagnosis. In our setting the interpretation of EUS guided FNAC is still in infancy and therefore we could not rely on it. CECT abdomen of our patient had mix features, both for and against metastasis. Therefore we decided to go ahead with surgery.

### Natural history of solitary benign adrenal lesions

As reported in a study by Barry et al. [28] majority (95.6%) of the image and/or biopsy proven benign adenomas of the adrenal gland has a low rate of enlargement (<1cm/ year). They can be managed only with long term surveillance using imaging modalities. None of the patients in this study had hormonal hyper-secretion of the adrenal adenomas or malignant lesions on follow-up. Therefore the management is as for the benign adrenal lesions in the general population. This may not be applicable in the presence of extra adrenal malignancy since there is not enough data. Further it may increase patient anxiety and cause higher expenditure.

### Conclusion

Adrenal metastasis from colorectal cancer to the adrenal gland is considered to be relatively rare. It is generally accepted that a solitary adrenal metastasis from adenocarcinoma of the colon and rectum should be resected to achieve good prognosis. Therefore, it is important to consider the possibility of adrenal metastasis from colorectal cancer during the course of the disease. Imaging characteristic and image guided biopsy of the adrenal lesions can be used to differentiate the benign versus metastatic deposits in the adrenal gland with a good accuracy in the case of general population. Patients with extra-adrenal malignancy have a higher probability of an adrenal lesion being a metastatic disease.

### References

- Herrera MF, Grant CS, van Heerden JA, Sheedy PF, Ilstrup DM. Incidentally discovered adrenal tumors: an institutional perspective. *Surgery*. 1991; 110: 1014-1021.
- Bovio S, Cataldi A, Reimondo G, Sperone P, Novello S, Berruti A, et al. Prevalence of adrenal incidentaloma in a contemporary computerized tomography series. *J Endocrinol Invest*. 2006; 29: 298-302.
- Mansmann G, Lau J, Balk E, Rothberg M, Miyachi Y, Bornstein SR. The clinically inapparent adrenal mass: update in diagnosis and management. *Endocr Rev*. 2004; 25: 309-340.
- Bernardino ME, Walther MM, Phillips VM, Graham SD Jr, Sewell CW, Gedgudas-McClees K, et al. CT-guided adrenal biopsy: accuracy, safety, and indications. *AJR Am J Roentgenol*. 1985; 144: 67-69.
- Francis IR, Smid A, Gross MD, Shapiro B, Naylor B, Glazer GM. Adrenal masses in oncologic patients: functional and morphologic evaluation. *Radiology*. 1988; 166: 353-356.
- Anagnostis P, Karagiannis A, Tziomalos K, Kakafika AI, Athyros VG, Mikhailidis DP. Adrenal incidentaloma: a diagnostic challenge. *Hormones (Athens)*. 2009; 8: 163-184.
- Murakami S, Terakado M, Hashimoto T, Tsuji Y, Okubo K, Hirayama R. Adrenal metastasis from rectal cancer: report of a case. *Surg Today*. 2003; 33: 126-130.
- Grumbach MM, Biller BM, Braunstein GD, Campbell KK, Carney JA, Godley PA, et al. Management of the clinically inapparent adrenal mass ("incidentaloma"). *Ann Intern Med*. 2003; 138: 424-429.
- Katayama A, Mafune K, Makuuchi M. Adrenalectomy for solitary adrenal metastasis from colorectal carcinoma. *Jpn J Clin Oncol*. 2000; 30: 414-416.
- Young WF Jr. Clinical practice. The incidentally discovered adrenal mass. *N Engl J Med*. 2007; 356: 601-610.
- Lenert JT, Barnett CC Jr, Kudelka AP, Sellin RV, Gagel RF, Prieto VG, et al. Evaluation and surgical resection of adrenal masses in patients with a history of extra-adrenal malignancy. *Surgery*. 2001; 130: 1060-1067.
- Kanjo T, Albertini M, Weber S. Long-term disease-free survival after adrenalectomy for isolated colorectal metastases. *Asian J Surg*. 2006; 29: 291-293.
- Mourra N, Hoeffel C, Duvillard P, Guettier C, Flejou JF, Tiret E. Adrenalectomy for clinically isolated metastasis from colorectal carcinoma: report of eight cases. *Dis Colon Rectum*. 2008; 51: 1846-1849.
- Lam KY, Lo CY. Metastatic tumours of the adrenal glands: a 30-year experience in a teaching hospital. *Clin Endocrinol (Oxf)*. 2002; 56: 95-101.
- Pfannschmidt J, Dienemann H, Hoffmann H. Surgical resection of pulmonary metastases from colorectal cancer: a systematic review of published series. *Ann Thorac Surg*. 2007; 84: 324-338.
- Glomset DA. The incidence of metastasis of malignant tumors to the adrenals. *American Journal of Cancer*. 1938; 32: 57-61.
- Wang KX, Ben QW, Jin ZD, Du YQ, Zou DW, Liao Z, et al. Assessment of morbidity and mortality associated with EUS-guided FNA: a systematic review. *Gastrointest Endosc*. 2011; 73: 283-290.
- Kim SH, Brennan MF, Russo P, Burt ME, Coit DG. The role of surgery in the treatment of clinically isolated adrenal metastasis. *Cancer*. 1998; 82: 389-394.
- Boland GW, Lee MJ, Gazelle GS, Halpern EF, McNicholas MM, Mueller PR. Characterization of adrenal masses using unenhanced CT: an analysis of the CT literature. *AJR Am J Roentgenol*. 1998; 171: 201-204.
- Hönigschnabl S, Gallo S, Niederle B, Prager G, Kaserer K, Lechner G, et al. How accurate is MR imaging in characterisation of adrenal masses: update of a long-term study. *Eur J Radiol*. 2002; 41: 113-122.
- Boland GW, Goldberg MA, Lee MJ, Mayo-Smith WW, Dixon J, McNicholas MM, et al. Indeterminate adrenal mass in patients with cancer: evaluation at PET with 2-[F-18]-fluoro-2-deoxy-D-glucose. *Radiology*. 1995; 194: 131-134.
- Erasmus JJ, Patz EF Jr, McAdams HP, Murray JG, Herndon J, Coleman RE, et al. Evaluation of adrenal masses in patients with bronchogenic carcinoma using 18F-fluorodeoxyglucose positron emission tomography. *AJR Am J Roentgenol*. 1997; 168: 1357-1360.
- Gupta NC, Graeber GM, Tamim WJ, Rogers JS, Irisari L, Bishop HA. Clinical utility of PET-FDG imaging in differentiation of benign from malignant adrenal masses in lung cancer. *Clin Lung Cancer*. 2001; 3: 59-64.
- Hussain S. Gantry angulation in CT-guided percutaneous adrenal biopsy. *AJR Am J Roentgenol*. 1996; 166: 537-539.
- Welch TJ, Sheedy PF 2nd, Stephens DH, Johnson CM, Swensen SJ. Percutaneous adrenal biopsy: review of a 10-year experience. *Radiology*. 1994; 193: 341-344.
- Martinez M, LeBlanc J, Al-Haddad M, Sherman S, DeWitt J. Role of endoscopic ultrasound fine-needle aspiration evaluating adrenal gland enlargement or mass. *World J Nephrol*. 2014; 3: 92-100.
- Bodtger U, Vilmann P, Clementsen P, Galvis E, Bach K, Skov BG. Clinical impact of endoscopic ultrasound-fine needle aspiration of left adrenal masses in established or suspected lung cancer. *J Thorac Oncol*. 2009; 4: 1485-1489.
- Barry MK, van Heerden JA, Farley DR, Grant CS, Thompson GB, Ilstrup DM. Can adrenal incidentalomas be safely observed? *World J Surg*. 1998; 22: 599-603; discussion 603-604.