

Appendiceal Mass - Determining Resection with Frozen Section: A Case Report and Review of Literature

Daniel Fegely* and Rodolfo Colaco

St. John's Episcopal Hospital, Far Rockaway, NY, Trinitas Regional Medical Center, Elizabeth, NJ, USA

Article Information

Received date: Jul 23, 2018
Accepted date: Aug 20, 2018
Published date: Aug 21, 2018

***Corresponding author**

Daniel Fegely, St. John's Episcopal Hospital, Far Rockaway, NY, Trinitas Regional Medical Center, Elizabeth, NJ, USA, Tel: 6105872661; Email: drfegely@gmail.com

Distributed under Creative Commons CC-BY 4.0

Abstract

Guidelines for the type of resection to be done for an appendiceal mass are usually determined by the size and location of the mass in the appendix. This is because most masses of the appendix are found intra-operatively or after pathological examination [1]. In this case an appendiceal mass was seen on CT scan and intra-operative frozen section of the appendix was utilized to determine the type of resection that was required. The patient was found to have adenocarcinoma of the appendix on frozen section and a right hemicolectomy was then done during the same case. This case is also worth discussion as primary adenocarcinoma of the appendix is a rare tumor representing 0.03% of all appendiceal pathology [1].

Introduction

Recommendations for appendiceal neoplasm resection are usually referenced in texts and papers when the mass is found incidentally during operative intervention for acute appendicitis. This is due to most masses of the appendix presenting as or with acute appendicitis and not being found prior to operative intervention. If the mass is delineated prior to operative intervention then different planning is able to be done for resection. In this case the patient presented with abdominal pain and was found to have an appendiceal mass preoperatively. Intra-operative frozen section was then used to determine the pathology present in the appendix and subsequent extent of required resection. The use of frozen section for appendiceal masses is discussed along with appendiceal adenocarcinoma.

Case Study

The patient was a 55 year old Caucasian female from home with past medical history of hypertension, diabetes, asthma, and GERD who presented to the ambulatory surgery unit for exploratory laparotomy and resection of an appendiceal mass. She initially presented to the office with complaint of right lower quadrant abdominal pain for a few weeks. CT scan of the abdomen and pelvis with IV and PO contrast showed a right lower quadrant inflammatory mass that was 5 cm in diameter, most likely representing the appendix with a thickened wall (Figure 1). There was induration also noted in the adjacent appendiceal fat and in the intra-abdominal wall in the right lower quadrant. The patient had a colonoscopy during work up for the pain and a cecal polyp was removed and found to be a tubular adenoma. The colonoscopy was otherwise negative.

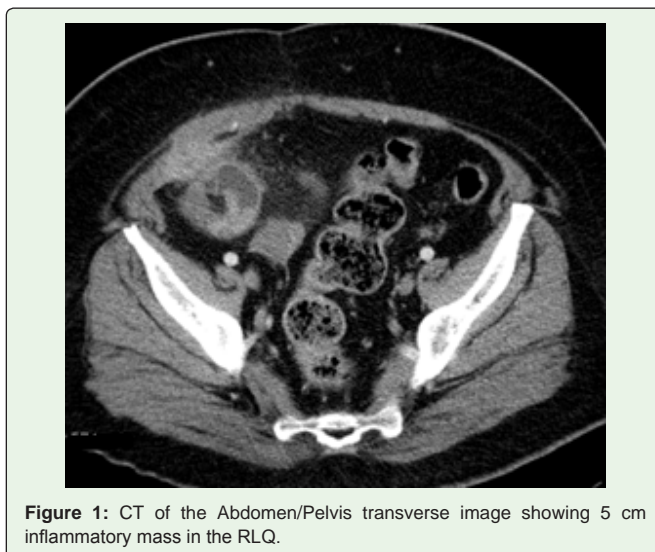


Figure 1: CT of the Abdomen/Pelvis transverse image showing 5 cm inflammatory mass in the RLQ.

She had a past medical history of hypertension, diabetes, asthma, and GERD. Her past surgical history consisted of a hysterectomy, laparoscopic cholecystectomy, and excision of a salivary gland. The patient denied smoking, drinking, or illicit drug use. She denied any family history of colon cancer or any other malignancy. Her allergies included nuts, latex and she had seasonal allergies.

The physical exam was positive for mild tenderness in the right lower quadrant of her abdomen. The abdomen was soft and non-distended. There was no rebound or guarding appreciated on exam. All other components of the physical exam were noncontributory.

It was then decided to proceed to the operating room for an exploratory laparotomy and open appendectomy with frozen section and possible right hemicolectomy pending frozen section results. The Urology service placed bilateral ureteral stents prior to the abdominal procedure. A low midline incision was made into the abdominal cavity. There was swelling noted at the tip of the appendix and the anterior abdominal wall was noted to be involved with the swelling. A portion of the anterior abdominal wall that was abutting the mass along with attached omentum was taken and sent for frozen section along with the appendix. The mass was also noted to be surrounded by a portion of small bowel. On frozen section the mass was found to be adenocarcinoma and was 3 cm from the proximal base of the appendix. A right hemicolectomy was then performed with the proximal margin taken proximal to the ileum involved with the mass. The patient recovered well postoperatively and was discharged home on post-operative day 6 with close follow up in the office.

The final pathology resulted in the tumor being classified as a 1.7 cm mucinous adenocarcinoma that was invading through appendiceal serosa into the anterior abdominal wall with 1 out of 15 lymph nodes positive for disease. Final TNM stage for the appendiceal adenocarcinoma was T4N1M0.

Review of Literature

In a study by Arellano, et al. the incidence of adenocarcinoma of the appendix is addressed. In the time frame of 47 years the study reviewed 53,019 cases of acute appendicitis. It was noted that 44 patients were found to have primary adenocarcinoma of the appendix. Of these patients the most common preoperative diagnosis was acute appendicitis which was calculated to be 66%. Most patients first had an appendectomy and then a subsequent right colectomy which was done in 2 to 5 weeks. Of the population studied this was needed to be done in 73%. Only the remaining 27% had a right colectomy at first initial operation. This study shows that primary adenocarcinoma of the appendix is rare, consisting of only 0.01% of cases, and most cases present as acute appendicitis [1].

Appendiceal adenocarcinoma is a condition which is difficult to treat as most patients are diagnosed in an advanced stage [2]. A retrospective study was conducted on patients diagnosed with adenocarcinoma of the appendix in Iceland between 1990 and 2009. In the study by Vidarsdottir H, et al. 22 patients were studied and most patients were diagnosed at operation or on pathology examination. Stage 4 disease was noted in 13 patients, while Stage 3, 2, and 1 disease was noted in 3, 3, and 3 patients respectively. No patients were diagnosed pre-operatively.

Prognostic factors pertaining to adenocarcinoma of the appendix are discussed in a study by Cortina, et al. In this study there were 13 patients diagnosed with adenocarcinoma of the appendix between 1972 and 1992 in 3 teaching hospitals. Of the patient population 5 were male and 8 were female. It was found that 77% of these patients had metastatic disease on presentation [3]. This is consistent with Vidarsdottir H, et al. where Stage 4 disease was noted in 13 out of 22 patients (59%) [2]. In the study patients that had mucinous histology had a better chance of survival than with colonic histology (P = 0.0093). It was also noted that patients with carcinomatosis had a worse chance of survival than patients without carcinomatosis (P = 0.0078) [3].

Outcomes after surgical intervention for patients with appendiceal adenocarcinoma depend largely on the type of resection that is performed. In a study by Ito H, et al. 36 patients with appendiceal adenocarcinoma were treated between 1981 and 2001. Of the patients treated 18 underwent a curative resection. It was determined that the overall 5 year survival was 46%. Survival at 5 years for a curative resection was found to be 61% compared to only 32% when a palliative surgery was done [4]. Curative resection should be done and may be as simple as an appendectomy. Patients may require a right hemicolectomy as the initial procedure, or subsequent procedure after initial appendectomy.

Discussion

Appendiceal tumors are difficult to treat as most are diagnosed at pathologic examination after resection. It is a rare occurrence that the appendiceal mass is diagnosed prior to an attempted resection. For noncarcinoid tumors of the appendix larger than 1 cm a right hemicolectomy is recommended [5]. Recommendations for carcinoid tumors of the appendix are slightly different in regards to resection. For carcinoid tumors that are larger than 1 to 2 cm, involves the base of the appendix, or invade the mesoappendix a right hemicolectomy is recommended [5]. In this case the patient had a 1.7 cm mass 3 cm from the proximal appendix base on final pathology. The size of this mass falls between guidelines depending on what the type of tumor pathology is found to be present. If the mass is adenocarcinoma a right hemicolectomy is recommended. An appendectomy could be done if the mass was found to be carcinoid since the mass was not involved with the appendiceal base. In this case frozen section of the appendix was utilized to determine the required resection. The pathology was found to be adenocarcinoma therefore a right colectomy was done. If an appendiceal mass is diagnosed before operative intervention frozen section can be used to guide the procedure course and determine resection. Curative resection is a large determination of 5 year survival as seen in the study by Ito H, et al. By using intra-operative frozen section the correct resection can be done at the first operation without the need for any additional procedure that may be required for curative intervention.

Conclusion

Appendiceal masses remain a difficult entity to treat due to the multiple potential pathologies that can be present. Most times the tumors are found after routine appendectomy for appendicitis and an additional surgery is required to adequately treat the patient [6,7]. It is also noted that a large amount of patients are found to have stage 4 appendiceal tumors at presentation [2]. Intra-operative frozen

section should be used if the appendiceal mass is diagnosed prior to any surgical intervention to determine the type of pathology that is present and the correct resection required for curative treatment.

References

1. Arellano ML, Dominguez YG, Ortiz FM, Garceau MAH, Cantero R, Montes JAR. Primary Adenocarcinoma of the Appendix: Experience at La Paz University Hospital of Madrid (1967-2014). *International Journal of Surgery Open*. 2016; 4: 23-26.
2. Vidarsdottir H, Jonasson JG, Moller PH. Adenocarcinoma of the Appendix in Iceland 1990-2009. A population based study. *Laeknabladid*. 2011; 97: 537-542.
3. Cortina R, McCormick J, Kolm P, Perry RR. Management and Prognosis of Adenocarcinoma of the Appendix. 1995; 38: 848-852.
4. Hiromichi I, Osteen RT, Bleday R, Zinner MJ, Ashley SW, Whang EE. Appendiceal Adenocarcinoma: Long-Term Outcomes after Surgical Therapy. *Diseases of the Colon & Rectum*. 2004; 47: 474-480.
5. Sabiston David C, Courtney M. Townsend. Sabiston Textbook of Surgery: The Biological Basis of Modern Surgical Practice. Elsevier Saunders, 2012. 1290-1291.
6. Kelly KJ. Management of Appendix Cancer. *Clinics in Colon and Rectal Surgery*. 2015; 28: 247-255.
7. Nitecki SS, Wolff BG, Schlinkert R, Sarr MG. The Natural History of Surgically Treated Primary Adenocarcinoma of the Appendix. *Annals of Surgery*. 1994; 219: 51-57.