

Isolated Vastus Intermedius Rupture-
Case Report and Review of LiteratureAzzopardi C¹, Vidoni A^{1*}, Goswami V² and Botchu R²¹Department of Orthopedics, Royal Orthopedic Hospital, Bristol Road South, UK²Department of Musculoskeletal Radiology, Heart of England NHS Foundation Trust, UK

Article Information

Received date: May 11, 2018

Accepted date: May 30, 2018

Published date: May 31, 2018

*Corresponding author

Alessandro Vidoni, Department of
Orthopedics, The Royal Orthopedic
Hospital, Bristol Road South, UK;
Email: avidonimd@gmail.comDistributed under Creative Commons
CC-BY 4.0Keywords Vastus Lateralis; Vastus
Medialis; Rectus femoris; Vastus
Intermedius

Abstract

Quadriceps ruptures are common but isolated tears of the vastus intermedius are uncommon. We present a case of a 45-year-old man presenting with swelling and pain in the thigh after trauma who had an isolated tear of the vastus intermedius.

Introduction

Quadriceps rupture is not uncommon. Partial tears usually involve either the rectus femoris or vastus intermedius tendon insertions whilst isolated tears of the vastus lateralis and medialis are less common [1]. Clinical suspicion of this condition and early confirmation on imaging is important as a delay in treatment may result in significant morbidity with retraction and atrophy of the quadriceps muscle [2]. Only two case reports of isolated tears of vastus intermedius have been described to date [3,5]. We present a case of a 45-year-old man presenting with swelling and pain in the thigh after trauma who had an isolated tear of the vastus intermedius.

Case report

45-year-old gentleman presented with swelling over his right anterior thigh and weakness of knee extension. His symptoms developed immediately after a twisting injury whilst lifting weights. The patient was fit and well with no past medical history. He was not on any medications, in particular, steroids which could have increased his risk of tendon rupture. Examination revealed a small dip in the anterior aspect of the right anterior thigh with some extensor lag and weak knee extension.

An ultrasound scan performed externally showed a partial tear of the quadriceps tendon which was treated conservatively. A formal ultrasound then demonstrated a defect in the deep aspect of the quadriceps tendon with proximal retraction from its patellar attachment. The superficial fibre, that is, the rectus femoris component was intact (Figure 1). This was made more obvious by dynamically flexing and extending the knee during the ultrasound scan. The patellar tendon was intact.

MRI confirmed the findings seen on ultrasound with a small fluid filled defect in the vastus intermedius just proximal to the insertion of quadriceps into the patella. The rectus femoris, vastus medialis and lateralis were intact. The defect in vastus intermedius measured 4cm from its patellar insertion (Figure 2).

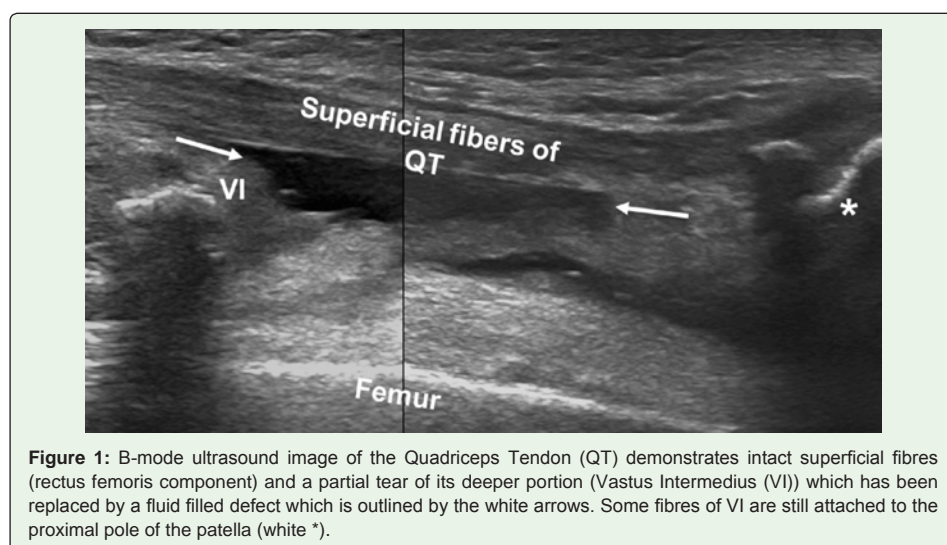
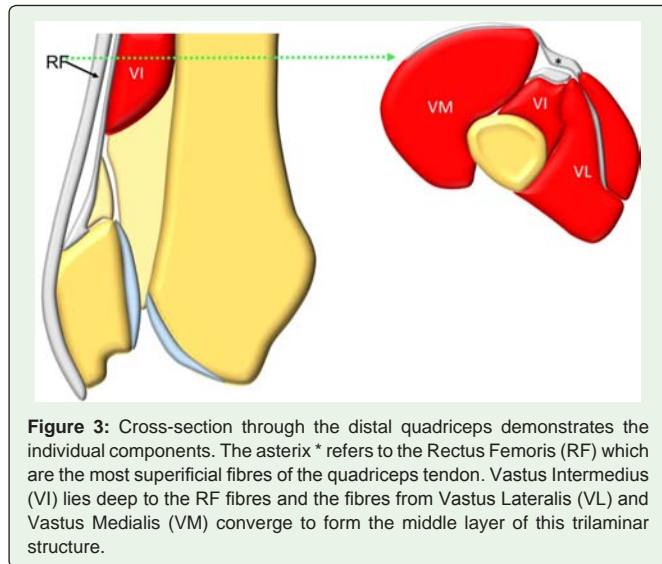
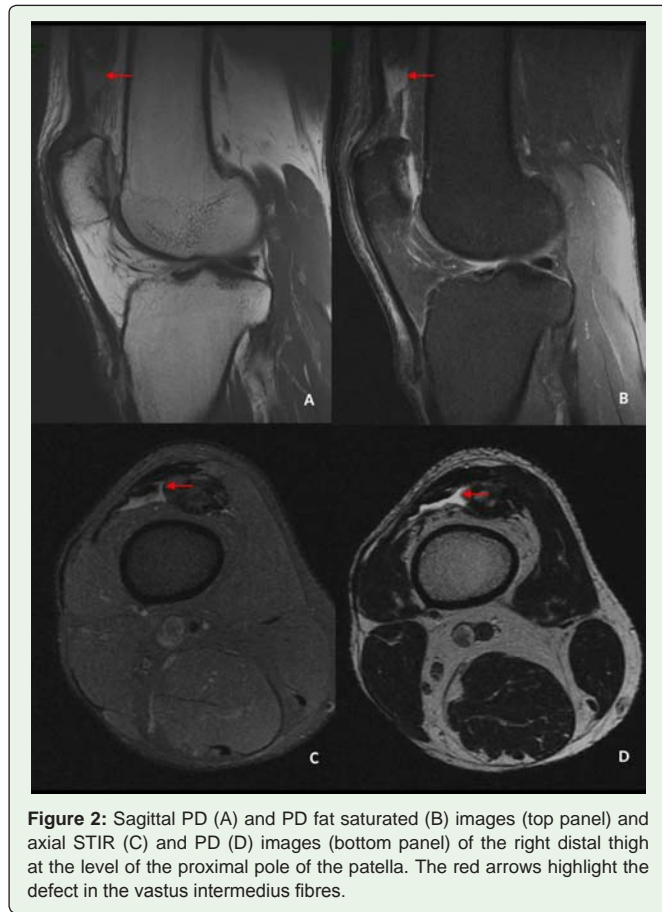

Figure 1: B-mode ultrasound image of the Quadriceps Tendon (QT) demonstrates intact superficial fibres (rectus femoris component) and a partial tear of its deeper portion (Vastus Intermedius (VI)) which has been replaced by a fluid filled defect which is outlined by the white arrows. Some fibres of VI are still attached to the proximal pole of the patella (white *).



The patient was treated conservatively initially in a brace in extension for a couple of weeks with controlled weight-bearing followed by graduated knee flexion. From 5th weeks onwards, range of motion exercises, stretching and proprioception exercise programs were commenced under supervision of physiotherapist.

Discussion

Quadriceps tendon ruptures are more common after the 4th decade usually in the presence of risk factors such as systemic or local steroids, statins and fluoroquinolones. Younger patients usually present after trauma. Eccentric overloading of the extensor mechanism when the knee is flexed with plantar flexion of the foot is the most common mechanism of injury [3].

The quadriceps femoris inserts into the patella as a common tendon with a tri-laminar arrangement. The most superficial fibres originate from the rectus femoris, the deepest layer from the vastus intermedius and the intermediate layer from the vastus lateralis and vastus medialis [4] (Figure 3).

The vastus intermedius arises from the proximal two thirds of the anterolateral surface of the femur, the lower half of the line as per a, the upper part of the lateral supra condylar line and the lateral intermuscular septum. It converges towards the patella and divides into lateral and medial parts. The vastus intermedius contributes first to the deep layer of the quadriceps tendon through its lateral part and second to the two-layered intermediate layer of the quadriceps tendon by its superficial and deep medial aponeurosis [4]. Its nerve supply is from the femoral nerve and its arterial supply is from the lateral femoral circumflex artery [5].

Clinical presentation of quadriceps rupture varies depending on the severity of the injury. The patient may present with difficulty walking, swelling, a mobile patella with loss of extensor mechanism, and a palpable defect. An extensor lag may be an indication of a partial tear [5].

Ultrasound is usually the first line investigation as it is readily available. The sensitivity and specificity of ultrasound in identifying partial tears is not established [5]. One advantage of ultrasound is the ability to perform real time dynamic scanning, which optimises the evaluation of tendon tears. Knee flexion and extension confirms the continuity of an intact tendon and helps differentiate from scar tissue [6]. Real-time dynamic scanning is a feature unique to sonography and is a capability that should be used to optimize evaluation of tendon tears. With knee flexion and extension, the fibrillar echo texture of an intact tendon may be more obvious, allowing further differentiation from scar tissue

Partial tears are seen on MRI as focal discontinuities of some layers of the quadriceps whilst other layers are still intact. MRI is the imaging modality of choice for optimally visualizing partial tears and treatment planning [7].

An isolated vastus intermedius tendon rupture is difficult to detect clinically and peri-operatively since the rectus femoris is intact, which makes this injury easy to miss. Early diagnosis and treatment is essential to decrease morbidity. Ultrasound and MRI play an essential role in the diagnosis of quadriceps rupture as they delineate the exact nature of the injury. There is no definitive treatment for the isolated vastus intermedius injury documented in the literature [5].

Teaching point

- Isolated tears of the vastus intermedius are rare
- They should be assessed by dynamic ultrasound scanning

- MR is the gold standard
- Early treatment is paramount as delays may result in retraction of the tendon and poor surgical outcome

References

1. MRI of Rectus Femoris / Quadriceps Injury - Radsourc. 2017.
2. Yu JS, Petersilge C, Sartoris DJ, Pathria MN, Resnick D. MR imaging of injuries of the extensor mechanism of the knee. *Radiographics*. 1994; 14: 541-551.
3. Cetinkaya E, Aydin CG, Akman YE, Gul M, Arikan Y, Aycan OE, et al. A rare knee extensor mechanism injury: Vastus intermedius tendon rupture. *International Journal of Surgery Case Reports*. 2015; 14: 186-188.
4. Grob K, Manestar M, Filgueira L, Ackland T, Gilbey H, Kuster MS. New insight in the architecture of the quadriceps tendon. *J Exp Orthop*. 2016; 3: 32.
5. S.M. Thompson, J. Bird, N. Somashekar, E. Dick, D. Spicer. Investigation and treatment for isolated vastus intermedius rupture. *Injury Extra*. 2008; 39: 232-234.
6. Foley R, Fessell D, Yablon C, Nadig J, Brandon C, Jacobson J. Sonography of Traumatic Quadriceps Tendon Tears With Surgical Correlation. *J Ultrasound Med*. 2015; 34: 805-810.
7. Zeiss J, Saddemi SR, Ebraheim NA. MR imaging of the quadriceps tendon: normal layered configuration and its importance in cases of tendon rupture. *Am J Roentgenol*. 1992; 159: 1031-1034.