

The Beneficial Effect of Apixaban in the Treatment of Heparin-Induced Thrombocytopenia (HIT 2)

Priya Bhardwaj, Jan Roland Petersen and Gitte Gleerup Fornitz*

Department of Cardiology, Slagelse Hospital, Denmark

Article Information

Received date: Mar 20, 2018

Accepted date: Apr 04, 2018

Published date: Apr 06, 2018

*Corresponding author

Gitte Gleerup Fornitz, Department of Cardiology, Slagelse Hospital, Slagelse, Denmark, Tel: +45-9357-7909; Email: gitte.fornitz@live.dk

Distributed under Creative Commons CC-BY 4.0

Keywords Thrombocytopenia; Heparin-treatment; Anticoagulation therapies; NOACs

Abstract

This case report illustrates a patient with Heparin-Induced Thrombocytopenia (HIT) who was successfully treated with Apixaban. HIT is an adverse drug reaction induced by treatment with heparin. The optimal anticoagulation strategy remains uncertain. This case presents a patient who developed massive pulmonary embolisms post total knee replacement, she was then treated with low-molecular-weight heparin (LMWH), which lead to bleeding and a critically platelet count drop, indicating serious HIT 2 syndrome.

By discontinuation of LMWH and switch to Apixaban in a modified dose regime, we managed to stop the life-threatening complications of LMWH. The platelet count recovered, and the patient survived.

Introduction

Heparin-Induced Thrombocytopenia (HIT) is an adverse drug reaction induced by treatment with heparin, which occurs more likely with unfractionated heparin (UFH) than with low-molecular-weight heparin (LMWH) [1]. HIT has been categorized into two groups; HIT type 1 is defined as a mild reaction, non-immune mediated. No complications are seen, and the thrombocytopenia will show spontaneous remission whilst continued treatment with heparin. HIT type 2 is an immune-mediated reaction [2]. Usually, the platelet 4 factor (PF4) is stored in and released from the alpha granules of activated platelets. PF4 binds to heparin due to high affinity, and this might trigger the formation of immunoglobulin G (IgG) antibodies. HIT occurs only if IgG is attached to the heparin-PF4 complex and this binds to platelet receptors. This leads to both a critical prothrombotic situation and bleedings caused by thrombocytopenia [3,4]. Type 2 HIT usually inserts 5-14 days after the first dose of heparin.

However, one single dose of heparin may cause the development of antibodies, and re-exposure to heparin within 3 months may cause serious life-threatening reactions [5,6].

Platelet count $<150 \times 10^9/L$ defines thrombocytopenia, while severe thrombocytopenia is defined by count $<50 \times 10^9/L$. Consequences can be life-threatening with a very high mortality rate (30%) [7,8], caused by bleedings (thrombocytopenia) and a hypercoagulable state, where most patients developed severe thromboembolic complications. Today there are no evidence-based recommendations how to treat these patients [9]. The new oral anticoagulants (NOACs) have shown relevant properties for the management of HIT, by rapid onset of action, oral administration, ease of use and lack of monitoring [10].

Case Report

A 67-year-old white female patient presented to emergency department with dehydration and a medical history of a right total knee arthroplasty 8 days before arrival. No clear symptoms other than loss of appetite. The patient was hemodynamically stable, which included normal blood pressure and pulse. Routine admission laboratory for general medical patients showed increased C-Reactive Protein (CRP) level at 190 mg/L [<10 mg/L] and a low haemoglobin level at 5.4 mmol/L [7,3 - 9,5 mmol/L]. She started treatment with 4 g piperacillin combined with 0.5 g tazobactam on the suspicion of pneumonia.

Due to the high risk of developing thrombosis by being bedridden and the suspicion of pulmonary embolism, the patient was treated with Dalteparin 200IU/kg of body weight (Figure 1). Computed Tomography (CT) scan of the chest verifies bilateral infiltrates and pulmonary embolism was disconfirmed, so the patient was treated for pneumonia with intravenous 4 g Piperacillin combined with 0.5 g Tazobactam in 11 days and 500 mg Clarithromycin in 7 days, and then discharged from the hospital.

5 days later the patient developed dyspnea, and due to d-dimer 20 L [<0.7] (Table 1) and chest CT verified bilateral massive pulmonary embolisms, treatment with Dalteparin 200IU/kg of body

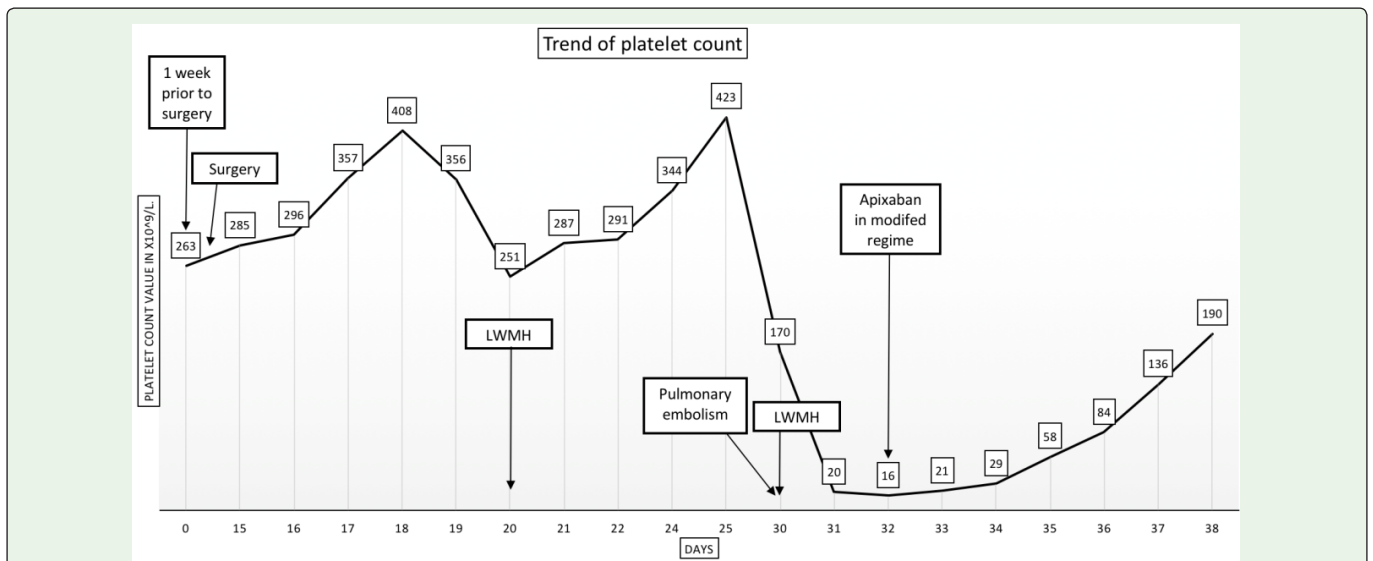


Figure 1: The trend of thrombocytopenia in the patient.

Table 1: Laboratory test results after heparin exposure.

Laboratory test	Day 30	Day 31	Day 32	Day 33	Day 34	Day 35	Day 36	Day 37	Day 38
Hemoglobin (mmol/L)		6,50	6,40	5,60	6,20	6,50	6,40		
Platelet Count (>150×10 ⁹ /L)	170,00	19,00	16,00	21,00	29,00	58,00	84,00	136,00	190,00
Fragment D-dimer	20,00	5,80	4,90	3,70	7,30	6,00			
Fibrinogen (5-11.5µmol/L)		22,70	21,50	16,90	16,70	14,80			
APTT (27-40 sec)		68,00	56,00		37,00				
INR (0.8-1.2)		1,40	1,40	1,50	1,60	1,70			1,50
Antithrombin(0.8-1.2 ×10 ³ IU/L)		0,61	0,78	0,82	0,84	0,84			

weight was immediately effectuated (Figure 1). Ultrasound of lower extremities and the pelvis were without thromboses.

12 hours later we observed gingival bleeding, petechiae on lower extremities and ecchymoses on the truncus. Platelet count showed a decrease of 88.9% (from 170×10⁹/L to 20×10⁹/L).

Dalteparin was then immediately discontinued and due to bleeding and thrombocytopenia transfusion of platelet concentrate was given, which aggravate the patient’s situation. As a result of more bleeding and periphery embolies, we observed a further drop in platelet count (16×10⁹/L).

As blood test analysis for antibodies directed against PF4 was not locally available, the diagnosis of HIT 2 was based on the available blood tests (Table 1) and the 4T score (Table 2).

To verify the diagnosis, a blood test was later taken and sent abroad, but unfortunately it went missing.

At this point, the patient was in a life-threatening situation with bleedings caused by thrombocytopenia and with severe thromboembolic complications caused by a hypercoagulable state. To turn this situation, we started with a single dose of Apixaban 2.5mg.

We then observed increasing platelet count, and thereafter a modified regime was used to treat the patient, that consisted

of Apixaban 2.5 mg BID, then Apixaban 5.0 mg BID and then a treatment dose of Apixaban 10.0 mg BID 1 week. During the next 7 days, the platelet count increased to 190×10⁹/L, and the patient was asymptomatic. Figure 1 illustrates the increase in platelets during Apixaban treatment, in the same period we observed a decrease in fibrinogen and APTT and d-dimer (Table 1).

4Ts score was used to investigate if the patient were likely to have HIT, by assessing the probability of having HIT. Score result >4 represents a high probability of HIT and can be divided into intermediate and high risk. The variables include thrombocytopenia, timing, thrombosis and the likelihood of another diagnosis. In our case, the patient scored 7 points (Table 1), as a result of the decrease in platelet count of 89%, timing <4 days after exposure, bilateral PE and no other obvious reasons.

Table 2: 4Ts Score of the patient.

Variable	Score
Thrombocytopenia	2
Timing of platelet count decrease	1
Thrombosis or other sequelae	2
Other causes of thrombocytopenia	2

2 points were given if the patient had a >50% platelet count decrease, decrease in 5-10 days, proven new thrombosis and no other explanation for platelet count decrease. 1 point was given if the patient had a 30-50% platelet count decrease, consistent with 5-10 days/decrease <1 day with lately heparin exposure, progressive/recurrent thrombosis and possibly no other evident cause. Lastly, 1 point was given, if the patient had <30 % platelet count decrease, a decrease in less than 5 days (with no recent heparin exposure), none thrombosis nor other present cause [11].

Discussion

HIT can occur in 5% of patients exposed to heparin, it is an extremely severe condition with a high mortality rate. Usually, HIT occurs in patients treated with UFH; however, in this case report the patient was exposed to LMWH. Interestingly in this case, the patient before developing pulmonary embolism was treated with one single dose of LMWH due to the high risk of developing thrombosis by being bedridden and suspicion of pulmonary embolism. Subsequently, the platelet count actually increases from $251 \times 10^9/L$ to $423 \times 10^9/L$.

This single dose of LMWH might have caused the development of antibodies that remained in the patient and caused both the extreme hypercoagulable state and the extreme drop in platelets ($20 \times 10^9/L$) when the patient shortly after was exposed to heparin due to life-threatening pulmonary embolism. Whether the pulmonary embolism was due to the already existing antibodies which caused a prothrombotic state remains unclear. But consequently, just a few hours after retreatment with heparin 28/2 due to massive pulmonary embolisms, the patient developed a life-threatening thrombocytopenia and a prothrombotic state which in this case lead to a severe health state with pulmonary and periphery embolisms, which usually ends fatally in 30% of the patients.

There are no existing guidelines on how to manage this critical condition, to our knowledge, and only a few case reports have previously been published.

In our case we successfully used a modified regime that consisted of Apixaban 2.5 mg BID for 1 day, then Apixaban 5.0 mg BID and then a treatment dose of Apixaban 10.0 mg BID for 1 week in order to restore the haemostatic balance. Treatment of HIT mainly consists in discontinuing heparin treatment and switching to an alternative anticoagulant, which could be direct thrombin inhibitors or direct factor, Xa inhibitors. Treatment with warfarin and thrombocyte transfusions is contraindicated as the risk of thrombosis increases [9]. Apixaban was used in this case for anticoagulation management as the HIT antibodies do not target the drug [12].

This treatment regime is supported by a few other case reports in which describes the beneficial effect of NOACs in the treatment of HIT syndrome [13,14].

Conclusion

Heparin treatment among others has potential to induce thrombocytopenia in patients. This case report suggests attention to platelet counts in patients treated with LMWH as well as a careful clinical examination of the patient can be crucial for the best prognosis.

In this case, the patient is treated first with one single dose of LMWH as prophylaxis, and then gets exposed with LMWH again due to pulmonary embolism, which causes the development of a fulminant immune-mediated HIT reaction. Our patient had an extensive clot burden and a critical platelet drop. Data in treatment of these patients are very limited. However, our modified treatment with Apixaban, we managed to turn this fierce reaction and critical situation, and the recovered patient is now dismissed from the hospital with a continued treatment with Apixaban 5 mg BID for at least 6 months.

This case enlightens the need for a worldwide data collection for this type of patient in order to make international treatment guidelines for HIT 2 patients.

This case report demonstrates that Apixaban can be used as a safe treatment option in patients with HIT.

Acknowledgement

Patient consent: A signed informed consent was obtained from the patient before writing the case report.

Author Contributions: All authors contributed to analysis and interpretation of the data. All authors contribute to drafting, critical revision and final approval of the article.

Conflicts of Interest: The authors received support from Boehringer Ingelheim, Bristol-Myers Squibb, Pfizer, MSD Denmark ApS and Bayer.

The sponsors had no role in data collection, data interpretation or the writing of this publication.

References

1. Sekhon SS, Roy V. Thrombocytopenia in adults: A practical approach to evaluation and management. *South Med J*. 2006; 99: 491-498.
2. Nicolas D, Reed M. Thrombocytopenia, Heparin Induced. *StatPearls Publishing*. 2018.
3. Nagalla S, Sarode R. Recent advances in understanding and management of acquired thrombocytopenia. *F1000Research*. 2018; 7: 68.
4. Krauel K, Pötschke C, Weber C, Kessler W, Füll B, Ittermann T, et al. Platelet factor 4 binds to bacteria, [corrected] inducing antibodies cross-reacting with the major antigen in heparin-induced thrombocytopenia. *Blood*. 2011; 117: 1370-1378.
5. Warkentin TE, Bernstein RA. Delayed-Onset Heparin-Induced Thrombocytopenia and Cerebral Thrombosis after a Single Administration of Unfractionated Heparin. *N Engl J Med*. 2003; 348: 1067-1069.
6. Modi C, Satani D, Cervellione KL, Cervantes J, Gintautas J. Delayed-onset heparin-induced thrombocytopenia type-2 during fondaparinux (Arixtra) therapy. *Proc West Pharmacol Soc*. 2009; 52: 5-7.
7. Warkentin TE. Fondaparinux for Treatment of Heparin-Induced Thrombocytopenia. *J Am Coll Cardiol*. 2017; 70: 2649-2651.
8. Heidebuchel H, Verhamme P, Alings M, Antz M, Diener HC, Hacke W, et al. Updated European Heart Rhythm Association Practical Guide on the use of non-vitamin K antagonist anticoagulants in patients with non-valvular atrial fibrillation. *Europace*. 2015; 17: 1467-1507.
9. Öztürk E, Mutluer FO. A Practical and Case-Based Approach to Thrombocytopenia in Cardiology Practice. *Turk Kardiyol Dern Arsivi-Archives Turkish Soc Cardiol*. 2018; 46: 155-162.

10. Khalid S, Daw H. The Role of Apixaban in the Treatment of Heparin-Induced Thrombocytopenia. *Cureus*. 2017; 9: 1428.
11. East JM, Cserti-Gazdewich C, Granton JT. Heparin-Induced Thrombocytopenia in the Patient Who Is Critically Ill. *Chest*. 2017; 1-13.
12. Walenga JM, Prechel M, Hoppensteadt D, Escalante V, Chaudhry T, Jeske WP, et al. Apixaban as an Alternate Oral Anticoagulant for the Management of Patients With Heparin-Induced Thrombocytopenia. *Clin Appl Thromb Hemost*. 2013; 19: 482-487.
13. Sharifi M, Bay C, Vajo Z, Freeman W, Sharifi M, Schwartz F. New Oral Anticoagulants in the Treatment of Heparin- Induced Thrombocytopenia. *Thromb Res*. 2015; 135: 607-609.
14. Poudel DR, Ghimire S, Dhital R, Forman DA, Warkentin TE. Spontaneous HIT syndrome post-knee replacement surgery with delayed recovery of thrombocytopenia: a case report and literature review. *Platelets*. 2017; 28: 614-620.