

# Rifamycin Sv Intrasinioally Injected in Arthritides Patients Showed Anti-Synovitis Activity and Some Features of the Disease Modifying Drugs

Caruso Innocenzo<sup>1\*</sup>, Cazzola Marco<sup>2</sup>, Santandrea Salvatore<sup>3</sup>, Montrone Franco<sup>4</sup> and Caruso Enzo Massimo<sup>5</sup>

<sup>1</sup>Past chief Rheumatology Unit, L. Sacco Hospital Milano, Italy

<sup>2</sup>Chief of rehabilitation Department, Saronno Hospital Varese, Italy

<sup>3</sup>Department of Rheumatology UOC, L.Sacco Hospital milano, Italy

<sup>4</sup>President, Associazione Italiana Contro l'Artrite (AICA), Italy

<sup>5</sup>Orthopedic Unit ist, clinico San Siro Milan, Italy

## Article Information

Received date: Jul 29, 2017

Accepted date: Aug 11, 2017

Published date: Aug 17, 2017

### \*Corresponding author

Caruso innocenzo, Past chief  
Rheumatology Unit, L. Sacco Hospital  
Milano Italy, Corso Italia 11, 20122  
Milano Italy; Tel: 338603264;  
Email: innocenzo.caruso@tiscali.it

**Distributed under** Creative Commons  
CC-BY 4.0

**Keywords** Endosomal epitopes;  
Pathogenic epitopes; Autonomic  
endogenous immunotherapy;  
Arthritogenic epitopes; Intrasinovial  
infiltration

## Abstract

**Objectives:** We addressed retrospectively the results of polyintrasynovial infiltration with Rifamycin SV, related to 658 patients with different forms of arthritides. The objective was to verify whether this treatment, in addition to treating synovitis, had the ability to induce the remission of extrarticular signs of diseases.

**Methods:** The patients were subdivided according to the treatment schedule:

- The group of arthritides (374) in which patients were subjected to infiltration on only one big joint with the aim to cure the individual synovitis;
- those (189) in whom the treatment had been extended from one to weekly infiltration of three or four big joints;
- the group of patients (95) in which only the small joints were treated.

Each of 1,364 joints, 727 big and 637 small, had been infiltrated once a week for 10 weeks and all patients were followed for three years.

**Results:** The individual synovitis showed a significant correlation with the kind of arthritides, the presence of radiological damage and dimension of joints. Patients in whom three or four joints were weekly infiltrated showed the remission of extra articular manifestations in psoriatic arthropathy and the clinical improvement and normalization of inflammation markers in many patients with rheumatoid arthritis. These changes occur very slowly, sometimes months after the end of 10 weeks of infiltrations.

**Conclusions:** The outcome of synovitis was related to anti-proliferative and cytolytic properties of Rifamycin SV. The remission of extrarticular manifestations of arthritides should be sustained by complex immunological mechanisms that Rifamycin SV indirectly might have activated only when it was infiltrated by the intrasinovial route.

## Introduction

Rifamycin SV repeatedly injected in joints with synovitis produces a series of effects [1-3] that are, in part, consistent with its pharmacology and pharmacodynamic characteristics, such as the inhibition, at high dose, of DNA-dependent RNA synthesis and protein synthesis in synovial tissue of experimental models of chronic inflammation in Guinea pigs [4], which account for its anti-inflammatory action on the synovitis of adult patients with arthritides, and their remission, and juvenile chronic arthritis [5,6].

In addition, the cytolytic properties that cause the marked depletion of synovial cells, observed in both experimental animal models of arthritis and arthritic patients (synoviorthesis) treated with intrasinovial infiltrations, are in line with the pharmacodynamic properties of this molecule [4,7]. Here, the needle biopsies of knee synovial membrane performed 30 months after therapy show that vast areas of tissue are replaced by a mass of collagen without fibrillar design. The levels of Rifamycin SV in the knee joint after infiltration with 500 mg is very high and persists for at least 4 hours (0.5–5 mg/mL synovial fluid); Rifamycin SV (125 µg/mL) provokes the cytolysis of about 90% of peripheral blood mononuclear cells (PBMCs) ( $5 \times 10^6$ ) at 37°C for 180 minutes (Caruso personal).

An effect of intrasinovial Rifamycin SV that has no connection with the molecular profile of this antibiotic is the induction of amelioration of symptomatology and the remission of extrarticular manifestations in most patients with arthritides [6,7].

We relied on the cytolytic action of Rifamycin SV and hypothesized that pathogenic autoantigen, freed from synovial cells would stimulate the immune regulatory T-cell response similar to that reported in some models of autoimmune diseases such as experimental autoimmune encephalomyelitis [8,9] and diabetes mellitus [10,11], in which the specific antigen pathogenetically responsible for the disease had been employed as a therapeutic agent to induce immune tolerance. Therefore, the remission of extrarticular signs of arthritides should be sustained by complex immunological mechanisms that Rifamycin SV indirectly might have activated only when it was infiltrated by the intrasynovial route.

In the present work, we addressed retrospectively the results of intrasynovial treatment with Rifamycin SV related to 658 patients with different form of arthritides, in which the inflamed joints, big and small, were infiltrated once a week for 10 weeks,

All patients were subdivided according to Rx picture (presence/absence of radiographic lesions).

The aims of the study were to investigate: (1) the incidence of the remission of individual synovitis; (2) the relation between the remission of individual synovitis and radiographic positivity/negativity; (3) the relation between the remission of synovitis and dimension of joints subdivided as big and small; (4) and the incidence of the remission of systemic manifestations in patients who underwent infiltration on greater number of joints per week because of the severity of disease.

## Patients

The study design was approved by the Ethics Committee of L. Sacco Hospital and by the Ethics Committee of the Regional Government of Lombardia, Italy. Informed consent was obtained from all patients.

The folders of 658 patients, with different arthritides were subdivided according to the treatment schedule with intrasynovial Rifamycin SV to which the patients had been subjected: (a) the group of arthritides (374) in which patients were subjected to infiltration on only one big joint. It encompassed 148 rheumatoid arthritis (RA), 50 juvenile chronic arthritis oligo-poliarticular (JCA) and 176 psoriatic arthropathy (PsA); (b) the group of patients (189) who had been treated with intrasynovial infiltrations on three or four big joints. It consisted of 129 severe RA and 60 PsA patients who, in addition to three or four synovitis, showed at least one extrarticular manifestation of disease. The selection of these patients were to verify whether the intrasynovial Rifamycin SV really had the ability to induce the remission of systemic manifestations, reported by us several times [6,7]; (c) the group of patients (95), 27 RA and 68 PsA, in which only the small joints were treated; Each of 1,364 joints, 727 big and 637 small, had been infiltrated once a week for 10 weeks and all patients were followed for three years.

Patients with rheumatoid arthritis had been enrolled according to American College of Rheumatology (ACR) 1987 revised criteria [12]. The functional class was between I and III, according to Functional ACR criteria [13].

The age, considering the two groups of adults, RA and PsA, ranged from 17 to 70, and the mean disease duration was 2,6 years for

RA patients (range 8 months to 6 years) and 3.7 years for PsA patients (range 10 months to 10 years).

In JCA patients, the age ranged from 6 to 14 years (mean 7,2±3,96) and the duration of disease was 3,5 years (median).

The majority of rheumatoid patients had an effusion in both knees; in PsA patients, it was mostly unilateral; in JCA, it was present in 38 of 50 patients.

The X-ray pictures of the small joints of the hands and feet (PIPs, MCPs and MTPs) and wrist of RA patients and those of inflamed joints only of the other arthritides were evaluated. The radiographic assessment was based on the evaluation of the presence of erosions and narrowing of the joint at any of the small joints [14,15]. Joint space narrowing (greater than 50%) and the presence of erosions of any size (marginal or intraosseous) were considered irreversible radiographic lesions. For each of these lesions, we considered only the presence or the absence with no calculation of any radiological score. It is well known that the radiographic lesions in RA patients may appear after just a few months of disease [16,17].

## Treatments

The dosages of Rifamycin injected in joints were: knee and hip 100–150 mg in 4–5 mL; shoulder, elbow, and ankle 12.5–25 mg in one mL. The dose could be increased for very large effusions of knees. The total quantity of Rifamycin SV never exceeded 500mg/week. Joint effusion should be drained completely before injection, and Baker's cyst should be injected along with the knee.

The small joints of the hands, in addition to the wrist and any synovial cysts, could sometimes be treated in patients subjected to one big joint weekly infiltration; they could be infiltrated individually. In the first, the dose was 2.5–5 mg (0,1,0,2 mL) for each joint; in the wrist, it was 12.5 (0.5 mL); and in the cyst, it was 0.5–1 mL (12.5–25 mg).

The joints, big and small, were regularly distributed to alternative days (free on the weekend) in accord with guidelines before reported [7]. The alternative-day administration of this antibiotic prevents local and general serious reactions described in the course of intermittent therapy with Rifampicin for tuberculosis [18].

The Rifamycin SV used in our unit was the one contained in vials of 10 mL (250mg) for intravenous use, available only in the hospital. In their own home, the patients used the vials for intramuscular use (250 mg/3 mL), making appropriate dilutions with saline solution.

Rifamycin in contact with oxygen in the air is oxidized to Rifamycin S, which is more toxic and strongly antigenic, thus vials should be used immediately after they are opened.

Patients with early disease were often treated with NSAIDs and/or small doses of corticosteroids (< 7.5 mg/day of prednisone equivalent) that were left during the treatment.

## Statistical analysis

To analyze the difference between big and small joints in remission incidence and difference between RA and PsA patients taking into account the Rx damage, we used a Cochran-Mantel-Haenszel test. Statistical significance was set at < 0.05 for all tests. Statistical analyses were carried out using SAS version 9.2 (SAS Institute, Cary, NC).

**Results**

The incidence of synovitis remission in RA and PsA patients for big and small joints, taking into account the positivity and negativity of the Rx picture, are reported in Tables 1 and 2.

The big joints (knee, shoulder, ankle) of RA patients, radiographically negative, achieved remission in 69.7% (122/175), 48.8% (20/41), and 60.0% (12/20) of cases, whereas Rx-positive patients achieved remission in 9.3% (7/75), 7.48% (2/27) and 6.7% (2/30) of cases. The big joints with radiographic damage in patients with PsA achieved remission of synovitis, following the same respective order as the preceding, in 38.1% (8/21), 35.6% (16/45), and 45.0% (18/40) of cases, whereas the radiographically negative patients reached up to 93.0% (80/86), 90.5% (94/105), and 88.7% (55/62).

Among the big rheumatoid joints, the hip responds less well, perhaps because of the presence of synovial tissue surrounding the round ligament, which produces irreversible articular cartilage damage in very early stages.

As for the small joints, 5.9% (12/202) of the Rx-positive and 14.6% (14/96) of the Rx-negative underwent remission of synovitis in RA, and the difference is statistically significant ( $p < 0.013$ ).

In patients with PsA, remission was achieved in 80% of Rx-positive (105/120) and in 94.0% of Rx-negative (220/234) patients, and the difference was significant ( $p < .0001$ ) (Table 1).

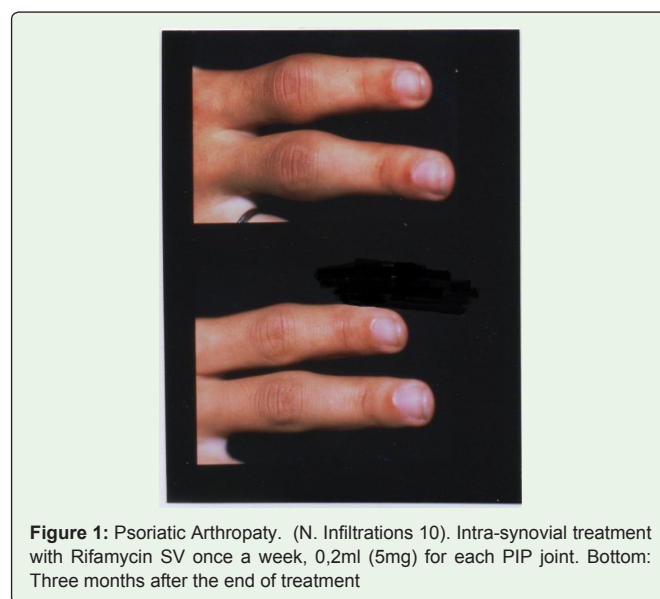Summarizing, the incidence of remission of individual synovitis is significantly higher in Rx-negative big joints of both RA and PsA patients, whereas the incidence in Rx-negative small joints is significantly higher only for PsA patients.

When we compared the incidence of synovitis remission between all big against all small joints, taking into account the Rx damage for both RA and PsA patients, we observed a statistically significant difference: The big joints achieved remission more frequently than small in RA patients ( $Chi = 59.86, p < .0001$ ), whereas the small joints

reached remission more frequently than big in PsA patients ( $Chi = 37.01, p < .0001$ ) (Table 2). Unlike RA, the remission of synovitis reaches high values in big joints and very high in the small joints of PsA patients (94%).

Finally, the comparison between the two arthritides, RA and PsA, for synovitis remission, taking into account the Rx damage, produced a difference in both for big ( $Chi = 78.22, p \leq .0001$ ) and small joints ( $Chi = 404.53, p \leq .0001$ ).

In general, the small joints of the RA respond less well than big ones to treatment with Rifamycin SV; those of the carpus respond very poorly to it. However, in a certain percentage of cases of both RA and of PsA patients, the Rx-negative synovitis of small joints may heal completely with a weekly infiltration of Rifamycin SV repeated for 10 weeks (Figure 1).



**Figure 1:** Psoriatic Arthropaty. (N. Infiltrations 10). Intra-synovial treatment with Rifamycin SV once a week, 0,2ml (5mg) for each PIP joint. Bottom: Three months after the end of treatment

**Table 1:** Intrasynovial infiltrations of Rifamycin SV in individual joints Follow up at 36 months of 658 patients with different arthritides.

	RA patients			PsA patients		
	Total n	Remission of synovitis n(%)	Chi square test Chi p-value	Total	Remission of synovitis ° n(%)	Chi square test Chi p-value
<b>KNEES</b>	250			107		
Rx positive	75	7 (9.3%)	76.34	21	8 (38.1%)	34.54
Rx negative	175	122 (69.7%)	<.0001	86	80 (93.0%)	<.0001
<b>SHOULDERS</b>	68			150		
Rx positive	27	2 (7.4%)	12.55	45	16 (35.6%)	46.60
Rx negative	41	20 (48.8%)	0.0004	105	94 (89.5%)	<.0001
<b>ANKLES</b>	50			102		
Rx positive	30	2 (6.7%)	16.59	40	18 (45.0%)	22.61
Rx negative	20	12 (60.0%)	<.0001	62	55 (88.7%)	<.0001
<b>SMALL JONTS*</b>	298			339		
Rx positive	202	12 (5.9%)	6.08	105	120 (80.0%)	17.66
Rx negative	96	14 (14.6%)	0.0136	234	220 (94.0%)	<.0001

\*Wrist, metacarpophalangeal, proximal interphalangeal, metatarsophalangeal joints. RA rheumatoid arthritis PsA psoriatic arthropaty. Chi square test to test association between positivity/negativity of X-ray and remission Chi square test to test association between positivity/negativity of Rx and remission of synovitis.

**Table 2:** Intrasynovial infiltrations of Rifamycin SV in big and small joints follow up at 36 months of 658 patients with different arthritides.

	RA patients			PsA patients		
	Total n	Remission of synovitis n (%)	Chi square Test* Chi p-value	Total n	Remission of synovitis n (%)	Chi square Test* Chi p-value
<b>BIG JOINTS</b>			59.86 <.0001			37.01 <.0001
Rx positive	132	11 (8.3%)		106	42 (39.6%)	
Rx negative	236	154 (65.3%)		253	229 (90.5%)	
<b>SMALL JOINTS</b>						
Rx positive	202	12 (5.9%)	105	120 (80.0%)		
Rx negative	96	14 (14.6%)	234	220 (94.0%)		

Chi square Test to test difference between Big and Small joints in remission (taking into account the positivity /negativity of Rx). RA rheumatoid arthritis, PsA psoriatic arthropathy. RA vs PsA for remission taking into account the positivity/negativity of Rx : Big joints: chi=78.22, p-value <.0001: Small joints: chi=404.53, p-value<.0001.

Children with JCA, in whom the inflamed big joints had been infiltrated, achieved remission of synovitis in 95% of cases, but the radiographic lesions of damaged joints evolved, along with a reduction of physical function.

Considering the systemic effects of intrasynovial Rifamycin SV, the remission of at least one extra-articular manifestation of PsA was reached in all 60 patients who had treated 3-4 large joints per week (Table 3); in two patients they totally remitted. Overall, 83% (67/81) of extrarticular signs went to remission whereas no effect on psoriatic plaques of skin was observed, at followup of 12 months.

As for the inflammation markers, the number of RA patients with baseline abnormal levels was reduced by 29% (37/129) for CRP and 25% (32/129) for ESR after 6 months and 32% (41/129) and 35% (45/129) at 12 months follow up, respectively.

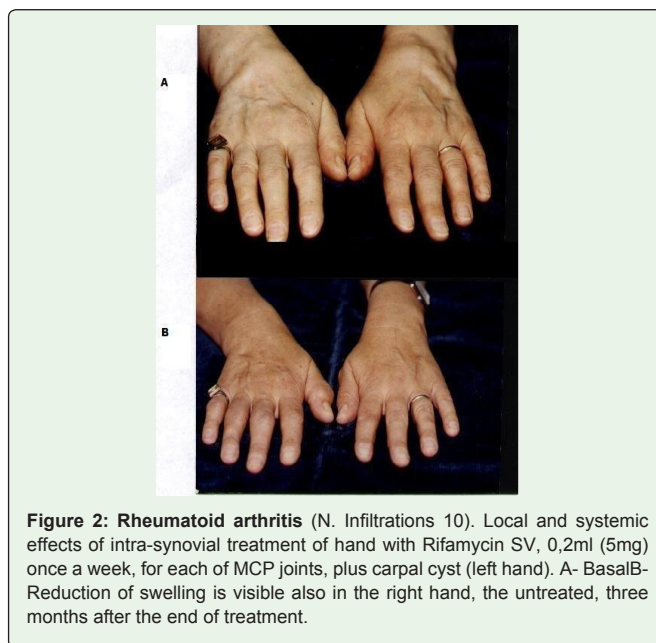
Systemic improvements, based on patient and investigator opinion, were reached by all psoriatic patients and by 72% (93/129) of RA patients. Clinical amelioration began at VI–VIII weeks and increased slowly until it became clear after the end of the 10 weeks of treatment. The patient was not always able to express an opinion on therapeutic efficacy, even when the reduction of swelling and the increase in range of motion were clear, because predominate local pain caused by infiltration with Rifamycin SV.

A demonstrative example that the systemic therapeutic effect of Rifamycin SV injected in joints is related to the migration of endosomal autoantigens is the case of synovial fluids in a patient in whom the treatment of most peripheral joints induced similar changes of synovial fluid mononuclear cells in both the treated and the untreated knee [4].

**Table 3:** Remission of extra-articular manifestations in 60 PsA patients weekly infiltrated with intrasynovial Rifamycin SV in 3-4 joints per10 weeks. Follow up at 12 months.

	N. patients with Ex M* at baseline	N. patients at 12 Mo follow up
Thenosynovitis of the hand	9 (13)	8 (4)
Plantar fasciitis	3 (3)	—
Enthesitis in different sites	17 (29)	15 (2)
Achilles tendinitis	3 (3)	2 (1)
Epicondylitis	19 (24)	17 (5)
Reduced axial motility	5 (5)	3 (2)
Episcleritis	4 (4)	—

\*PsA psoriatic arthropaty. \*Ex M, extrarticular manifestations which appeared by no more than three Mo, in parenthesis.



**Figure 2:** Rheumatoid arthritis (N. Infiltrations 10). Local and systemic effects of intra-synovial treatment of hand with Rifamycin SV, 0,2ml (5mg) once a week, for each of MCP joints, plus carpal cyst (left hand). A- BasalB-Reduction of swelling is visible also in the right hand, the untreated, three months after the end of treatment.

Moreover, the reduction of swelling in an untreated joint, after treatment of the opposite side, was observed in the knee, but it was even more evident in the MCP and PIP joints (Figure 2).

### Discussion

The results of statistical processing concerning the outcomes of arthritides have led us to conclude that the Rifamycin SV, repeatedly infiltrated by intrasynovial route, produces in the vast majority of cases therapeutic effects as resorption of effusion, gradual and slow reduction of pannus, significant reduction in joint pain, at all stages of the disease and in the most arthritides, even in advanced RA patients.

In general, the joints of larger dimensions respond better than the small joints, and the absence of radiographic damage is a prelude to a good therapeutic response.

The antisynovitis action is due to the anti-proliferative and cytolytic properties of this antibiotic.

The systemic effects of this treatment, which concerned the regression of extrarticular signs, the improvement of clinical symptomatology and the normalization of markers of inflammation in many patients occur very slowly, sometimes months after the end of 10 weeks of infiltration.



To our hypothesis, the mechanisms of the immune response that mediate the systemic effects are characterized by migration of endosomal autoantigens. Rifamycin SV, intrasynovially infiltrated, induces the lysis of antigen presenting cells and squeezes out all contents of the antigen-processing compartment in which there are also pathogenic epitopes, stripped of CLIP (the class II associated invariant chain peptide) [19] and completely free.

The arthritogenic epitope can directly reach the lymph nodes and the synovial membranes, through the lymph or transported by dendritic cells [20]; the synovial membranes are commonly considered a true secondary lymphoid organ [21]. The release of endosomal epitopes post-infiltration once a week and the repeated arrivals of autoantigens (almost every other day), coming from the infiltrations of the other joints (when the treatment is extended to 3 or 4 joints per week), probably causes the expansion of the regulatory T cells in each synovial membrane and any other inflamed area as a likely consequence of interaction of pathogenic epitopes with the binding site of the anti-idiotypic (paratope).

The changes detected in the hand and knee, both untreated, further support the hypothesis that the systemic therapeutic effect of Rifamycin SV injected in joints is related to the migration of endosomal autoantigens. The cells carrying the epitopes could have a preferential tropism toward joints of the same type.

The use of an intrasynovial route was essential to achieve the therapeutic effects. In fact, the oral administration of Rifampin, an active derivative of Rifamycin SV, at three times the intra-synovial dosage, was devoid of any therapeutic activity [22].

But, our recent studies reported that this route may successfully be replaced with the direct subcutaneous administration of endosomal extract (ultrafiltrate) in the autologous vaccination of rheumatoid patients; in addition, the presence of pathogenic epitopes in the endosomal ultrafiltrate was evidenced by significant upregulation of a marker for T-regulatory cells when it was added to PBMCs culture of RA patients [23].

In conclusion, the results of this retrospective study confirm that the intrasynovial route of administration, through the release of endosomal contents from antigen presenting cells, allowed Rifamycin SV to implement an endogenous, autonomic and specific, immunotherapy; a novel immunotherapy modality which bypassed the impediment of the ignorance and unavailability of pathogenic autoantigens.

Rifamycin SV injected in the joints is a therapeutic modality that can hardly have an extensive practical application, considering the severe pain following the infiltration. It would be beneficial if the pharmaceutical industry, with the help of new technologies, could mitigate, if not completely overcome, this great impasse.

### Adverse Effects

The most important side effect of intrasynovial treatment is the deep local pain induced by Rifamycin SV, lasting 3 to 10 min after infiltration.

The other side effects are minor (< 0.5%) and usually subside with interruption of treatment: diarrhea, increase of liver enzymes, allergy, and etc.

Local reactions at treated joints in patients with history of allergy remit with the administration of antihistamines.

Furthermore, frequent interruptions of the treatment cycle favor local hypersensitivity reactions that are significantly less frequent when Rifamycin SV is administered on alternate days or 5 days a week (free on the weekend) in different joints.

### Conclusions

The poli-intrasynovial infiltration of Rifamycin SV produces several clinical effects, which range from the remission of the individual synovitis to the remission of some extrarticular manifestations and normalization of inflammation markers of arthritides.

In patients (374) who underwent infiltration on one big joint the remission of individual synovitis was significantly higher in big compared to small joints in RA patients, whereas the incidence was lower in big compared to small joints in PsA patients. The comparison between Rx-positive and Rx-negative is highly significant in all big joints and in both arthritides. Children with JCA, achieved remission of synovitis in 90% of cases, but the radiographic lesions of damaged joints evolved, along with a reduction of physical function.

The remission of at least one extra-articular manifestations has been observed in PsA patients who underwent infiltration in 3 or 4 different big joints per week.

As for the inflammation markers, the number of RA patients with baseline abnormal levels was reduced by 29% (37/129) for CRP and 25% (32/129) for ESR after 6 months and 32% (41/129) and 35% (45/129) at 12 months followup, respectively.

The therapeutic effects of intrasynovial Rifamycin SV established very slowly during and, mainly, after the end of infiltrations.

The mechanisms of the immune response that mediate the systemic effects are characterized by migration of endosomal autoantigens, not tied to any HLA-DR molecule, which cause the expansion of the regulatory T cells as a likely consequence of the interaction with the binding site of the idiotypic (paratope). TREG cells suppress the effector immune response, contributing to remission of some systemic features of arthritides.

The most important side effect of intrasynovial treatment is the deep local pain induced by Rifamycin SV, lasting 3 to 10 min, after infiltration which is an insurmountable obstacle to practical application of this therapeutic modality of arthritides.

### Competing Interests

The authors declare that the research was conducted in the absence of any conflict of interest. None of those who produce or market the Rifamycin SV had a role in the study design, interpretation of the data or the writing of manuscript. There were no financial support to our work

### Acknowledgments

We would like to thank Eliana Rulli MSc, istituto di ricerche farmacologiche "Mario Negri" for the assistance in statistical analysis, Donata Dell'Acqua PhD for technical assistance, and Facchetti Anna for secretarial work.

## Authors Contributions

Study conception and design, Caruso Innocenzo, Acquisition of data, Cazzola, Santandrea, Caruso Enzo Massimo, Caruso Innocenzo, Analysis and interpretation of data, Cazzola, Montrone, Caruso Enzo Massimo.

## References

1. Caruso I, Montrone F, Fumagalli M, Patrono C, Santandrea S, Gandini M. Rheumatoid knee synovitis successfully treated with intra-articular Rifamycin SV. *Ann Rheum Dis.* 1982; 41: 232-236.
2. Lindblad S, Hedfors E, Malmorsg A. Rifamycin SV in local treatment of synovitis. A clinical, arthroscopic and pharmacologic evaluation. *J Rheumatology.* 1985; 12: 900-903.
3. Blyth T, Stirling A, Coote J, Land D, Hunter A. Injection of the Rheumatoid Knee: Does intra-articular methotrexate or rifampicin add to the benefit of triamcinolone hexacetonide? *Br J Rheumatol* 1998; 37: 770-772.
4. Caruso I, Montrone F, Fumagalli M, Patrono C, Boselli P, Scrollini F. Rifamycin SV in the treatment of knee synovitis. *Orthopedics.* 1982; 5: 1336-1343.
5. Cottafava F, Pinelli G, Freschi PA, Nardelli E, Ginocchio L, Bertolotto M et al. Sinovite reumatoide al ginocchio trattata con buon risultato con Rifamicina SV intrarticolare. *Min Ped.* 1982; 34: 33-37.
6. Caruso I, Principi N, D'Urbino G, Santandrea S, Boccassini L, Montrone F et al. Rifamycin SV administered by intra-articular infiltrations shows disease modifying activity in patients with pauci and polyarticular juvenile rheumatoid arthritis. *J Int Med Res.* 1993; 21: 243-256.
7. Caruso I. Twenty years of experience with intra-articular Rifamycin for chronic arthritides. *J Int Med Res.* 1997; 25: 307-317.
8. Anderton S, Burkhart C, Metzler B, Wraith D. Mechanisms of central and peripheral T-cell tolerance: lessons from experimental models of multiple sclerosis. *Immunol rev.* 1999; 169: 123-37.
9. Racke MK, Critchfield JM, Quigley I. Intravenous antigen administration as a therapy for autoimmune demyelinating disease. *Ann Neural.* 1996; 39: 46-56.
10. Piaggio E, Mars LT, Cassanm C, Cabarrocas J, Hofstatter M, Desbois S, et al. Multimerized T cell epitopes protect from experimental autoimmune diabetes by inducing dominant tolerance. *Proc Natl Acad Sci USA.* 2007; 104: 9393-9398.
11. Tisch R, Wanb B, Serreze DV. Induction of glutamic acid decarboxylase 65-specific Th2 cells and suppression of autoimmune diabetes at late stage of disease is epitope dependent. *J Immunol.* 1999; 63: 1178-1187.
12. Arnett FC, Edworthy SM, Bloch DA, McShane DJ, Fries JF, Cooper NS et al. The American Rheumatism Association 1987 revised criteria for the classification of rheumatoid arthritis. *Arthritis Rheum.* 1988; 31: 315-324.
13. Hochberg MC, Chang RW, Dwosh I, Lindsey S, Pincus T, Wolfe F. The American College of Rheumatology 1991 revised criteria for the classification of global functional status in rheumatoid. *Arthritis Rheum.* 1992; 35: 498-502.
14. Sharp JT, Lidsky MD, Collins LC, Moreland J. Methods of scoring the progression of radiologic changes in rheumatoid arthritis. Correlation of radiologic, clinical and laboratory abnormalities. *The Journal of Rheumatology* 1990; 17: 1263-1267.
15. Sharp JT, Bluhm GB, Brook A. Reproducibility of multiple-observer scoring of radiological abnormalities in the hand and wrist of patients with rheumatoid arthritis. *Arthritis Rheum.* 1985; 28: 16-24.
16. Machold KP, Stamm TA, Nell VP, Pflugbeil S, Aletaha D, Steiner G et al. Very recent onset rheumatoid arthritis: clinical and serological patient characteristics associated with radiographic progression over the first years of disease. *Rheumatology (Oxford).* 2007; 46: 342-349.
17. Caruso I, Santandrea S, Sarzi Puttini PC, Boccassini L, Montrone F, Cazzola M et al. Azzolini V Segre D. Clinical laboratory and radiographic features in early rheumatoid arthritis. *J Rheumatology.* 1990; 17: 1263-1267.
18. Aquinas M, Allan WG, Horsfall PA, Jenkins PK, Hung-Yan W, Girling D et al. Adverse reactions to daily and intermittent rifampicin regimens for pulmonary tuberculosis in Hong Kong. *Br Med J.* 1972; 1: 765-771.
19. Roche PA and Kazuyuki Furuta. The ins and outs of MHC class II-mediated antigen processing and presentation. *Nature Reviews Immunology.* 2015; 15: 203-216.
20. Itano AA & Jenkis MK. Antigen presentation to naive CD4T cells in the lymphnode. *Nature Immunol.* 2003; 4: 733-739.
21. Lipsky Peter L. Why does rheumatoid arthritis involve the joints? *N Engl J Med.* 2007; 356; 23: 2419-2420
22. Caruso I, Cazzola M, Santandrea S. Clinical improvement in ankylosing spondylitis with rifamycin SV infiltrations of peripheral joints. *J Int Med Res.* 1992; 20: 171-181.
23. Caruso I, Santandrea S, Gismondo M, Lombardi A, Montrone F, Caruso EM et al. Vaccination with endosomal unknown epitopes produces therapeutic response in rheumatoid arthritis patients and modulates adjuvant arthritis of rats. *J. Transl Med.* 2016; 14: 162. DOI 10.1186/s12967-0908-7.