

Carcinoma with Medullary Features of the Nipple: A Case Report of an Infrequent Breast Tumor with a Rare Presentation

Raquel Civolani Marques Fernandes^{1*}, Felipe Andreotta Cavagna¹, Thais Menezes Cardoso da Cruz¹, Thainá Marina Furlanetti¹ and Luiz Henrique Gebrim^{1,2}

¹Department of Pathology of Perola Byington Hospital, Women's Health Reference Center, Brazil

²Federal University of Sao Paulo, Brazil

Article Information

Received date: Sep 01, 2017

Accepted date: Sep 25, 2017

Published date: Sep 27, 2017

*Corresponding author

Raquel Civolani Marques Fernandes,
Department of Pathology of Perola
Byington Hospital, Av. Brigadeiro
LuisAntonio, 683/ 1 andar/ Patologia,
São Paulo- 01317-000, Brazil,
Tel: +55-11- 984154321;
Email: raquel.c.fernandes@me.com

Distributed under Creative Commons
CC-BY 4.0

Keywords Breast carcinoma; Medullary
features; Nipple; Triple negative

Abstract

The aim of this report is to relate an unusual clinical presentation of breast carcinoma with medullary features. A Japanese patient aged 57 complained of right nipple lump with progressive growth over the past six months. Upon physical examination, we found no nodules in the breast, except for a pedunculated tumor from her right nipple. The breast ultrasonography revealed an irregular, not circumscribed nipple lump. The mammogram did not show any pathologic findings. The biopsy confirmed a triple negative carcinoma with medullary features (MCF). Even though a case report on invasive ductal carcinoma regarding the same clinical scenario had occurred in 1996, a MCF of the nipple without any radiologic or clinical findings in the parenchyma has not been described until the present date.

Introduction

Nipple pedunculated tumors are uncommon breast lesions. Normally, when the physician faces a patient with a nipple tumor without any clinical or imaging parenchymal findings, the initial hypothesis should be a benign lesion, such as nipple adenoma or pyogenic granuloma. Carcinomas are often related to alterations in breast parenchyma, apart from Paget disease, which is frequent, associated with eczematous and/or ulcerated lesion.

We present a case report of an exophytic nipple tumor without any radiologic or clinical findings in the parenchyma. The incisional biopsy revealed a triple negative carcinoma with medullary features (MCF). This case demonstrates another important differential diagnosis which should be considered when dealing with nipple lesions.

Case Report

A 57-year-old Japanese woman presented a pedunculated lesion on her right nipple, which had been growing steadily for six months. The patient has drug-controlled hypertension and denies other pathologies, addictions or breast cancer family history.

During a physical examination, we observed a 15,0mm solid, erythematous, hardened, painless, pedunculated nodule growing from her right nipple (figure 1). There were no discharges of any kind, ulcers or eczema. Similarly, no other alterations were found during the physical examination of the breasts and the clinical diagnosis was of adenoma of the nipple.

The mammogram did not show any pathologic findings (figure 2). The ultrasound showed an irregular nodule with circumscribed margins and posterior acoustic shadow, measuring 13,0 x 9,0 x 13,0 mm located at the right breast nipple (figure 3).

The incisional biopsy was performed and a MCF, histological grade 3 (Nottingham) [1] was diagnosed. The immunohistochemistry profile lacked expression of Estrogen Receptor (ER); Progesterone Receptor (PR) and Human Epidermal Growth Factor Receptor 2 negative (HER2) with high index of mitotic rate (80%).

Although the tumor was staged as T4bN0M0 due to skin involvement, considering that the patient did not present any other clinical or radiological changes other than the nipple lesion, we decided to perform conservative surgical treatment. The patient underwent a central quadrantectomy with sentinel node biopsy two months after. By that time, the tumor had quadruplicated (figure 4), but no compromised nodes or distant metastases were found.

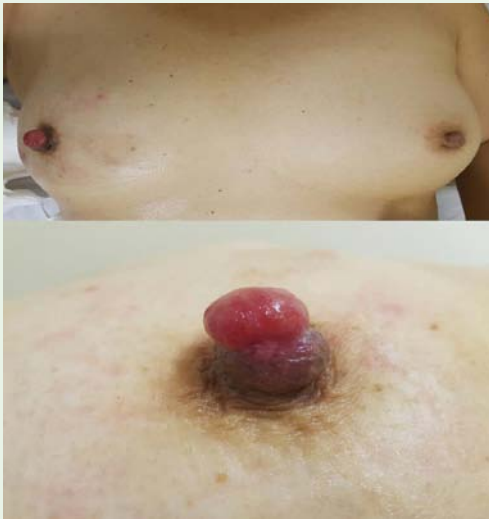

Figure 1: Physical examination of right breast shows a solid pedunculated nodule growing from her right nipple.

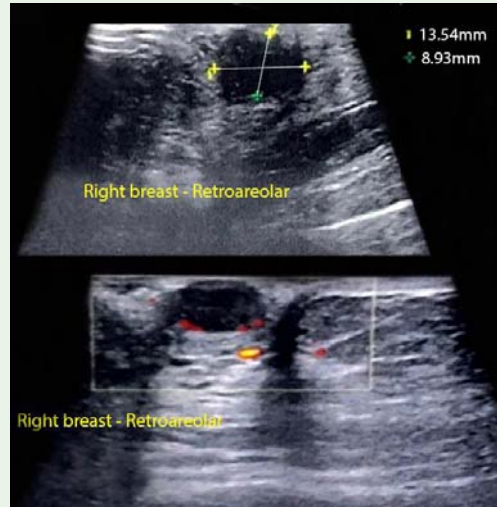


Figure 3: Ultrasonography: an irregular nodule with circumscribed margins and posterior acoustic shadow on the right breast nipple.

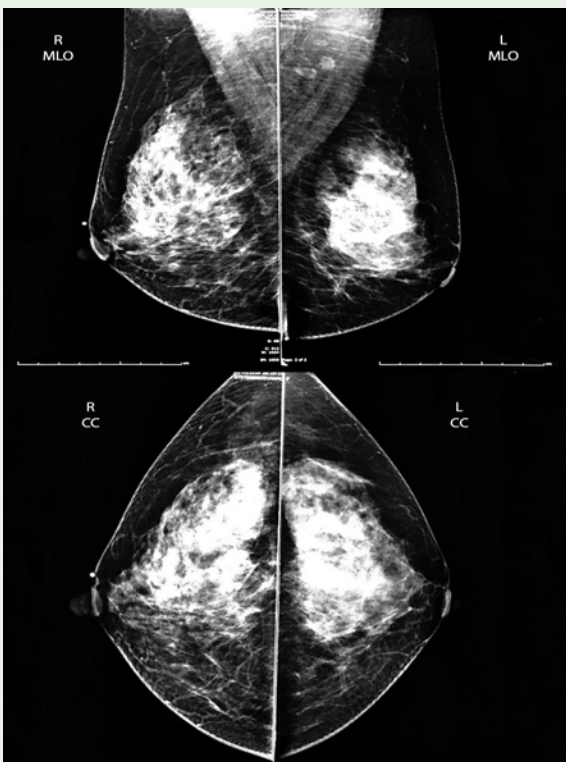


Figure 2: Mammogram: no pathologic findings on either breast or metallic clip in the right nipple.

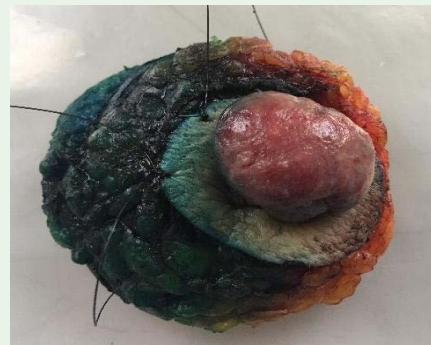

Figure 4: Surgical specimen: the tumor fully replaced the nipple.

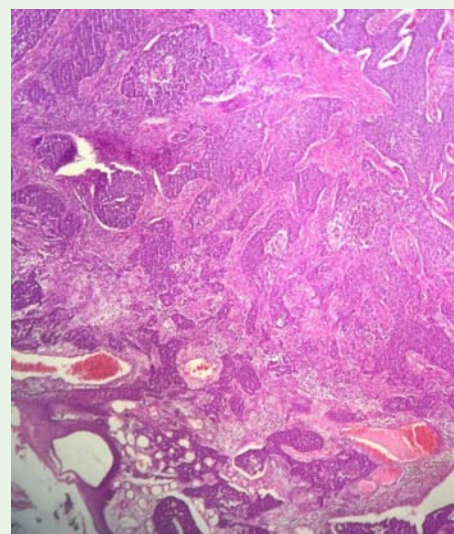


Figure 5: (Photomicrography HE, 40X) Histological appearance of a surgical tissue specimen from the affected nipple. The tumor was composed of syncytial blocks permeated by dense inflammatory infiltrate.

Triple negative MCF was confirmed through a surgical specimen analysis. A broader immunohistochemical panel (table 1) was performed to confirm breast origin (CK7 and GATA3 positive) and rule out different types of tumors, such as skin appendage carcinoma, squamous carcinoma, and basocellular carcinoma.

The patient proceeded to complete her treatment with chemotherapy and radiotherapy.

Table 1: Immunoprofile.

Marker	Results
ER	negative
PR	negative
HER2	negative
Ki67	positive (80%)
GATA3	positive
CK7	positive
CK20	negative
Androgen receptor	negative
BerEP4	negative
P63	negative
P53	positive (focal)
CK5/6	negative
CEA policlonal	negative
CK14	negative
EGFR	negative
Uroplakin	negative

Discussion

Considering the clinical presentation, different diagnostic hypotheses could be raised prior the biopsy. Initially, our first hypothesis regarded nipple adenoma because of the apparent benign clinical characteristic.

Nipple adenoma is a rare benign variant of intraductal papilloma, most commonly presented as a nipple mass or in duration, but which can also lead to erosion, bloody discharge, and itching [2]. It can clinically resemble both malignant lesions like Paget's disease and benign conditions like dermatitis of the nipple, requiring a biopsy to confirm the diagnosis [3].

Another possible differential diagnosis would be pyogenic granuloma with vascular lesion of the skin and mucous membranes, generally affecting regions submitted to frequent trauma. It is more frequent, benign, and usually presents as a solitary, rapidly grown papule or polyp which bleeds easily after minor trauma [4].

Paget's disease of the breast is an uncommon presentation of breast malignancy, accounting for 1–3% of all the breast tumors, with its peak incidence between 50 and 60 years old. Clinically, it is characterized as nipple or areolar erythema, eczema, ulceration, bleeding and itching, which can be mistaken for nipple eczema and have its diagnosis delayed [5]. In contrast to our patient, Paget's disease is rarely presented with a pedunculated tumor, more often being an ulcerated lesion, first on the nipple and subsequently spreading to the areola and parenchyma.

Skin tags such as acrochordon are benign, small, soft, pedunculated or warty tumors [6] which can affect the nipples. Our patient's lesion was neither soft nor small and had an erythematous aspect; therefore, this hypothesis was not long considered.

Histologically, the biopsy as well as the surgical specimen revealed an epithelial malignant neoplasm composed of syncytial blocks (figure 5) permeated by dense inflammatory infiltrate with areas

of necrosis of geographical pattern placed on the superficial breast parenchyma contiguous with hypodermis, dermis and epidermis, forming an exophytic ulcerated mass. Neither intraepithelial ductal nor intraepidermal pagetoid component was found.

Classically, the following criteria were used to define classic Medullary Carcinomas (MC): syncytial architecture in > 75% of the tumor mass, pushing margins, lack of tubular differentiation, a prominent lymphoplasmacytic stroma infiltrate, pleomorphic high-grade nuclear containing one or several nucleoli and numerous mitosis. The terms "Atypical Medullary Carcinoma" (atypical MC) and Invasive Carcinoma no special type with medullary features (Invasive Carcinoma NST with medullary features) have been proposed for tumors that do not fulfil all these criteria. Regarding the current WHO classification, it is recommended that MC, atypical MC and Invasive Carcinoma NST with medullary features be grouped within the category of MCF (7). These tumors are triple negative with variably expression of keratins 5/6 and 14 and EGFR, considered by some authors a subtype of basal-like carcinomas. [8-10]. The lymphoid infiltrates show predominance of CD-3 T lymphocytes [11].

The immunohistochemistry profile of our case lacked expression of ER; PR and HER2 with high index of mitotic rate (80%). There was no expression for other basal markers. Diffuse expression of cytokeratin 7 and GATA 3 suggesting breast carcinoma origin. The lack of expression of androgen receptor, p63 protein and BerEP4 ruled out skin tumors as skin appendage carcinoma, squamous carcinoma and basocellular carcinoma (table 1).

Despite being rare (<1% of invasive breast carcinomas), this clinical presentation of the MCF has not been described (to our knowledge) in literature until the present date. Even with a similar case report in 1996 by Ohsum S. and colleagues [12], their tumor microscopically showed findings of a more differentiated carcinoma with tubular formation, diagnosed as Ductal Invasive Carcinoma, accompanied by *in situ* carcinoma with expression of ER and PR, while in our case the tumor was a triple negative Carcinoma with Medullary Features without any *in situ* component.

This case raises the possibility to include a differential diagnosis on the clinical practice when confronted with nipple exophytic tumor upon physical examination.

References

1. Elston CW, Ellis IO. Pathological prognostic factors in breast cancer. I. The value of histological grade in breast cancer: experience from a large study with long-term follow-up. *Histopathology*. 2002; 41: 154-161.
2. Kijima Y, Matsukita S, Yoshinaka H, Owaki T, Aikou T. Adenoma of the nipple: report of a case. *Breast Cancer*. 2006; 13: 95-99.
3. Pasquali P, Freitas-Martinez A, Fortuño A. Nipple Adenoma: New Images and Cryosurgery Treatment. *Breast J*. 2016; 22: 584-585.
4. Caliskan M, Gatti G, Sosnovskikh I, Rotmensz N, Botteri E, Musmeci S, et al. Paget's disease of the breast: the experience of the European Institute of Oncology and review of the literature. *Breast Cancer Res Treat*. 2008; 112: 513-521.
5. Nakai N, Itoh R, Katoh N. Skin tag of the nipple with blister formation: two case reports. *J Dermatol*. 2013; 40: 946-947.

6. Zaballos P, Llambrich A, Cuéllar F, Puig S, Malveyh J. Dermoscopic findings in pyogenic granuloma. *Br J Dermatol*. 2006; 154: 1108-1111.
7. Lakhani SR, Ellis IO, Schnitt SJ, Tan PH, Van de Vijver MJ. WHO Classification of Tumours of the Breast. IARC: Lyon. 2012.
8. Rodríguez-Pinilla SM, Rodríguez-Gil Y, Moreno-Bueno G, Sarrió D, Martín-Guijarro Mdel C, Hernandez L, et al. Sporadic invasive breast carcinomas with medullary features display a basal-like phenotype: an immunohistochemical and gene amplification study. *Am J Clin Pathol*. 2007; 31: 501-508.
9. Nielsen TO, Hsu FD, Jensen K, Cheang M, Karaca G, Hu Z, et al. Immunohistochemical and clinical characterization of the basal-like subtype of invasive breast carcinoma. *Clin Cancer Res*. 2004; 10: 5367-5374.
10. Fernandes RCM, Bevilacqua JLB, Soare IC, Siqueira SA, Pires L, Hegg R, et al. Coordinated expression of ER, PR and HER2 define different prognostic subtypes among poorly differentiated breast carcinomas. *Histopathology*. 2009; 55: 346-352.
11. Guo X, Fan Y, Lang R, Gu F, Chen L, Cui L, et al. Tumor infiltrating lymphocytes differ in invasive micropapillary carcinoma and medullary carcinoma of breast. *Mod Pathol*. 2008; 21: 1101-1107.
12. Ohsum S, Nozaki I, Takashima S, Manda K. Invasive Ductal Carcinoma of the Nipple: A case report. *Breast Cancer*. 1996; 3: 215-218.