



Metastatic Myxoid Leiomyosarcoma of the Uterus: A Case Report of a Diagnostically Challenging Tumor with Literature Review and Proposed Diagnostic Algorithm

Iraj Zanair Afzal^{1*}, Maham Afzal², Irteza Afzal¹, Phillip Pearson¹, Emory Newkirk¹, Edmond Fahoury¹, Hilary Eskander¹, Kirk Sheplay¹, and Mohamed Aziz¹

¹American University of the Caribbean, 1 University Drive at Jordan Road Cupecoy, St. Maarten

²York University, York, Canada

Abstract

Myxoid leiomyosarcoma is often not included in the differential diagnosis of myxoid malignancies outside the uterus and, as a result, may be underrecognized or misdiagnosed. We present a case of a 63-year-old woman who presented with multiple abdominal/pelvic, omental and mesenteric masses. The patient presented with an infiltrating mesenteric tumor, but had a history of prior uterine leiomyosarcoma removed 4 months before current presentation. Review of prior uterine leiomyosarcoma proved to be of the rare myxoid variant and current tumor was considered metastatic leiomyosarcoma to the mesentery. Pathologists should have increased awareness of this variant of leiomyosarcoma. This paper explores the various markers that can be used to diagnose myxoid leiomyosarcomas against other possible benign and malignant myxoid tumors such as myxoid leiomyomas, inflammatory myofibroblastic tumor, extraskeletal myxoid chondrosarcoma, myxoid liposarcoma, conventional leiomyosarcomas, and endodermal stromal tumors, among others. An algorithm is proposed to assist in definitive diagnosis.

Keywords: Myxoid: leiomyosarcoma: leiomyoma: Algorithm: Endodermal: Stromal: Tumor: Inflammatory: Lymphoplasmic: Infiltrate: Colloidal: Iron: Metastasis: Sarcoma

Abbreviations

LMS: Leiomyosarcoma. **MLMS:** Myxoid Leiomyosarcoma. **TCN:** Tumor Cell Necrosis. **SMA:** Smooth Muscle Actin. **IMT:** Inflammatory Myofibroblastic Tumor. **EST:** Endometrial Stromal Tumor. **IHC:** Immunohistochemistry. **FNA:** Fine Needle Aspiration

Introduction

Myxoid leiomyosarcoma (MLMS) is an uncommon tumor, which although previously well described in the uterus, is recognized to a lesser extent at other sites. A myxoid variant of leiomyosarcoma was originally described in the uterus, where it is uncommon, but well documented. Since that time a small number of additional cases of MLMS have been published, with several cases occurring in the female external genital

region. Rare cases of MLMS have also been described in the soft tissue, ovary, prostate, stomach, esophagus, maxillary antrum, parotid gland, and heart [1]. MLMS is defined as a tumor that exhibit light microscopic and immunohistochemical evidence of smooth muscle differentiation and contains myxoid stroma in at least 60% of the tumor examined microscopically. Myxoid leiomyosarcoma is often not included in the differential diagnosis of myxoid malignancies outside the uterus and, as a result, may be under recognized or misdiagnosed. This paper describes a case of MLMS occurring in the mesentery that eventually was found to be a metastatic tumor from the uterus. Key markers such as Ki67, p53, p16, PHH2, and HMGA2 are often positive in MLMS [5]. Furthermore, expression of these markers differs based on tumor size and therefore tumor size measurements can be used in the diagnostic phase as well [1].

Case Presentation

We present a case of 63-year-old female, with a past medical history of a low-grade uterine leiomyosarcoma, treated with hysterectomy and no postoperative chemotherapy or radiation. The low-grade leiomyosarcoma was confined to the myometrium, and measuring 12.5 cm in greatest dimension. No lymphovascular invasion was noted, and all dissected twelve lymph nodes were negative for metastasis. Four months later, repeated CT demonstrated multiple new abdominal and pelvic masses, possibly representing metastases. The largest mass measured 3.7 x 3.4 x 2.4 cm at the lower abdominal quadrant. Fine needle aspiration (FNA) with cellblock preparation was done from the largest mass for quick evaluation and revealed malignant tumor cells arranged as bundles of smooth muscle cells in a myxoid

Submitted: 17 September, 2020 | **Accepted:** 30 September, 2020 | **Published:** 02 October, 2020

***Corresponding author:** Iraj Zanair Afzal. 1American University of the Caribbean, 1 University Drive at Jordan Road Cupecoy, St. Maarten, e-mail: iraj.afz94@gmail.com

Copyright: © 2020 Hutcherson EK, et al. This is an open-access article distributed under the terms of the Creative Commons Attribution License, which permits unrestricted use, distribution, and reproduction in any medium, provided the original author and source are credited.

Citation: Afzal IZ, Afzal M, Afzal I, Pearson P, Newkirk E, et al. (2020) Metastatic Myxoid Leiomyosarcoma of the Uterus: A Case Report of a Diagnostically Challenging Tumor with Literature Review and Proposed Diagnostic Algorithm. SM J Clin Pathol 4: 5.



background. This was followed by incisional tissue biopsy, which confirmed the features noted in the cytology FNA sampling.

The tumor was predominantly (>75%) myxoid and displayed spectrum of histomorphologic patterns. Cellular histomorphologic details were in form of mixed low- and high-grade features with moderate cellular atypia, minimal necrosis and mitosis. In scattered areas, the tumor displayed storiform pattern with myxofibrosarcoma-like morphology (**Figure 1A**), and in many other areas, the cells were arranged in a cord-like pattern, reminiscent of extraskeletal myxoid chondrosarcoma (**Figure 1B**). In addition, other areas of the tumor displayed a fascicular pattern, reminiscent of leiomyosarcoma (LMS) (**Figure 1C**). There were also scattered highly pleomorphic bizarre cells within the myxoid background (**Figure 1D**). Immunohistochemistry studies showed positive vimentin and strong positivity for smooth muscle marker desmin. The tumor cells were negative for myogenin, melanocytic markers, lymphoid markers, and epithelial markers, confirming the diagnosis of leiomyosarcoma. Review of prior uterine leiomyosarcoma proved to be of the rare myxoid variant and current tumor was considered a metastatic tumor to the mesentery. Within eight months of initial presentation with uterine leiomyosarcoma, the tumor has already spread to the omentum, diaphragm, and liver capsule, indicating aggressive behavior of this variant of tumor contrary to prior concept of a less aggressive variant.

Due to extensive abdominal metastasis, the patient was not a candidate for surgical intervention and was treated with combined chemotherapy including doxorubicin and ifosfamide,

in addition to radiation therapy. She was stable for 2 years with no evidence of metastasis or recurrence. After 2 years, metastasis to the lung was identified and the patient's general condition started to deteriorate. She received additional chemotherapy and radiation but expired seven months later due to wide spread metastasis and multiple organ failure.

Discussion

MLMS displays a wide spectrum of histomorphologic patterns, as seen in our case. The differential diagnosis is broad and includes a variety of benign and malignant tumors with myxoid features. The myxoid feature of the matrix can be confirmed through the acid mucopolysaccharide stain (colloidal iron). Benign tumors may include entities such as schwannoma, nodular fasciitis, myxoid leiomyoma, and inflammatory myofibroblastic tumor (IMT), among others. Morphological characteristics that distinguish myxoid leiomyosarcomas from myxoid leiomyomas include tumour cell necrosis (TCN), mitotic figures, and nuclear atypia [5].

Myxoid leiomyosarcomas clinical behaviour is of question as some reports cite it to be an aggressive variant of leiomyosarcomas, while others cite it to be slow growing (in reference to conventional leiomyosarcomas) [1]. Furthermore, due to the rarity of the myxoid variant, not enough clinical data exists to predict MLMS behaviour. However, a population-based study in Norway concluded that MLMS patients had a 5-year survival of 73%, which is more favourable than the conventional leiomyosarcoma's 49% [2]. The main concern for this statement is that there is a sample size bias since this study had included

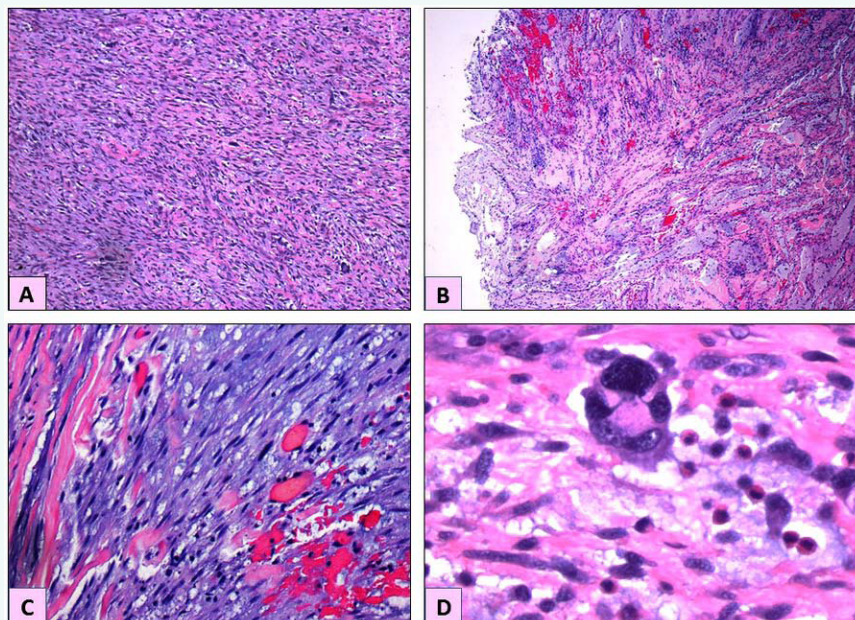


Figure 1 Microscopic examination of the resected tumor.

1A: In scattered areas, the tumor displays a storiform pattern with myxofibrosarcoma-like morphology. H&E X20

1B: In many other areas, the tumor cells were arranged in a cord-like pattern, reminiscent of extraskeletal myxoid chondrosarcoma. H&E X20

1C: Other areas of the tumor displayed a fascicular pattern, reminiscent of leiomyosarcoma with prominent myxoid background. H&E X60

1D: There were also scattered highly pleomorphic bizarre cells scattered within the myxoid background. H&E X100



18 cases of MLMS (18/419 patients), while for conventional leiomyosarcomas the sample size was 223/419 [2].

Definitive histomorphologic diagnosis of MLM can be challenging. The reason is that MLMS do not follow conventional grading and staging criteria of TCN, mitotic figures, and cytological atypia. These criteria work well with conventional leiomyosarcomas, but not as well with MLMS. High mitotic activity is an important criterion for differentiating leiomyosarcoma from other benign tumors such as leiomyoma. Necrosis may be seen in high-grade tumors and the threshold number of mitotic figures per high power field that characterizes malignant growth may vary depending on the location from which the tumor arises [8]. Depending on where the sample is being analyzed, myxoid areas typically show a low mitotic count of 3-4/HPF (High Power

Field) while solid areas can show 10-12/HPF [3, 7]. Furthermore, MLMS behavior is difficult to predict as the relationship between mitotic figures/HPF and tumor recurrence/size are not strongly correlated. Most conventional tumors show increasing tumor size/chances of recurrence as mitotic figures/HPF increase, but MLMS do not exhibit this behavior, contributing to their ability to deviate from the norm; **Figures 3 and 4** exemplify this based on data from Parra-Herran et al [4]. MLMS do show a positive correlation with increasing tumor size and recurrence in patients (Figure 2). MLMS nuclear atypia is variable with myxoid regions showing more prominent atypia than non-myxoid regions [6].

This forces pathologists to pursue other markers of malignancy, such as capsular invasion, invasive borders, lymphovascular invasion, and other malignant features. Most of

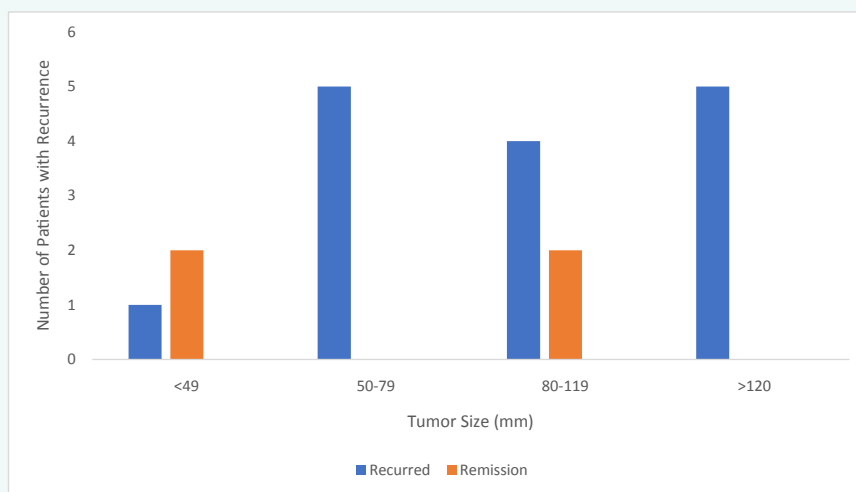


Figure 2 Relationship Between Tumor Size (mm) and Number of Patients with Recurrence of MLM.

This figure shows that the odds of a tumor recurring increase if the tumor size was initially large. Data summarized from Parra-Herran et al [4]

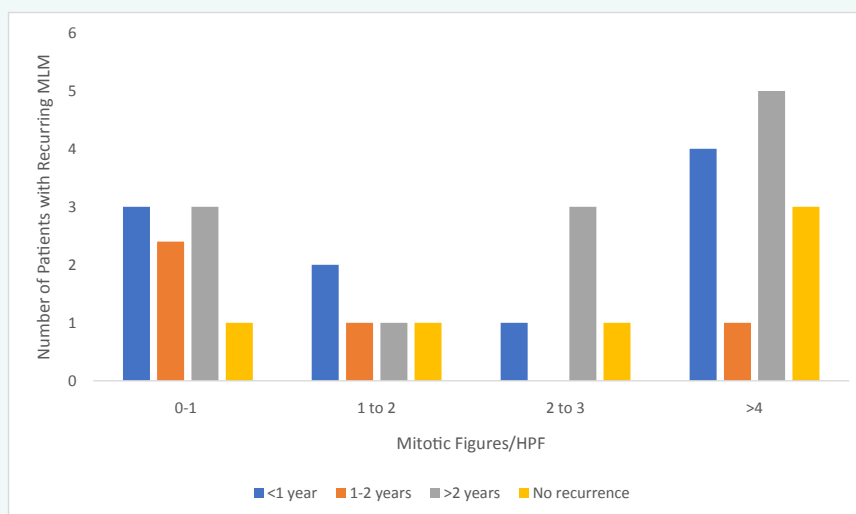


Figure 3 Relationship Between Mitotic Figures/HPF and Number of Patients with Recurring MLM.

This figure shows that there is no direct correlation between mitotic figures/HPF and tumor recurrence. Data summarized from Parra-Herran et al [4]

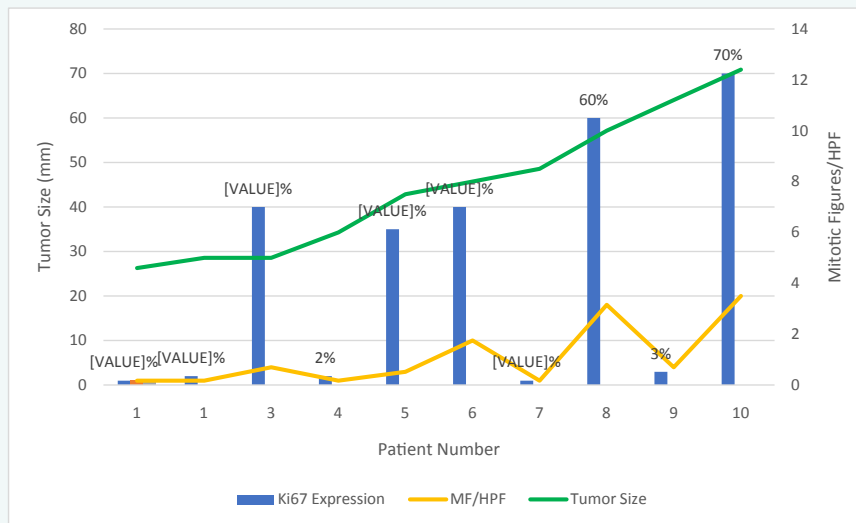


Figure 4 Relationship between Ki67 Expression (%), Tumor Size (mm), and Mitotic Figures/HPF. This figure shows that Ki67 expression has a weak correlation with tumor size, while there is no clear relationship between tumor size and mitotic figures/HPF. Data summarized from Parra-Herran et. al [4]

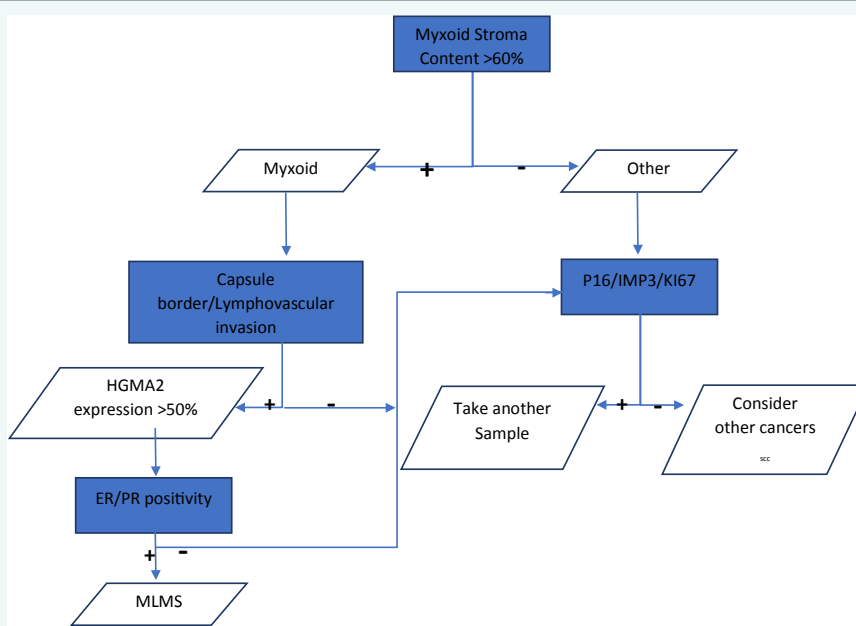


Figure 5 Proposed Algorithm to Assist in Diagnosing Myxoid Leiomyosarcomas. Initial diagnosis should begin by studying stromal content, followed up by capsule border/lymphovascular invasion, and lastly via IHC, particularly HGMA2 expression and ER/PR positivity

MLMS exhibit capsular invasion, but lymphovascular invasion is not a common feature. Parra-Herran et al were able to show that 24/25 of their MLMS exhibited an invasive border, while 9/25 had lymphovascular invasion [4]. Lu et al were able to show MLMS vascular invasion in only 2 out of their 10 patients but reported tumor border invasion in all cases. Lu et al confirmed tumor border invasion in nearly all of their MLMS cases and consider it to be the “most helpful diagnostic feature for uterine MLMS”.

Due to MLMS being difficult to diagnose, it becomes of importance to utilize immunohistochemical (IHS) studies, for which only relatively little data is available on expression of these markers in MLMS.

Biomarkers that are commonly used to distinguish between malignant and benign smooth muscle tumors include overexpression of p16, p53, and IMP3. Lu et al found that p16 and IMP3 overexpression were present in only 5/10 and 3/10,



respectively, of their 10 cases. Despite their relatively low expression, p16 might be a good prognostic marker since p16 staining was linked to tumor progression [1]. Regarding p53, only 2/10 patients in Lu et al case series overexpressed this marker, indicating it does not have the same prognostic value as p16. Similarly, Ki67, a very commonly used proliferative marker, was found to have inconclusive clinical significance since it lacks sensitivity for malignancy [5] and the index of expression ranged from 1%-70%, indicating a poor correlation between tumor progression and aberrant expression as demonstrated in Lu et al's report. However, PHH3, a marker for identifying mitotic cells, has been found to be more reliable and specific for true mitotic figures in smooth muscle tumors [6]. Their use becomes particularly significant since identifying mitotic figures in MLMS is a difficult task. MLMS also have been found to express estrogen receptors (ER) (5/10) and progesterone receptors (PR) (6/10) receptors by Lu et al.

The most sensitive and useful biomarker might be HMGA2, a nonhistone DNA-binding factor with transcriptional factor activity. This is expressed in normal adult uterine myometrium but is upregulated in the development of leiomyomas, particularly the truncated form as it induces myometrial cell transformation towards tumor cells. This marker is seen in 25% of conventional leiomyomas but was seen by Lu et al in 100% of MLMS [7]. Furthermore, 51-75% of cells were found to be positive for HGMA2 in all 10 patients This is indicative of HGMA2's possible diagnostic value, albeit it is also expressed in other mesenchymal tumors and therefore does not make it specific for MLMS, but warrants further investigation with increased number of cases.

Based on prior published reports, an algorithm is proposed in this paper to assist pathologists in diagnosing MLMS. After establishing a malignant diagnosis, the initial step is to identify myxoid stroma content to determine whether the patient has conventional leiomyosarcoma or MLMS. Once identified as being over 60% myxoid, studying for capsular and/or lymphovascular invasion would be the next step. Lastly, immunohistochemical staining can be used to assist in diagnosis; HGMA2 expression would be the best sensitive staining test for MLMS and ER/PR positivity can be used in developing a treatment strategy.

Cytogenetic and molecular genetic analyses have shown that many of myxoid sarcomas are characterized by recurrent chromosomal translocations resulting in highly specific fusion genes. These genetic abnormalities have been identified in myxoid liposarcoma, low-grade fibromyxoid sarcoma, extraskeletal myxoid chondrosarcoma, myxofibrosarcoma, myxoinflammatory fibroblastic sarcoma, and myxoid dermatofibrosarcoma protuberans, among others [9]. However, such studies are lacking in myxoid leiomyosarcoma, or at best, are at the early stage to report specific changes. Other entities of diagnostic challenge that should be included in the differential diagnosis of MLMS are extraskeletal myxoid chondrosarcoma and myxoid liposarcoma. Yassin Nayel et al reported a interesting case of a myxoid chondrosarcoma that was similar histomorphologically

to myxoid liposarcoma and myxoid leiomyosarcoma. In their reported case, molecular testing was the final diagnostic determinant as IHC studies were not conclusive [10].

We hope this case report will add to the repertoire of research on this topic and provide clinicians and pathologists with more insight about myxoid leiomyosarcoma, allowing for appropriate diagnosis and informed management decisions until definitive conclusions can be established by future randomized clinical trials.

Acknowledgment

Special thanks to Garrett Reber, Adnan Jamal, and Pattamestrige Perera, MD candidates, American University of the Caribbean for their assistance in reviewing the final version of this manuscript

References

1. Lu B, Shi H, & Zhang, X. (2017). Myxoid Leiomyosarcoma of the uterus: a clinicopathological and immunohistochemical study of 10 cases. *Human Pathology*, 1(59): 139-146
2. Abeler VM, Røyne O, Thoresen S, Danielsen HE, Nesland JM, Kristensen GB. (2009). Uterine sarcomas in Norway. A histopathological and prognostic survey of a total population from 1970 to 2000 including 419 patients. *Histopathology*, 54.
3. Ns, Divya, and Srinivasamurthy V. (2014). Myxoid leiomyosarcoma of ovary-a rare case report. *Journal of clinical and diagnostic research*, 8(6): 5-6.
4. Parra-Herran C, Schoolmeester JK, Yuan L, et al. (2016). Myxoid leiomyosarcoma of the uterus: a clinicopathologic analysis of 30 cases and review of the literature with reappraisal of its distinction from other uterine myxoid mesenchymal neoplasms. *Am J Surg Pathol*, 40:285-301
5. O'Neill CJ, McBride HA, Connolly LE, McCluggage WG. Uterine leiomyosarcomas are characterized by high p16, p53 and MIB1 expression in comparison with usual leiomyomas, leiomyoma variants and smooth muscle tumor
6. Burch DM and Tavassoli FA. (2011). Myxoid leiomyosarcoma of the uterus. *Histopathology*, 59:1144-55.
7. Ben Huang, Jiayi Yang, Qingyuan Cheng, Peipei Xu, June Wang et al. Prognostic Value of HMGA2 in Human Cancers: A Meta-Analysis Based on Literatures and TCGA Datasets. *Front. Physiol.*, 26 June 2018 | <https://doi.org/10.3389/fphys.2018.00776>
8. Schmidt M, Raniwsky A, Sebald A, Balakrishnan E, Aziz M (2018) Leiomyosarcoma of the Epididymis: Case Report of Uncommon Location and Review of the Literature. *JSM Clin Case Rep* 6[4]: 1159.
9. Jun Nishio, Hiroshi Iwasaki, Kazuki Nabeshima, and Masatoshi Naito. Cytogenetics and
10. Molecular Genetics of Myxoid Soft-Tissue Sarcomas. Genetics Research International
11. Volume 2011, Article ID 497148, 13 pages doi:10.4061/2011/497148
12. Nayel Y, Jackson G, Taylor M, Varney J, Aziz M, et al. (2020) Extraskeletal Myxoid Chondrosarcoma in Comparison to Myxoid Liposarcoma- Case Report of a Challenging Diagnosis and Brief Review of the Literature. *JSM Clin Cytol Pathol* 5: 5.