

Transcranial Doppler in Posttraumatic Vasospasm Diagnosis of Basilar Artery: Case Report

Planas Oñate Alexeis^{1*}, Machado Curbelo Calixto², González Rivera Armando Elías¹ and Sánchez Miranda José Mario¹

¹Intensive Critical Care Unit, Calixto García's Teaching Hospital, Havana, Cuba

²Institute of Neurology and Neurosurgery, Department of Clinical Neurophysiology, Havana, Cuba

Article Information

Received date: Feb 07, 2017

Accepted date: Mar 07, 2017

Published date: Mar 10, 2017

*Corresponding author

Planas Oñate Alexeis, Intensive Critical Care Unit, Calixto García's Teaching Hospital, Havana, Cuba, Tel: +5378632385; Email: alexeipo@infomed.sld.cu

Distributed under Creative Commons CC-BY 4.0

Key words Transcranial doppler; Vasospasm; Subarachnoid hemorrhage; Basilar artery; Vertebro-basilar

Abstract

Transcranial Doppler (TCD) is commonly used in the monitoring of neuro-critical patient. In the subarachnoid hemorrhage is used in the early diagnosis of cerebral vasospasm.

We studied a 30 years old male patient, with severe traumatic brain injury, and right epidural parietal hematoma, right cerebellum hematoma and posttraumatic subarachnoid hemorrhage in posterior territory. The initial Glasgow Coma Score (GCS) was in 4 points.

TCD was done one day 2, 3, 6, 14 y 21. We used as vasospasm diagnosis in basilar artery, the criteria of $V_{m_{BA}} > 95$ cm/sec and $V_{m_{BA}}/V_{m_{ECVA}} > 2$ referred to Soustiel Ratio (SI).

The patient was diagnosed with early vasospasm of the basilar artery on day 3, based on a $V_{m_{BA}} = 121$ cm/sec and SI = 3.36. The patient was treated with nimodipine immediately of vasospasm diagnosis. It also had neurosurgical treatment with evacuation of the epidural and cerebellum hematoma.

Repeat TCD measurement was not done until day 6, the $V_{m_{BA}}$ was 79 cm/sec and the IS was 2.29.

It was transferred to another floor after 25 days in the ICU, with a GCS of 12.

The TCD was used as a diagnosis kit in the vasospasm and show his usefulness in the develop tracing of traumatic subarachnoid hemorrhage in posterior territory. It showed the TCD value in the monitoring of neurocritical patient with severe brain injury and high suspicion of vasospasm develop.

Introduction

The Transcranial Doppler is commonly used in the monitoring of neuro-critical patient [1]. In the Subarachnoid Hemorrhage (SAH) is frequently used in the diagnosis of early cerebral vasospasm [2].

The TCD vasospasm diagnosis in SAH patients is validated in the Cerebral Middle Arteries (MCA's) [3,5], but it's poorly defined in the posterior territory [2,6].

Many years ago in SAH, the vasospasm diagnosis was only explored in the anterior circulation. In the posterior territory it was evaluated in some cases with traumatic subarachnoid hemorrhage [7].

During the last years, TCD was used to measure the cerebral flow arteries velocities as vasospasm rates suspected in the posterior territory [6].

Recently, the posterior rate or Soustiel Index (SI) is used in the vasospasm diagnosis of basilar artery [5,8,9].

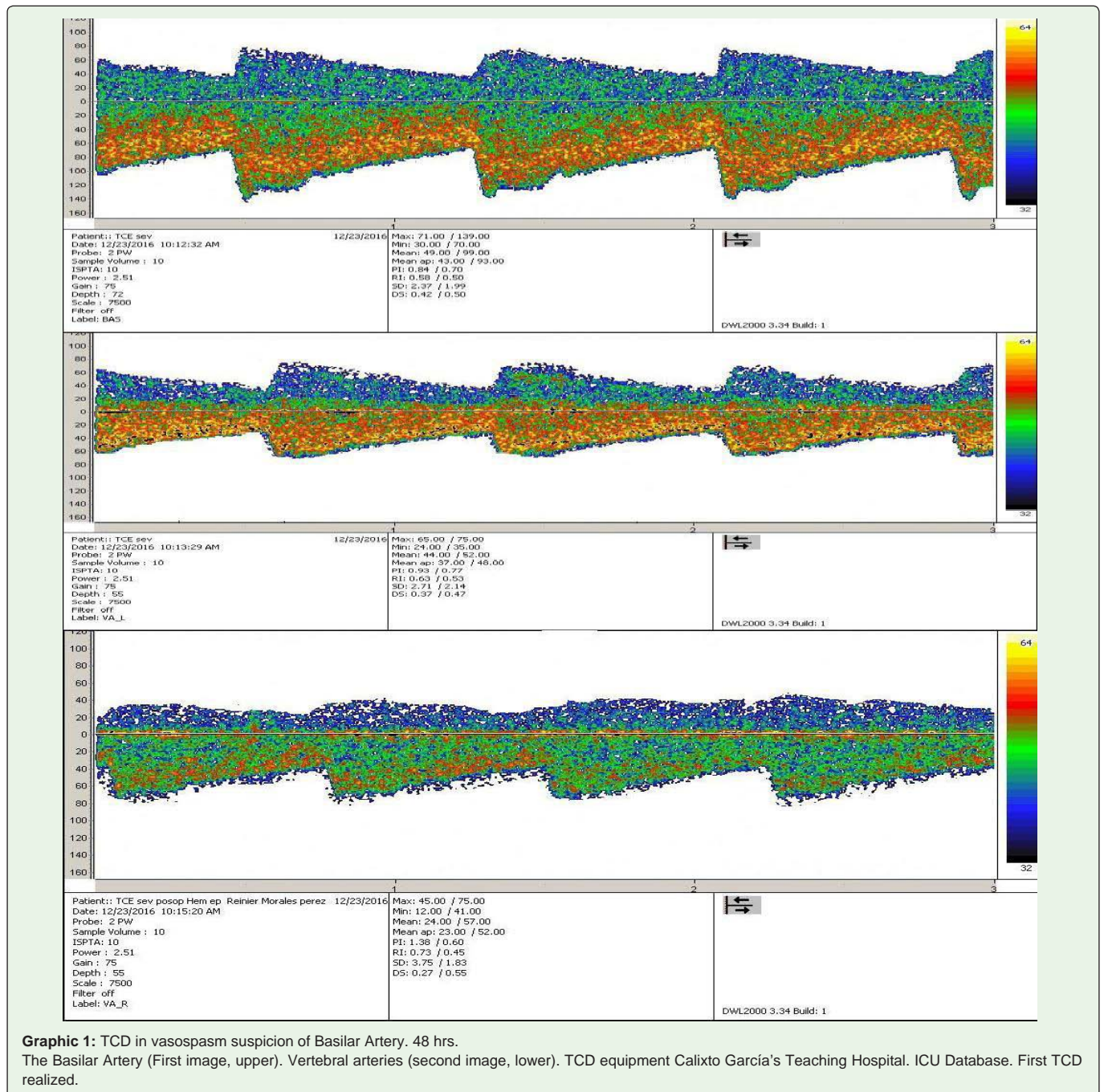
We find the Soustiel Index to calculate the ratio between the Basilar Artery (BA) and Vertebral Artery (VA). We divided the last intensity value in the mean velocity of BA and the average of the Mean Velocity (Vm) in vertebral's arteries. The normal value is 2 [5,8,9].

Case Report

We studied a 30 years old male patient, with severe brain injury by a sort of blunt trauma. The initial GCS was in 4 points, with oro-tracheal intubation and artificial mechanic ventilation necessity. The cranial CT scan showed a patient with right parietal epidural hematoma, right cerebellum hematoma and posttraumatic subarachnoid hemorrhage in posterior territory, with no other significant lesions. The patient was evaluated by neurosurgery, with non-surgical yardstick.

It was admitted to Intensive Critical Care Unit (ICU) and we star with neuro-intensive treatment.

We performed TCD with a Doppler EZ - DOP equipment and 2 MHz transducer. All exams were realized by the same explorer. The TCD was done one day 2, 3, 6, 14 y 21.



On day 2, the test showed high velocities pattern in CMA's and Cerebral Anterior Arteries (CAA's) in both hemispheres, associated to high resistance pattern, in right Cerebral Posterior Artery (CPA) (Table 1).

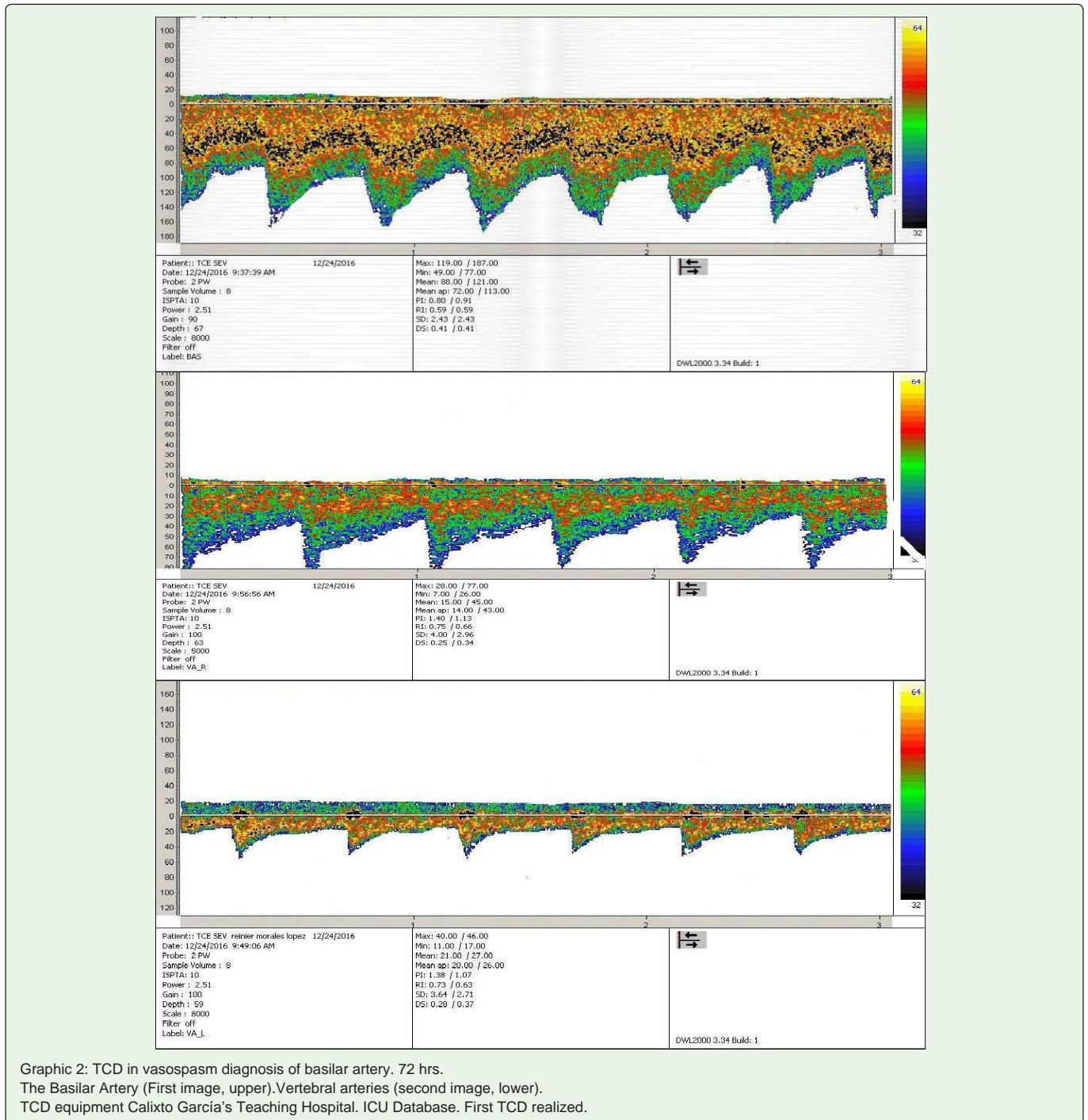
The Vm in both CMA's were over 120 cm/sec, but the Lindergard Rate (LI) in both cases were <3 (Generally in vasospasm cases the LI ≥ 3) [7]. This vasospasm is associated to low values of IP and IR.

In this patient the anterior vasospasm criteria's were absent. We consider as cerebral hyperemia pattern and it were present in the 4 arteries of the anterior territory.

We used as vasospasm diagnosis in basilar artery, the criteria of $Vm_{BA} > 95$ cm/sec and $Vm_{BA}/Vm_{ECVA} > 2$ referred to Soustiel ratio.

We explored the vertebro-basilar system, and we found BA with Vm: 99 cm/sec and the Soustiel Rate (SI): 1.82 with a high suspicion of BA vasospasm because the patient had a high Vm value in AB, but the Soustiel rate was normal.

The patient was diagnosed with an early vasospasm of the basilar artery on hospital day 3, based on a $Vm_{BA} = 121$ cm/sec and a $(SI) Vm_{BA}/Vm_{ECVA} = 3.36$ (Table 2).



Graphic 2: TCD in vasospasm diagnosis of basilar artery. 72 hrs. The Basilar Artery (First image, upper). Vertebral arteries (second image, lower). TCD equipment Calixto García's Teaching Hospital. ICU Database. First TCD realized.

The patient had a neurologic deterioration with GCS in 3 points. We began the treatment with calcio-antagonistic (nimodipine 60 mg/4 hrs).

The neuro-surgical physicians return to evaluate the patient and recognized a neurosurgical intervention necessity. The epidural hematoma and cerebellum hematoma were evacuated. The patient remained with similar neurologic state during 72 hrs with GCS in 3 points.

The TCD measurement was not done until day 6. The $V_{m_{BA}}$ was 79 cm/sec and the $SI = 2.29$. We find a normal pattern bilateral in CMA's and CAA's, with V_m decrease in vertebro-basilar territory. The patient moves the GCS to 6 points.

In the next day's the TCD showed slow and progressive decrease of the VM BA velocities with a clinical and neurologic patient recovery (Table 2).

Table 1: TCD results in anterior and vertebro - basilar arteries.

TCD. 12/23/2016	Vm. (cm/sec)	Systolic velocity. (cm/sec)	Diastolic velocity. (cm/sec)	Pulsatility Rate. (IP)	Resistance Rate. (IR)	Lindergard Rate. (LI)	Soustiel Rate. (SI)
CMA right.	129	183	87	0.74	0.52	2.30	-
CMA left.	130	173	72	0.78	0.58	2.77	-
CAA right.	107	155	64	0.85	0.59	-	-
CAA left.	112	164	69	0.85	0.58	-	-
CPA right.	44	77	23	1.23	0.70	-	-
CPA left.	65	92	39	0.82	0.58	-	-
BA.	99	139	70	0.70	0.50	-	1.82
VA right.	57	75	41	0.60	0.45	-	-
VA left.	52	75	35	0.77	0.53	-	-
Internal carotid extra-cranial right.	56	-	-	-	-	-	-
Internal carotid extra-cranial left.	47	-	-	-	-	-	-

TCD equipment Calixto García's Teaching Hospital. ICU Database. First TCD realized.

Table 2: TCD results in vertebro-basilar arteries.

TCD Vertebro-basilar arteries.	Day 2 nd .	Day 3 rd .	Day 6 th .	Day 14 th .	Day 21 th .
VM BA	99 cm/sec	121 cm/sec	79 cm/ sec	45 cm/ sec	42 cm/ sec
VM VA Left.	57 cm/sec	27 cm/sec	31 cm/ sec	38 cm/ sec	36 cm/ sec
VM VA Right.	52 cm/sec	45 cm/sec	38 cm/ sec	41 cm/ sec	38 cm/ sec
VM VA average.	54.5 cm/sec	36 cm/sec	34.5 cm/sec	39.5 cm/ sec	37.5 cm/ sec
Soustiel Rate. (SI)	1.82	3.36	2.29	1.15	1.12
Glasgow Come Score	O-1 V-1 M-2 4 points.	O-1 V-1 M-3 points.	O-3 V-2 M-3 6 points.	O-4 V-2 M-4 10 points.	O-4 V-2 M-6 12 points.

TCD equipment Calixto García's teaching Hospital. ICU Database.

The patient was transferred to another floor after 25 days in the ICU, with a neurologic state and GCS 12 points.

Discussion

We report a 30 years old patient with severe traumatic brain injuries and early vasospasm apparition in posterior circulation before 72 hrs. It was a rapid progression to severe vasospasm. We used the criteria of $Vm_{BA} > 95$ cm/sec and Soustiel rate ($Vm_{BA}/Vm_{ECVA} > 2$) as vasospasm diagnosis of BA.

According to studies performed in patients with cerebral vasospasm after a traumatic brain injury, using criteria of a $Vm_{BA} > 90$ cm/sec, the basilar artery vasospasm was in 19%; it was recorded from post-injury between days 2nd and 12th.

The literature describe in these case as values of $Vm > 90$ cm/sec in BA, showing a vasospasm diagnosis in posterior territory arteries with angiographic correlation performed [2,10].

The traumatic vasospasm AB was present in younger patients with a low score in GCS at the hospital admission [10]. These results are according with our findings.

Orthel et al. used $Vm > 90$ cm/sec and the Soustiel rate ($SI > 2.5$) in BA as vasospasm criteria. In 102 patient was performed the SI and it was positive in 23 patient (22.5%), this criteria represented a significant risk of vasospasm development [10].

When the Soustiel rate is about > 2 , the diagnosis of vasospasm is about 95% of specificity [6,7,9].

The $SI > 2.5$ is associated to moderate vasospasm and when the $SI > 3$ and with Vm in BA > 95 cm/sec, the diagnosis of severe vasospasm have a specificity and sensibility near to 100% [7-9].

In our case since the first TCD with Vm in BA of 99 cm/sec, we had a high suspicion of vasospasm. The second TCD showed a severe vasospasm in BA based on a Vm_{BA} of 121 cm/sec and a SI of 3.36 (Figures 1 and 2 and Table 2).

The beneficial effect showed by nimodipine in some studies, in a subgroup of brain injury patients with subarachnoid hemorrhage make suggest this drug use in the treatment of the patient. The nimodipine was included in our institutional guide by treat the ASH, although we should be very careful, because it can increase the risk of adverse reactions in someone patient.

Next to 6th day, the patient began with progressive decrease in BA velocities associated to a better clinical condition. These findings showed a close relationship between vasospasm resolution and the neurologic recovery.

Conclusions

The TCD was used as a diagnosis kit in the vasospasm and show his usefulness in the develop tracing of traumatic subarachnoid hemorrhage in the posterior territory. It showed the TCD value in the

monitoring of neurocritical patient with severe brain injury and high suspicion of vasospasm develop.

References

1. Planas Oñate A, González Rivera AE, Sánchez Miranda JM, Machado Curbelo C. Doppler transcraneal en el diagnóstico de la muerte encefálica. *Rev Cub Med Int Emerg*. 2016; 15: 37-54.
2. Fernández Delgado E, Egea Guerrero J, Freire Aragón MD, Rivera Fernández V. Aproximación diagnóstica al vasoespasmo de la circulación vertebrobasilar: utilidad del doppler transcraneal. *Med Intensiva*. 2015; 39:124-126.
3. Aaslid R, Huber P, Nornes H. A transcranial Doppler method in the evaluation of cerebrovascular spasm. *Neuroradiology*. 1986; 28: 11-16.
4. Sloan MA, Alexandrov AV, Tegeler CH, Spencer MP, Caplan LR, Feldmann E, et al. Assessment: transcranial Doppler ultrasonography report of the Therapeutics and Technology Assessment Subcommittee of the American Academy of Neurology. *Neurology*. 2004; 62: 1468-1481.
5. Scherle Matamoros C, Pérez Nellar J. Utilidad del doppler transcraneal para la detección del vasoespasmo en arterias cerebrales anteriores. *Rev neurolog*. 2010; 50: 273-278.
6. Sloan MA, Burch CM, Wozniak MA, Rothman MI, Rigamonti D, Permutt T, et al. Transcranial Doppler detection of vertebrobasilar vasospasm following subarachnoid hemorrhage. *Stroke*. 1994; 25: 2187-97.
7. Scherle Matamoros C, Pérez Nellar J. Utilidad del doppler transcraneal en la hemorragia subaracnoidea. Revisión. *Rev Chil Neuro-Psiquiat*. 2011; 49: 79-85.
8. Soustiel JF, Shik V, Shreiber R, Tavor Y, Goldsher D. Basilar vasospasm diagnosis: Investigation of a modified "Lindegaard Index" based on imaging studies and blood velocity measurements of the basilar artery. *Stroke*. 2002; 33: 72-78.
9. Svirni GE, Ghodke B, Britz GW, Douville CM, Haynor DR, Mesiwala AH, et al. Transcranial Doppler grading criteria for basilar artery vasospasm. *Neurosurg*. 2006; 59: 360-366.
10. Oertel M, Boscardin WJ, Obrist WD, Glenn TC, McArthur DL, Gravori T et al. Posttraumatic vasospasm: the epidemiology, severity, and time course of an underestimated phenomenon: a prospective study performed in 299 patients. *J Neurosurg*. 2005; 103: 812-824.