

Case Report: Exposed Floating Knee with Bone Loss with Primary Fixation

Bruno Gonçalves Pereira Paschoa*, Gustavo Tadeu Sanchez, Carlos Eduardo da Silveira Franciozi, Daniel Balbachevsky, Fernando Baldy dos Reis and Marcos Vinicius Malheiros Luzo

Departamento de Ortopedia e Traumatologia, Escola Paulista de Medicina da Universidade Federal de São Paulo, Brasil

Article Information

Received date: May 21, 2017

Accepted date: Jun 28, 2017

Published date: Jun 29, 2017

*Corresponding author

Bruno Gonçalves Pereira Paschoa,
Departamento de Ortopedia e
Traumatologia, Escola Paulista de
Medicina da Universidade Federal de
São Paulo, Rua Borges Lagoa, andar
São Paulo, Brasil, Tel: 55 11 5549-4848;
Email: bruno.paschoa@hotmail.com

Distributed under Creative Commons
CC-BY 4.0

Abstract

Ipsilateral fracture of the femur and tibia, denominated as floating knee, are results of high-energy trauma related to high rates of associated injuries and complications. This case reports a type IIIA exposed floating knee, with loss of joint bone fragments of the tibia and femur during an accident. Guided by the MESS score, limb saving was performed, fragments were reinserted and joint reconstruction was performed. The patient had bone consolidation in four months, infection with fistula in the knee at six months with some improvement when treated and osteonecrosis of the reinserted fragments was observed at sixteen months (lateral femoral condyle and lateral tibial plateau). The patient maintains the arc of motion in the knee of 10-90 degrees of flexion-extension, walks without crutches, but with a limp, valgus and pain. The use of scores like MESS helps in the decision to rescue or amputate severe cases, but it does not predict the functional outcome, and the floating knee is commonly associated with complications and worse case functional results, especially when it involves intra-articular fractures, comminuted fractures and infection, factors that are present in this reported case.

Introduction

The tibial and femoral ipsilateral fractures, designated in 1975 by Blake and McBryde as floating knee, are fractures resulted from high-energy trauma with a high rate of complications [1]. More prevalent in male patients around the third decade of their life, being victims of traffic accidents, where the incident rate has increased in the past few years [1,2]. Along with floating knee, the patients frequently show severe traumas (skull, thorax, abdomen and / or limbs) that can be life threatening, needing an approach to the polytrauma [1-4]. Associated ligament lesions around 30-55% are classically described in floating knee as well as: open fractures, about 60-80%, vascular lesions in some studies are reported over 29%, extensive lesions of soft tissues, infections, and, in some cases, pulmonary embolism and neurological injuries are reported [3,5,6].

In a prospective study evaluating the outcomes of the floating knee, Shahzad [7] evidence shows complications in soft tissue injuries requiring reconstruction in 7.7% of cases, femur infection in 16.9%, tibia infection in 20%, stiffness in 32.3% and the need for amputation reaching 7.7%.

Fraser classified the fractures according to the affected location, dividing femoral and tibial diaphysis fractures as type 1, fracture of the femoral diaphysis and intra-articular tibia as type 2A, intra-articular fracture of the femur and diaphyseal tibia as type 2B, and Intra-articular of both, as type 2C [8].

The treatment is guided by the patient's poly-trauma associated lesions, life support being the priority, and orthopedic damage control is performed in unstable patients with temporary fixations for posterior definitive fixation with the stabilized patient. The orthopedic treatment is individualized according to the fracture pattern and associated lesions, and an unfavorable functional outcome is often reported [1-3,7,9].

Case report

A 17-year-old male patient, who was run over on 10/09/2015, was brought to the pre-hospital emergency team, admitted to a level 1 trauma center, presenting deformities, exposed bone fractures, bone loss of the lower limb and the left knee all of which were attributed to the collision with the car bumper (Figure 1). Externalized bone fragments (lateral femoral condyle and tibial plateau) were brought in a plastic bag containing saline solution. (Figure 2) The patient was treated by the general surgical team according to the ATLS protocol, and an orthopedic and vascular evaluation was requested when the patient was already in the surgical center. Without alterations in other systems, the patient was hemodynamically stable, Glasgow 15. Filiform palpable pulse, slowed distal in the ankle and left foot, with good distal perfusion, toe movement and left foot hallux were present. Patient's popliteal artery was visual (Figure 3).

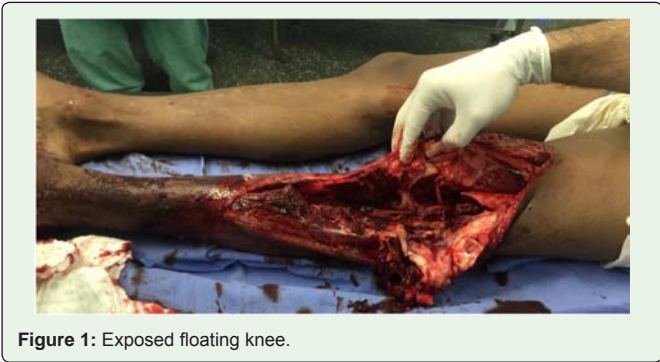

Figure 1: Exposed floating knee.

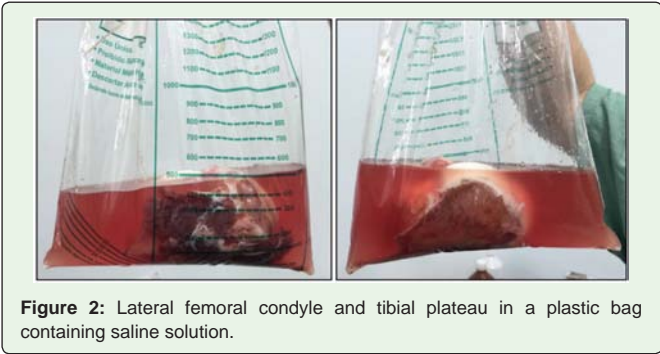


Figure 2: Lateral femoral condyle and tibial plateau in a plastic bag containing saline solution.

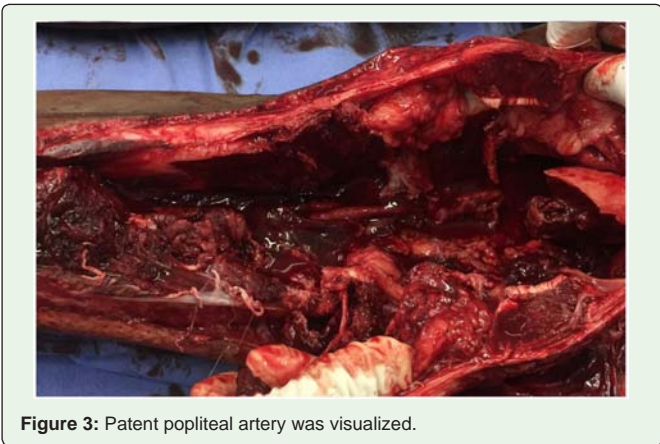


Figure 3: Patent popliteal artery was visualized.

The left knee was diagnosed with a supra intercondylar femoral fracture, lateral tibial plateau fracture, patella sagittal fracture, dislocation of fibular head, longitudinal injury of the extensor mechanism, posterolateral corner loss and absence of the lateral meniscus. No preoperative radiography was performed. Due to good general condition of the patient and fracture instability, a definitive primary fixation was performed with the use of loose bone fragments, which were sterilized with alcoholic chlorhexidine and saline solution 0.9%. The surgery was performed about three hours after the trauma. The femur was fixed with a dynamic screw condylar plate and 6.5 mm compression screws and the tibial plateau with an unlocked anti-shear 4.5 mm plate and a 4.5 mm screw fixing a proximal tibio-fibular (Figure 4); No bone grafts were used. The patellar fracture was fixed with 3.5mm compression screws and the extensor mechanism was re-tensioned (Figure 5).The lateral meniscus and the posterolateral corner were absent, a suture was performed with the re-tensioning of

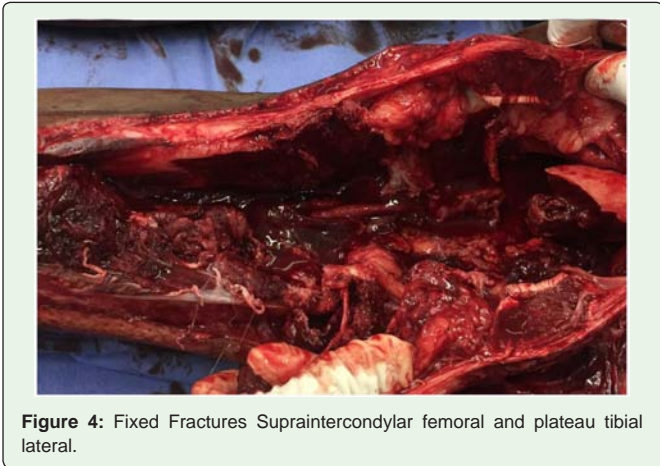


Figure 4: Fixed Fractures Supraintercondylar femoral and plateau tibial lateral.

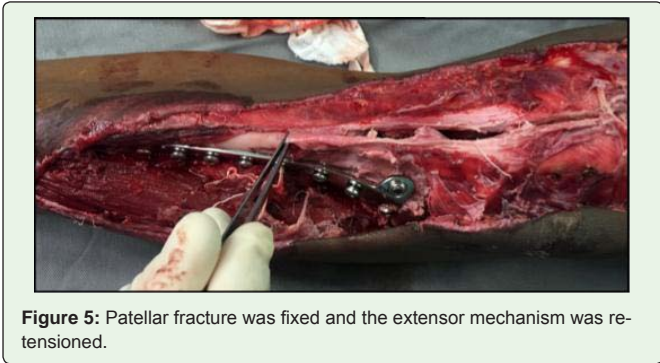


Figure 5: Patellar fracture was fixed and the extensor mechanism was re-tensioned.

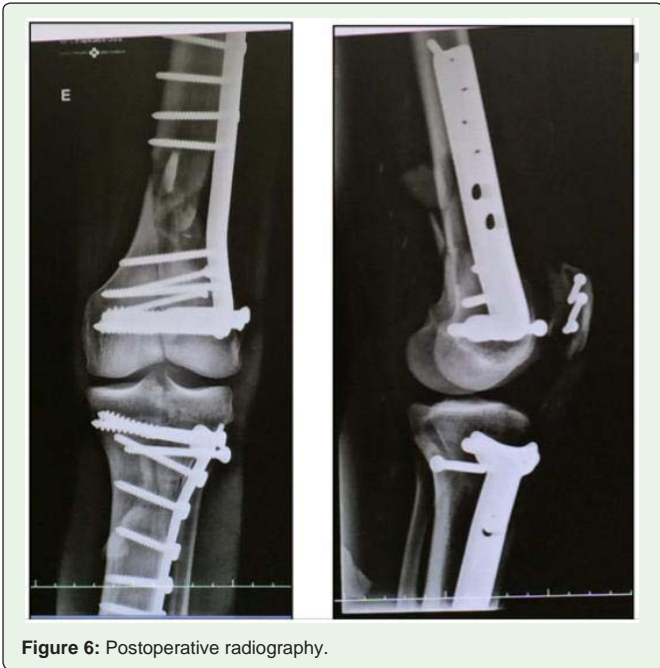

Figure 6: Postoperative radiography.

the lateral soft tissues that were present. Postoperative radiography was performed (Figure 6).

There were areas of suffering of the surgical wound with areas of adjacent necrosis but with good evolution (Figure 7). In the fourth

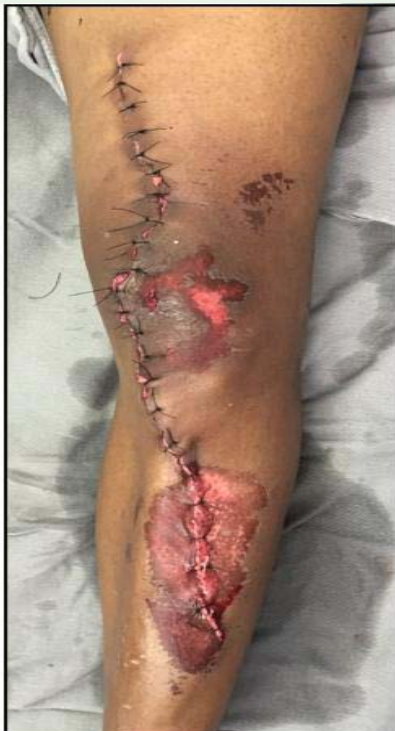

Figure 7: Aspect of wound closure.

month after the operation, radiographic bone consolidation was present (Figure 8), and amplitude of movement of 0-80 degree of knee flexo-extension.

At six months after the operation, a secretory fistula presented on the anterior side of the left leg, mechanical cleaning was performed and the implant was maintained. 16 months after the operation, evidence showed osteonecrosis of the lateral femoral condyle and lateral tibial plateau (Figure 9).

Currently, the patient walks without the aid of a crutch, but with a limp due to valgus and pain, classified as level 4 according to the VAS [10] (Visual Analogue Scale). He does not use an orthoses in the limb. The patient was not evaluated on other scales. He presents with an active arc of motion ranging from 10-90 degrees of flexion-extension. The examination revealed: valgus stress ++ / +++, anterior drawer ++ / +++, lachman + / +++, posterior drawer + / +++. Non-symptomatic patient with regard to instability and no reconstruction procedures were required.

Case Discussion

Along with the increasing number of floating knees cases, it is currently observed that more attention and studies to assess the outcomes of these serious injuries is necessary [2,9].

The presence of intra-articular fractures, higher scores of skeletal injury and the severity of soft tissue injuries are significant indicators of unfavorable outcomes [4,11,12], all of which are presented in the case report.

Hee [4] analyzed that increasing age was associated with delays in bone junction, and the capacity to walk and carry load. The habit of smoking and the quantity of cigarettes smoked per year at the time of injury is related to the increased incidence of knee stiffness, pseudoarthrosis and the inability to support weight when walking. The highest scores related to the trauma severity scores are associated with delayed walking and loading ability. The presence of open fractures, predicted the probability of stiffness and the delay in walking and carrying load. Comminuted fractures were associated with pseudoarthrosis, and segmental fractures with delayed bone healing.

Hee suggested a preoperative scoring system, which considered age, smoking habits at the time of injury, trauma severity scores, open fractures, segmental fractures, and comminution for the prognosis of the final outcomes for these types of fractures.

The surgical stabilization of the fractures is recommended for early mobilization, providing better results. The intramedullary nails are recommended whenever it is possible as the best treatment choice except for grade 3B and C in open fractures [9,13]. The single incision technique to fix both fractures has been recommended in several studies [6,8,13-15]. Comparing the single versus traditional incision for anterograde nails in the fractures, the first was found to have less surgical time and anesthesia with reduction of blood loss. Currently, the standard of treatment is a single incision and retro-grade femoral and antegrade tibial nails are proposed for floating knee, however, in some cases in which there is intra-articular involvement, the use of plates and screws is required [11].

In cases of severe and extensive injuries, the surgeon must decide between initial amputation and limb saving [3]. The MESS (Mangled

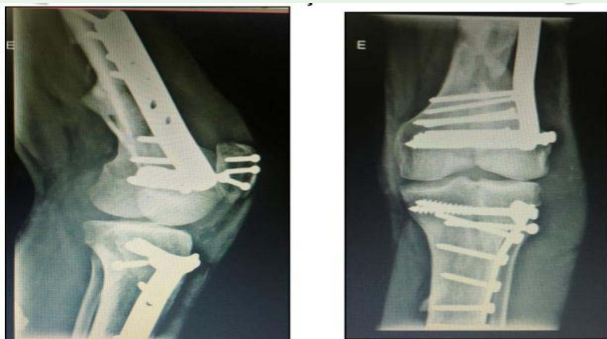

Figure 8: Radiographic bone consolidation with four months.

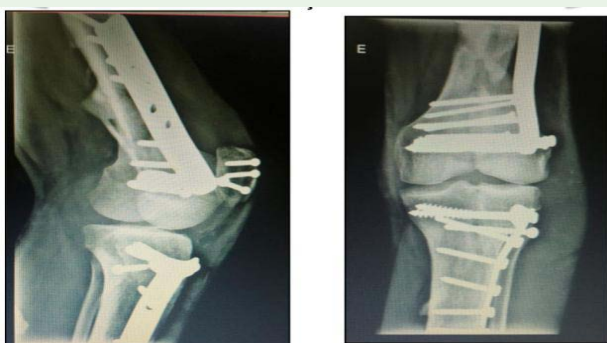

Figure 9: Osteonecrosis of the lateral femoral condyle and lateral tibial plateau.

Extremity Severity Score) score takes into account four parameters: skeletal and soft tissue injury; limb ischemia; shock; patient's age. It is a tool that has proven to be useful in the clinical and legal management of such lesions and as an indicator for amputation, when amputation is indicated for a score of higher than or equal to 7 [16]. The reported patient reached a score of 5, due to the presence of soft tissue avulsion [4] and diminished pulse, but maintaining good distal perfusion [1]. The MESS score was used and it was chosen to save the limb and reconstruct the joint, demonstrating that this tool is useful to help in decision making and rationalization even in cases that are apparently difficult and without saving.

In a study by Schiro [17], in which the scores for amputation were evaluated, decision-guided MESS score showed a higher accuracy, making it possible to decrease the frequency of late amputations, which are related to an increase morbidity and mortality.

Knee ligament injuries are more common with floating knee injuries than with isolated femur or tibial fractures, with an incidence of over 50%, and careful evaluation and monitoring of the knee is required in all cases of floating knee injuries [2,3,11].

The rate of pseudoarthrosis in the recent literature varies from 4% to 11% for the femur and from 3% to 30% for the tibia [5], despite the poor prognostic factors. In this case, 4-6 months post-operatively showed consolidation.

There are no reports in the literature of osteonecrosis of the femoral condyle and/or tibial plateau as a complication of the floating knee, a fact evidenced in our case at 16 months after the operation. The factor attributed to this outcome in our case is considered to be the detachment of the bone fragments of the lateral femoral condyle and lateral tibial plateau, which were saved from the scene of the accident. They were used for joint reconstruction and subsequently they also suffered with an infection process, that was treated approximately 6 months after the operation, and osteonecrosis of the reinserted fragments was observed sixteen months after the operation at the implant locations.

It was discussed with the patient that the possibility of a femoro-tibial arthrodesis, was an option, however, due to the patient's present movement and bearable pain, this was not performed.

Evaluating the final result of floating knee treatment, the primary factors demonstrated, that comminutive fractures, intra-articular fractures and extensive soft tissue injuries contribute to joint restriction in post-operative clinical evolution, and according to the Karlstrom scale the limitation of joint function of at least 20 degrees or less than normal makes the result, regular [11].

In a study by Marco [2], evaluating the functional results on the Lysholm scale, the results were unsatisfactory in 64.7% of the cases, along with the Karlström scale, where 88.2% of the cases were also considered unsatisfactory.

The literature shows that the clinical results obtained in the treatment of the floating knee vary considerably even by standardizing the Karlström scale. While Rethnam [11] and Hee [4] present, respectively, 82.7% and 68.6% of satisfactory results, Fraser [8] considers only 30% of satisfactory results in patients treated surgically, although claiming that floating knee treatment presents discouraging results. Feron [5], who achieved 53% of satisfactory results in one year

and 44% in 2 years, showed that the worst results were associated with the periarticular location of fractures, comminution and infection, as reported in our case.

Despite the severity of the case, it was possible to perform the saving and reconstruction of the limb, which allows for a lower energetic expenditure for the patient in walking than with a possible femoral amputation and also avoids the need of an orthosis, which are limited and currently very difficult to access by our public system because of its cost. The MESS score used, allowed for the limb to be saved, however the limb's final functional status is not predicted or evaluated by the score [16,17].

Conclusion

The floating knee is a serious injury, associated with high-energy traumas with the involvement of multiple systems. Treatment must assess the systemic and local associated lesions to target the best possible outcomes according to the severity of each case. The use of scores such as MESS helps with the decision making process to rescue or amputate in severe cases, however, it does not predict the functional outcome with the floating knee, being commonly associated with complications and worse functional outcomes, especially when it involves intra-fractures, comminution, and infection, factors that were present in this reported case.

References

1. Nouraei MH, Hosseini A, Zarezadeh A, Zahiri M. Floating knee injuries: Results of treatment and outcomes. *J Res Med Sci.* 2013; 18: 1087-91.
2. Marco FA, Rozim AZ, Piedade SR. Knee joint stability in a floating knee condition. *Acta Ortop Bras.* 2008; 16: 32-36.
3. Bertrand ML, Andrés-Cano P. Management of the Floating Knee in Polytrauma Patients. *Open Orthop J.* 2015; 9: 347-355.
4. Hee HT, Wong HP, Low YP, Myers L. Predictors of outcome of floating knee injuries in adults: 89 patients followed for 2-12 years. *Acta Orthop Scand.* 2001; 72: 385-394.
5. Feron J-M, Bonneville P, Pietu G, Jacquot F. Traumatic Floating Knee: A Review of a Multi-Centric Series of 172 Cases in Adult. *Open Orthop J.* 2015; Suppl 1: 356-360.
6. Ostrum RF. Treatment of Floating knee injuries through a single percutaneous approach. *Clin Ortop Relat Res.* 2000; 375: 43-50.
7. Shahzad K, Ahmad Khan RD, Yasin A. Floating knee injuries: postoperative complications and outcome. *J Pak Med Assoc.* 2015; 65: S195-201.
8. Fraser RD, Hunter GA, Waddell JP. Ipsilateral fracture of the femur and tibia. *J Bone Joint Surg.* 1978; 60-B: 510-515.
9. Prasad VKV, Satyanarayana J, Narasimha Rao T, Satish P, Moorthy GVS. A Prospective study of 97 cases to arrive at treatment protocols for floating knee. *J of Evolution of Med and Dent Sci.* 2015; 4: 3608-3613.
10. Martinez JE, Grassi DC, Marques LG. Analysis of the applicability of different pain questionnaires in three hospital settings: outpatient clinic, ward and emergency unit. *Rev Bras Reumatol.* 2011; 51: 304-308.
11. Rethnam U, Yesupalan RS, Nair R. The floating knee: epidemiology, prognostic indicators & outcome following surgical management. *J Trauma Manag Outcomes.* 2007; 1: 2.
12. Hegazy AM. Surgical Management of Ipsilateral Fracture of the Femur and Tibia in Adults (the Floating Knee): Postoperative Clinical, Radiological, and Functional Outcomes. *Clin Orthop Surg.* 2011; 3: 133-139.
13. Lundy DW, Johnson KD. "Floating knee" injuries: ipsilateral fractures of the femur and tibia. *J Am Acad Orthop Surg.* 2001; 9: 238-245.

14. Theodoratos G, Papanikolaou A, Apergis E, Maris J. Simultaneous ipsilateraldiaphyseal fractures of the femur and tibia: treatment and complications. *Injury*. 2001; 32: 313-315.
15. Ríos JA, Ho-Fung V, Ramírez N, Hernández RA. Floating knee injuries treated with single-incision technique versus traditional antegrade femur fixation: a comparative study. *Am J Orthop (Belle Mead NJ)*. 2004; 33: 468-472.
16. Helfet DL, Howey T, Sanders R, Johansen K. Limb salvage versus amputation. Preliminary results of the Mangled Extremity Severity Score. *Clin Orthop Relat Res*. 1990; 256: 80-86.
17. Schirò GR, Sessa S, Piccioli A, Maccauro G. Primary amputation vs limb salvage in mangled extremity: a systematic review of the current scoring system. *BMC Musculoskelet Disord*. 2015; 16: 372.