

Clinical Image ‘A Suspected Body Packer’

Kevin Ching Hin Wong*, Wai Yip Wong, Oi Fung Wong, Hing Man Ma and Albert Chau Hung Lit

Accident and Emergency Department, North Lantau Hospital, Hong Kong

Article Information

Received date: Mar 16, 2018

Accepted date: Mar 19, 2018

Published date: Mar 20, 2018

***Corresponding author**

Kevin Ching Hin Wong, Accident and Emergency Department, North Lantau Hospital, 8 Chung Yan Road, Tung Chung, Lantau, Hong Kong, Email: kevinwongch@hotmail.com

Distributed under Creative Commons CC-BY 4.0

Case

A 71-year-old male under custody by Custom Officer for suspected body packing was brought to the emergency department for medico-legal examination. Vitals were stable. Physical examination was unremarkable. Per rectal examination was negative. Kidney, Ureter and Bladder (KUB) X-ray showed dilated bowel loops with vague radiopaque shadows in the stomach and left lower quadrant (Figure 1). Bedside ultrasound scan of abdomen showed a linear echogenic structure with posterior acoustic shadowing (Figure 2). Presence of intra-intestinal drug packets was highly suspected. Plain Computed Topography (CT) of abdomen and pelvis revealed numerous hyperdense drug pockets in the stomach and small bowel segments (Figure 3). The patient passed all the drug packets during his stay in the custodial ward. The content of the drug packets was confirmed to be liquid cocaine.

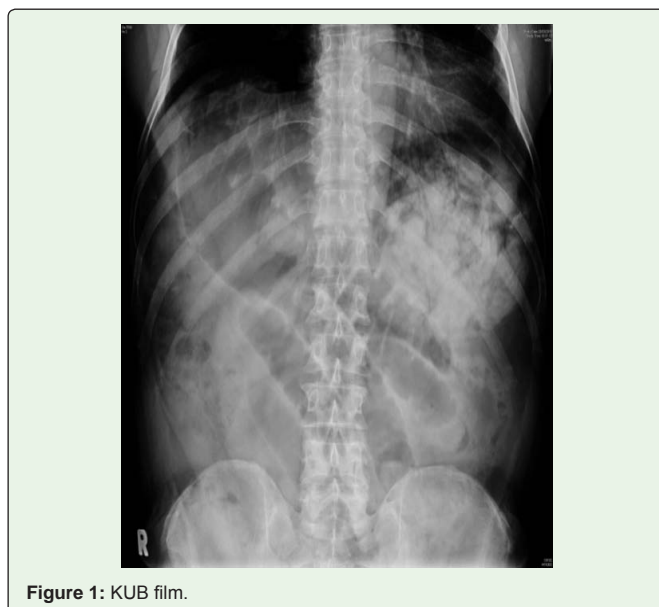


Figure 1: KUB film.

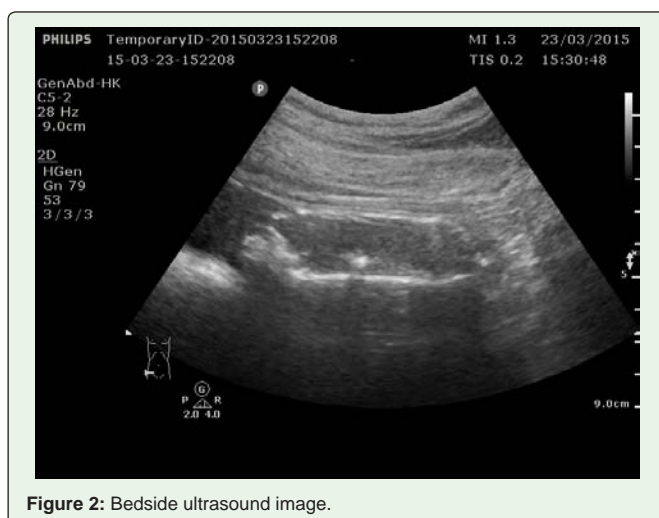

Figure 2: Bedside ultrasound image.

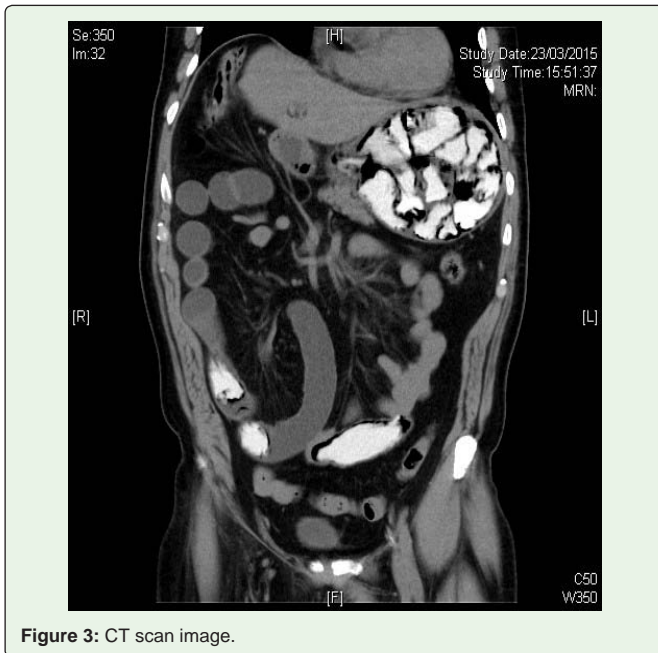


Figure 3: CT scan image.

Discussion

Body packing refers to the intracorporeal concealment of illegal substances for smuggling [1]. It was first reported in 1973 by Deitel and Syed who described a 21-year-old patient who developed small bowel obstruction after swallowing a condom filled with hashish [2]. Cocaine, heroin and cannabis are three main drugs commonly smuggled using this method [1]. Both children and pregnant women have been reported to be used as body packers [3].

Body packers usually present to the emergency department either for medical assessment after detention or arrest so as to confirm the presence or absence of concealed drugs, or due to complications including drug-induced toxic effects and intestinal obstruction [3], which are described by the term “body packer syndrome” [4]. History is unreliable in this patient group [5]. Radiological investigations are important to identify the ingested drug packets and to look for complications such as bowel obstruction, gastrointestinal perforation and subsequent acute peritonitis [1].

Plain abdominal X-ray is the most commonly used imaging modality for initial screening. However, its sensitivity is reported to be ranging from 40% to 90% [1], with specificity about 90% [4]. False positives are usually due to misinterpretation of normal intestinal air, calcifications, scybala and other foreign bodies [1]. On the radiograph, the interpreters should look for the presence of one or multiple well-defined opacities [1] and specific signs including the “double-condom sign”, “tic-tac sign” and “parallelism sign” [6].

Computed Topography (CT) has high sensitivity and specificity ranging from 95% to 100% [4]. It is used for highly suspicious cases with equivocal results on initial screening [1]. The drug packets on CT appear as multiple, uniform, round to oval dense foreign bodies with better seen “double-condom” and “rosetta sign” [5]. Limitation of CT includes its ionizing radiation burden, cost and availability [4].

A recent change in intestinal transport of cocaine from solid to liquid form was reported in attempt to avoid detection [7]. Plain X-rays were significantly less sensitive and specific in identifying liquid-containing packets [4], due to their lower radiographic density and better adaptability to intestinal anatomy.

Ultrasound is suggested as an alternative procedure as it is fast [5], cheap, easy-to-use, and radiation-free [4]. It can also be used for paediatric and pregnant cases [4]. In the case of liquid cocaine its sensitivity may be favoured due to the liquid content [7]. However, ultrasound is operator dependent. It is specific in experienced hands. A positive predictive value of 97.6% with accuracy up to 94% has been reported in one study [8]. Its sensitivity is considered lower than plain radiographs [9] and a negative ultrasound does not reliably exclude the presence of drug packets. On ultrasound the packets appear as linear, arcuate, oval or round, smooth hyperechogenic structures with posterior acoustic shadowing [5].

Body packing has its medical and legal implications. Physicians should be aware of different imaging modalities and their limitations.

References

1. Pinto A, Reginelli A, Pinto F, Sica G, Scaglione M, Berger FH, et al. Radiological and practical aspects of body packing. *Br J Radiol.* 2014; 87: 20130500.
2. Deitel M, Syed AK. Intestinal obstruction by an unusual foreign body. *Can Med Assoc J.* 1973; 109: 211-212.
3. Traub SJ, Hoffman RS, Nelson LS. Body packing--the internal concealment of illicit drugs. *N Engl J Med.* 2003; 349: 2519-2526.
4. Berger FH, Nieboer KH, Goh GS, Pinto A, Scaglione M. Body packing: a review of general background, clinical and imaging aspects. *Radiol Med.* 2015; 120: 118-132.
5. Cengel F, Bulakci M, Selcuk T, Savas Y, Ceyhan M, Kocak A, et al. The role of ultrasonography in the imaging of body packers comparison with CT: a prospective study. *Abdom Imaging.* 2015; 40: 2143-2151.
6. Sica G, Guida F, Bocchini G, Iaselli F, Iadevito I, Scaglione M. Imaging of drug smuggling by body packing. *Semin Ultrasound CT MR.* 2015; 36: 39-47.
7. Burillo-Putze G, Becker LT, Rodríguez MG, Torres JS, Nogué S. Liquid cocaine body packers. *Clin Toxicol (Phila).* 2012; 50: 522-524.
8. Meijer R, Bots ML. Detection of intestinal drug containers by ultrasound scanning: an airport screening tool?. *Eur Radiol.* 2003; 13: 1312-1315.
9. Lee K, Koehn M, Rastegar RF, van Hoorn F, Roy E, Berger FH, et al. Body packers: the ins and outs of imaging. *Can Assoc Radiol J.* 2012; 63: 318-322.