

The use of Rescue Therapy in Three Cases of Aconite-Induced Refractory Ventricular Arrhythmia: Intravenous Lipid Emulsion or Extracorporeal Membrane Oxygenation

Yu Kwan LI^{1*}, Shing Kit LAM², Chi Ming CHAN¹ and Albert Chau Hung LIT¹¹Department of Accident and Emergency, Princess Margaret Hospital, Hong Kong²Department of Accident and Emergency, Pok Oi Hospital, Hong Kong

Article Information

Received date: Mar 20, 2018

Accepted date: May 30, 2018

Published date: May 31, 2018

*Corresponding author

Yu Kwan LI, Department of Accident and Emergency, Princess Margaret Hospital, 2-10 Princess Margaret Hospital Road, Lai Chi Kok, Hong Kong,
Email: lipatrick@gmail.com

Distributed under Creative Commons CC-BY 4.0

Keywords Ventricular Arrhythmia; Intravenous Lipid Emulsion; Lipophilic drugs; Hypaconitine; Deoxyaconitine

Abstract

Aconite-induced ventricular arrhythmias are often resistant to direct current cardioversion and conventional pharmacotherapy currently advocated in Advanced Cardiac Life Support algorithms and patients may die from refractory ventricular tachyarrhythmia. Aconitum alkaloids are lipid soluble and hence intravenous lipid emulsion is a potential treatment. We report two cases of aconite-induced refractory ventricular arrhythmia which did not respond to intravenous lipid emulsion while another case was successfully managed with extracorporeal membrane oxygenation as a bridge to recovery.

Introduction

Aconite poisoning is still one of the major herb related public concerns nowadays, especially in Asian countries. Severe aconite poisoning with case fatalities do occur. Based on the non-selected cases managed in a regional hospital in Hong Kong, the overall in-hospital mortality of aconite poisoning was 5.5% [1]. While most of these patients died from refractory ventricular arrhythmia, traditional resuscitation using the pharmacotherapy and direct current cardioversion currently recommended in Advanced Cardiac Life Support algorithms may not be useful in aconitine and related alkaloids induced ventricular arrhythmias [2]. Therefore, effective treatment for this condition remains to be sought.

We describe three cases of severe aconite poisoning with refractory ventricular tachyarrhythmia. After conventional therapy, we tried Intravenous Lipid Emulsion (ILE) therapy in two refractory cases but failed. Another case of “hidden” aconite poisoning was successfully treated with Extracorporeal Membrane Oxygenation (ECMO) support.

Case Series

Case 1

An 83-year-old woman with no prior history of cardiac disease presented to emergency department with repeated vomiting and depressed conscious state shortly after consuming herbal decoction containing 60 grams of prescribed “Fuzi” in April 2012. She was unstable and required cardiopulmonary resuscitation en route to the hospital. Her initial blood pressure was 100/42 mmHg with pulse 218 per minute on arrival and electrocardiogram showed wide complex tachycardia (Figure 1a). Intravenous amiodarone 150 mg was administered. Despite treatment, she ran into refractory Ventricular Tachycardia (VT) and subsequently Ventricular Fibrillation (VF) which was resistant to electrical therapy, further bolus of amiodarone, flecainide, and adrenaline together with Advanced Cardiac Life Support (ACLS) resuscitation. Therapeutic trial of intravenous 100 ml 20% Intralipid® was administered followed by 300ml over 30 minutes (Figure 1b,c). Another bolus of 100ml 20% Intralipid® was employed because of refractory pulseless VT. Despite active resuscitation, patient finally succumbed and was certified dead after resuscitation for 1 hour and 48 minutes. Her serum sample confirmed the presence of Aconitum alkaloids (hypaconitine, deoxyaconitine) and their hydrolyzed products.

Investigation by Department of Health found this lot of “Fuzi” (the lateral root tuber of *A. carmichaeli*) was contaminated by more toxic “Chuanwu” (the root tuber of *A. carmichaeli*). The recommended dosage for processed “Chuanwu” is 1.5-3 grams.

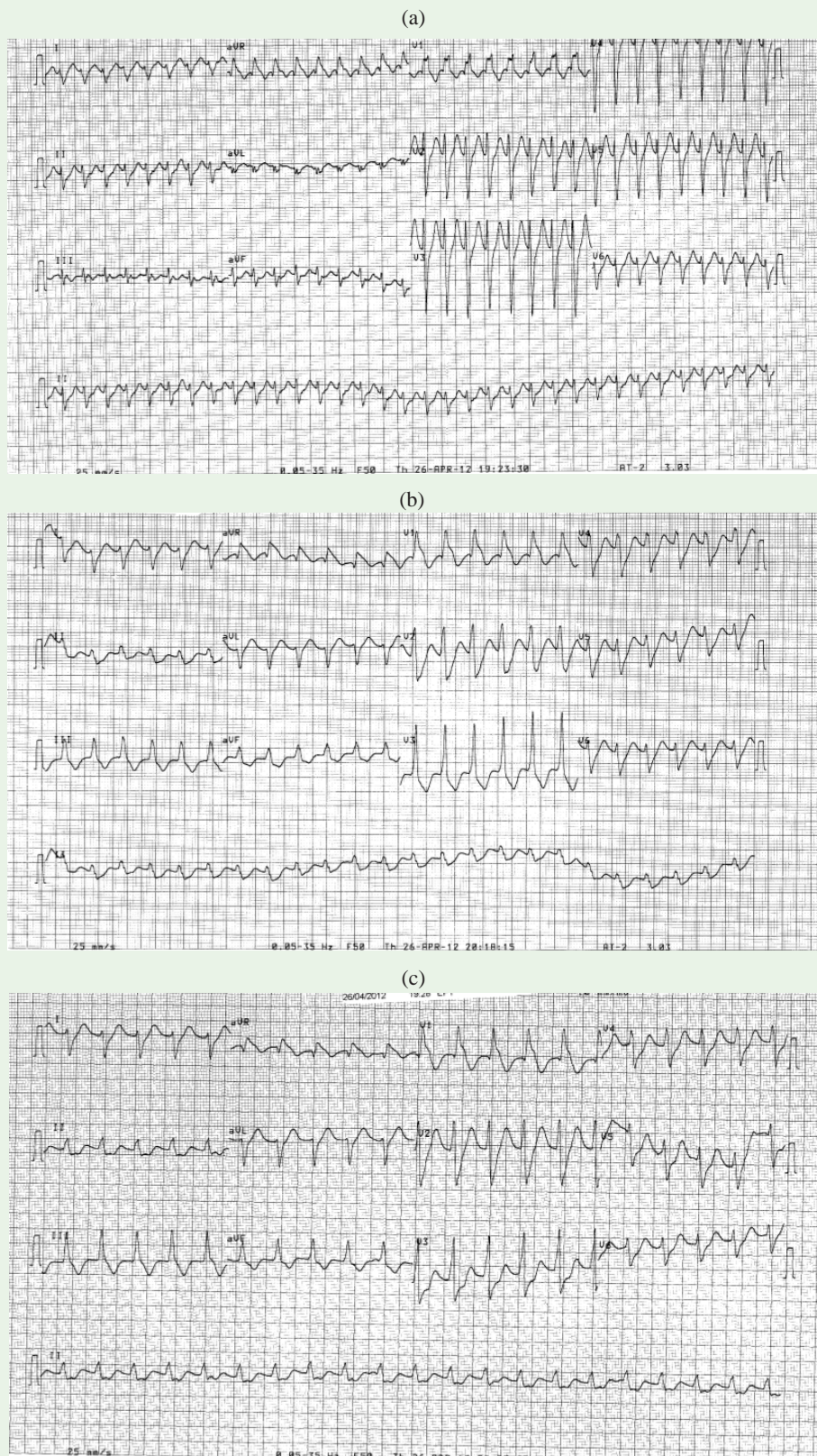


Figure 1: Case 1: (a) ECG on presentation showing wide complex tachycardia at the rate of 204 per minute; (b) ECG immediately before Intralipid® administration; (c) ECG a few minutes after Intralipid® administration showing no significant changes(a).

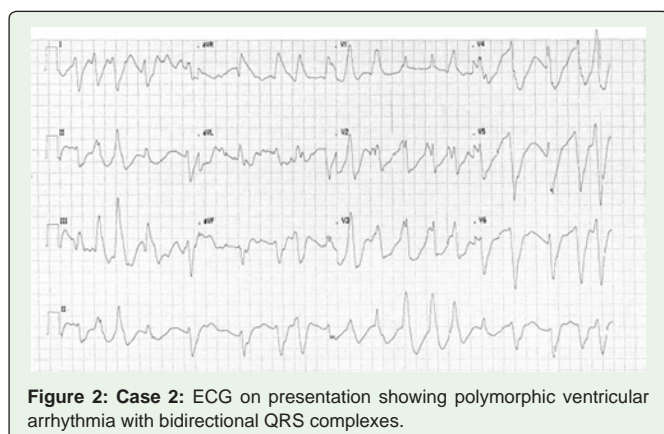


Figure 2: Case 2: ECG on presentation showing polymorphic ventricular arrhythmia with bidirectional QRS complexes.

Case 2

A 40-year-old Nepalese man without previous history of cardiac disease presented to emergency department in June 2013 with acute onset of confusion, dizziness, vomiting and sweating shortly after taking Bikhama, the common name of *Aconitum bisma*. His initial blood pressure was 87/53 mmHg with pulse 139 per minute and Glasgow Coma Scale of 11/15 (E4V2M5). Cardiac monitoring showed wide complex tachycardia compatible with polymorphic ventricular tachycardia (Figure 2). Intravenous amiodarone 150 mg was loaded and followed by maintenance infusion.

His clinical condition continued to deteriorate requiring high dose inotrope support and intubation. Despite treatment, he developed refractory VT and VF which were resistant to electrical therapy, further amiodarone administration together with ACLS resuscitation. Therapeutic trial of intravenous 100 ml 20% Intralipid® was administered and followed by 400 ml over 20 minutes. Despite active resuscitation, patient finally succumbed and was certified dead after resuscitation for 2 hour and 31 minutes.

Aconitum alkaloids (indaconitine, pseudoaconitine, yunaconitine), bikhaconitine and their hydrolyzed products were identified in both of his urine sample and herbal remnant.

Case 3

A 62-year-old man without prior history of heart disease presented to emergency department in January 2013 with acute onset of chest discomfort, facial and limbs numbness for one hour. Cardiac monitoring revealed wide complex tachycardia compatible with polymorphic ventricular arrhythmia. His initial blood pressure was 168/99 mmHg with pulse 164 per minute. A loading dose of intravenous amiodarone 150 mg was administered and followed by maintenance infusion. Despite treatment, he deteriorated and developed unstable VT with episodes of pulseless VT requiring repeated electrical therapy. He was intubated and was transferred to intensive Cardiac Care Unit. He developed further episodes of pulseless VT and unstable VT. Emergency coronary angiogram and serum troponin I was normal. He was put on Intra-Aortic Balloon Pump (IABP) and Veno-Arterial Extracorporeal Membrane Oxygenation (VA-ECMO) because of persistent unstable haemodynamics. Ventricular arrhythmia resolved at around 24 hours after admission. Then, VA-ECMO and IABP were successfully weaned off after employment for 27 hours. Cardiac magnetic resonance imaging was normal.

He later admitted taking home-made herbal tea half hour before the onset of symptoms. His urine sample and herbal remnant confirmed the presence of *Aconitum* alkaloids (aconitine, mesaconitine, deoxyaconitine).

He was discharged from the hospital without any neurological sequelae on day 13.

Discussion

Aconite-induced ventricular arrhythmias are often refractory to direct current cardioversion and antiarrhythmic drugs [2]. To our knowledge, the first two cases were the first reported cases of ILE therapy for *aconite* induced refractory ventricular arrhythmia in the English literature and case three was Hong Kong's first reported case of ECMO support as a bridge to recovery in temporary haemodynamically unstable ventricular dysrhythmia caused by *aconite* poisoning.

Aconitine binds with high affinity to the open state of voltage-dependent sodium channels, thereby inducing arrhythmias by the prolongation of the open state of the channel leading to sustained depolarization [3]. The associated increase in intracellular calcium via Na^+ - Ca^{2+} exchange system induces triggered activity promoting automaticity within the ventricular myocardium and the generation of ventricular arrhythmias [4].

From a recent published review on 65 reported cases of probable *aconite* poisoning resulting in ventricular arrhythmia, the therapies that were mostly associated with terminating the arrhythmia were flecainide, prolonged cardiopulmonary resuscitation and cardiopulmonary bypass [2]. However, in a Hong Kong study of 17 patients with herb-induced *aconite* poisoning with ventricular arrhythmias, no single agent was uniformly effective [5].

Intravenous lipid emulsion (ILE) therapy is regarded as a useful rescue therapy for treating lipid-soluble drug-induced cardiotoxicity because of its "lipid sink" theory [6]. According to the theory, the administration of lipid reduces the volume of distribution of the drug in question by sequestration of lipophilic drugs out of the periphery and into the vascular compartment. ILE has been widely advocated into international guidelines for the management of major local anesthetic-induced systemic toxicities despite the lack of randomized controlled human trials [7-10]. Its use has also been extended to the other lipophilic drug toxicities although the evidence for its effect remains sparse [11]. *Aconitine* is lipophilic substance and ILE may be a potential treatment for its toxicity [3].

In an in-vitro model proposed by Deborah French et al, the partition constant accounts for approximately 75% of the variation in the percent decrease in serum drug concentration, while the volume of distribution accounts for an additional approximately 13% of the variation [12]. The lipid partition constant ($\log P$) is the single most key factor to predict the efficacy of ILE therapy from this model. The more positive the $\log P$ value and the larger the volume of distribution, the more soluble the drug is in lipid and the more likely ILE is to be useful clinically in sequestering the drug, making it less available at its site of action.

The severity of the intoxication and hence the risk of fatality is related to the blood concentration of *aconitine*, *mesaconitine* and *hyaconitine* for "Chuanwu", "Caowu" and "Fuzi" poisonings which

attributed to the most of aconite poisonings in Hong Kong [3]. According to the Pubchem database from the National Centre for Biotechnology Information website, the logP values of these major Aconitum alkaloids including aconitine, hypaconitine, mesoaconitine are 0.3, 0.9 and -1 respectively. Such values comparing with logP value 3.4 of bupivacaine, the reduction of serum level attributed to ILE is expected to be insignificant. This may explain why ILE seems to be not useful in our first two cases.

According to the guideline from Extracorporeal Life Support Organization, ECMO should be considered if “shock persists despite volume administration, inotropes and vasoconstrictors, and intraaortic balloon counterpulsation if appropriate” [13]. ECMO is a bridge to recovery, transplant and implantable circulatory support. It is especially useful in severe poisoning patients since the clinical impact of the intoxication is often temporary [14]. It provides temporary haemodynamics and oxygenation support while the xenobiotic is metabolized or eliminated [15]. Since pharmacotherapy and electrical cardioversion are not universally effective in patients with severe aconite poisoning with ventricular arrhythmia and circulatory collapse, ECMO is potentially an effective modality of treatment. The clinical impact of the aconite poisoning is often temporary and most of the patients would recover from ventricular arrhythmia within 24 hours after consumption as the blood concentration of Aconitum alkaloids are generally below the detection limits at this time [16].

Conclusion

For patient with aconite induced refractory unstable ventricular arrhythmia that is resistant to antiarrhythmic medications, ILE therapy seems unlikely to be effective but temporary ECMO support may be useful by acting as a bridge to recovery, allowing the Aconitum alkaloids to be excreted from the circulation, thereby weaning off from its toxic effect. These observed findings should be confirmed by future research study.

References

1. Chan TYK, Tomlinson B, Tse LKK, Chan JC, Chan WW, Critchley JA. Aconitine poisoning due to Chinese herbal medicines: a review. *Vet Hum Toxicol*. 1994; 36: 452-455.
2. Coulson JM, Caparotta TM, Thompson JP. The management of ventricular dysrhythmia in aconite poisoning. *Clin Toxicol (Phila)*. 2017; 55: 313-321.
3. Chan TY. Aconite poisoning. *Clinical Toxicology*. 2009; 47: 279-285.
4. Amran MS, Hashimoto K, Homma N. Effects of sodium-calcium exchange inhibitors, KB-R7943 and SEA0400, on aconitine-induced arrhythmias in guinea pigs in vivo, in vitro, and in computer simulation studies. *J Pharmacol Exp Ther*. 2004; 310: 83-89.
5. Tai YT, But PBH, Young K, Lau CP. Cardiotoxicity after herb-induced aconite poison. *Lancet*. 1992; 340: 1254-1256.
6. Rothschild L, Bern S, Oswald S, Weinberg G. Intravenous lipid emulsion in clinical toxicology. *Scand J Trauma Resusc Emerg Med*. 2010; 18: 51.
7. Neal JM, Bernards CM, Butterworth JF 4th, Di Gregorio G, Drasner K, Hejtmanek MR, et al. ASRA practice advisory on local anesthetic systemic toxicity. *Reg Anesth Pain Med*. 2010; 35: 152-161.
8. AHA Guideline: 2017.
9. AAGBI Guideline: Management of Severe Local Anesthetic Toxicity. 2017.
10. Hoegberg LC, Bania TC, Lavergne V, Bailey B, Turgeon AF, Thomas SH, et al. Systematic review of the effect of intravenous lipid emulsion therapy for local anesthetic toxicity. *Clin Toxicol (Phila)*. 2016; 54: 167-193.
11. Levine M, Hoffman RS, Lavergne V, Stork CM, Graudins A, Chuang R, et al. Systematic review of the effect of intravenous lipid emulsion therapy for non-local anesthetics toxicity. *Clin Toxicol (Phila)*. 2016; 54: 194-221.
12. French D, Smollin C, Ruan W, Wong A, Drasner K, Wu AH. Partition constant and volume of distribution as predictors of clinical efficacy of lipid rescue for toxicological emergencies. *Clin Toxicol (Phila)*. 2011; 49: 801-809.
13. Extracorporeal Life Support Organization (ELSO) Guideline: Guidelines for Adult Cardiac Failure. 2017.
14. de Lange DW, Sikma MA, Meulenbelt J. Extracorporeal membrane oxygenation in the treatment of poisoned patients. *Clin Toxicol (Phila)*. 2013; 51: 385-393.
15. Wang GS, Levitan R, Wiegand TJ, Lowry J, Schult RF, Yin S. Extracorporeal Membrane Oxygenation (ECMO) for Severe Toxicological Exposures: Review of the Toxicology Investigators Consortium (ToxIC). *J Med Toxicol*. 2016; 12: 95-99.
16. Yoshioka N, Gonmori K, Tagashira A, Boonhooi O, Hayashi M, Saito Y, et al. A case of aconitine poisoning with analysis of aconitine alkaloids by GC/SIM. *Forensic Sci Int*. 1996; 81: 117-123.