

Prognostic Factors for Patients with
Renal Cell Carcinoma and Tumour
Thrombus: A ReviewTomasz Golabek^{1*}, Jakub Bukowczan², Mikolaj Przydacz¹ and Piotr L. Chlosta¹¹Department of Urology, Collegium Medicum at the Jagiellonian University, Poland²Department of Endocrinology and Diabetes Mellitus, Diabetes Resource Centre, North Tyneside General Hospital, UK

Article Information

Received date: Nov 11, 2015

Accepted date: Jan 21, 2016

Published date: Jan 27, 2016

*Corresponding author

Tomasz Golabek, Department of Urology,
Collegium Medicum at the Jagiellonian
University, ul. Grzegorzeczka 18, 31-
531 Krakow, Poland, Tel: +48 12 424
79 50; Fax: +48 12 424 79 70; Email:
elementare@op.pl

Distributed under Creative Commons
CC-BY 4.0

Keywords Renal cell carcinoma; Tumour
thrombus; Prognostic factors

Abbreviations BMI: Body Mass Index;
CI: Confidence Interval; CSS: Cancer
Specific Survival; HR: Hazard Ratio;
IVC: Inferior Vena Cava; N: Nodes;
NS: Not Statistically Significant; M:
Distant Metastases; RCC: Renal Cell
Carcinoma; cRCC: Clear Cell Renal
Cell Carcinoma; pRCC: Papillary Renal
Cell Carcinoma; chRCC: Chromophobe
Renal Cell Carcinoma; RV: Renal Vein;
TT: Tumour Thrombus; VS: Versus

Abstract

Background: There has been a large set of studies on potential prognostic factors in patients with renal cell carcinoma and venous tumour thrombus. However, the epidemiological evidence for the effect on survival of many of them has not been consistent. Therefore, we conducted a literature review of the studies on the prognostic factors in patients with renal cancer and tumour thrombus extending into the venous system to identify determinants with the strongest predicting potential.

Methods: We performed a literature review by searching the PubMed database for articles published from its inception until November 2015 based on clinical relevance.

Results: There have been several anatomical, histological, clinical and molecular prognostic factors identified in patients with the renal cell carcinoma and tumour thrombus. Anatomical factors of the highest prognostic potential include extent of tumour thrombus, venous wall cancer invasion, and metastases to the regional lymph nodes or distant organs. Whereas the most important histological prognostic factors include renal cell carcinoma subtype, tumour grade and presence of tumour necrosis, sarcomatoid features, microvascular, as well as the renal collecting system cancer invasion. Both clinical and molecular determinants have received a very limited amount of attention in terms of prognostic usefulness in renal cell carcinoma patients with tumour thrombus.

Conclusion: Although several anatomical, histological, clinical and molecular factors have been associated with the prognosis in patients with renal cell carcinoma and venous tumour thrombus, in majority of cases the evidence is based on retrospective and limited in size studies. Therefore, further multicentre and prospective studies are needed to better understand determinants negatively affecting outcome in patients with renal cell carcinoma and tumour thrombus.

Introduction

Renal cancer carcinoma (RCC) is one of the very few malignancies with an ability to extend into the venous system, and to form a tumour thrombus (TT) involving the renal vein (RV), inferior vena cava (IVC), or even the heart [1,2]. An estimated TT prevalence ranges between 4% and 36% of all RCC patients, and it is most commonly located within the RV (50% of cases) [3,4]. The atrium is one of the least affected sites with merely 1% of all RCC cases affected [5].

The natural course of RCC with concomitant TT within the venous system, without radical nephrectomy and thrombectomy, has very poor outcome. Epidemiological data from the SEER (Surveillance, Epidemiology, and End Results) database from the USA, revealed that the average survival among these individuals was 5 months shorter, whereas annual disease specific survival was only 29% [6]. Notably, radical nephrectomy extended by thrombectomy can improve the annual disease specific survival to as high as 90% in those individuals [7].

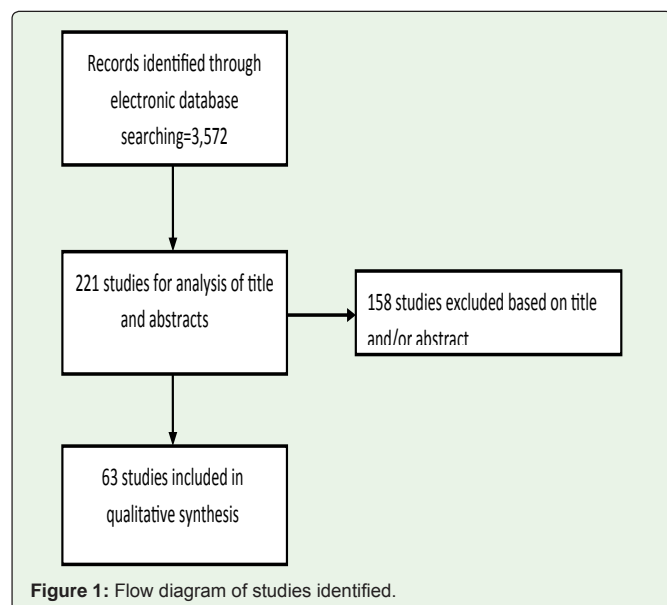
Individualised cancer treatment involves tailoring therapy to optimise the patient's care with a minimal risk of toxicity. This is particularly relevant with regard to renal cancer, which has the greatest mortality rate amongst all malignancies of the urinary tract [8]. Identification of factors determining the course of disease can inform the decision about treatment. Prognostic factors represent an example of these as they can predict the disease course regardless the treatment used.

In this section, we will summarise the literature in terms of prognostic factors significantly associated with the prognosis of RCC patients with venous tumour thrombus.

Materials and Methods

Literature search

Potentially relevant studies were identified through searching the Medline electronic database from its inception until November 2015. We considered all human research articles published in



English, not classified as review, editorial, comment, letter, guideline, or news. The search strategy included the following terms: renal cell carcinoma, renal carcinoma, renal cancer, clear cell renal carcinoma, clear cell renal cancer, tumor thrombus, venous thrombus, venous tumour thrombus, prognostic factor, prognostic factors, survival, survival factor, survival factors, determinants of outcomes, mortality, and recurrence.

Results

Study selection

A flow chart of the selection of eligible studies is given in Figure 1.

Eligibility assessment was performed by 2 independent reviewers, in duplicate. The search strategy yielded 3,572 citations, of which 221 were considered potentially relevant. 158 of these were excluded after screening of titles and abstracts. The full texts of the remaining 63 studies were assessed and included in this review.

The Evidence

Anatomical factors

Extent of tumour thrombus: Although the extent of tumour thrombus has been extensively investigated and is well recognised

Table 1: A comparison between prognostic value in terms of mortality between the tumour thrombus limited to the renal vein versus tumour thrombus extending into the inferior vena cava.

Author, year	Nr of patients with TT in RV	Nr of patients with TT in IVC	Multivariate analysis of prognostic value of TT extent (p value)
Tang et al. [16]	93	76	0.036*
Antonelli et al. [17]	99	48	0.001*
Nakayama et al. [18]	7	21	0.028*
Tilki et al. [19]	400	638	<0.001*
Cho et al. [20]	88	36	NS
Pirola et al. [21]	40	27	NS
Ali i wsp. [22]	12	38	<0.05*
Hirono et al. [23]	152	132	0.0241*
Vergo et al. [15]	5	45	0.31
Miyake et al. [24]	65	70	NS
Spiess et al. [25]	23	76	0.059
Sidana et al. [26]	64	68	0.069
Martinez-Salamanca et al. [27]	537	355	<0.005*
Wagner et al. [13]	933	196	<0.001*
Klaver et al. [28]	50	51	0.003*
Ficarra et al. [29]	276	60	0.11
Klatte et al. [14]	166	137	0.28
Leibovich et al. [30]	283	139	<0.0001*
Moinzadeh et al. [12]	46	68	0.0001*
Kim et al. [31]	41	28	0.575
Blute et al. [32]	191	171	0.002*
Gettman et al. [33]	127	160	0.048*
Staehler et al. [34]	19	51	NS
Ljungberg et al. [35]	47	19	0.95

Key: TT: Tumour Thrombus; RV: Renal Vein; IVC: Inferior Vena Cava; NS: Not Statistically Significant; *: Statistically Significant.

Table 2: The effect of venous wall cancer invasion on survival in renal cell carcinoma patients with tumour thrombus within the venous system.

Author, year	N	Follow-up (months)	Multivariate analysis HR (95%CI)	5-year survival without invasion vs. with invasion (%)	Mean survival without invasion vs. with invasion (months)
Cho et al. [20]	124	29.0 (m)	4.4 (1.2-15.6)	---	---
Hirono et al. [23]	280	40.4 (m)	---(---)	59 vs. 33	---
Manassero et al. [36]	22	32.2 (a)	---(---)	---	24 vs. 8
Hatcher et al. [37]	44	48(m)	---(---)	69 vs 57	115 vs. 64

Key: N: Number of RCC Patients with TT; A: Mean; M: Median; HR: Hazard Ratio; CI: Confidence Interval; Vs: Versus; ---: no data.

Table 3: The effect of tumour size on survival in renal cell carcinoma patients with tumour thrombus within the venous system.

Author, year	N	Tumour size cut-off (cm)	Follow-up (months)	Multivariate analysis HR (95%CI)	5-year survival tumour size cut-off ≤ vs > tumour size cut-off (%)
Whitson et al. [38]	1875	Per each 5cm tumour growth	12 (m)	1.2 (1.0-1.4)	---
Hirono et al. [23]	280	>8.3	40.4 (m)	--- (---)	59 vs 36
Miyake et al. [24]	135	>10.0	32.7 (a)	2.80 (---)	60 vs 35
Sidana et al. [26]	132	>7.5	30.3 (a)	1.16 (1.07-1.27)	---
Wagner et al. [13]	1192	>7.0	61.4 (m)	---(---)	---

Key: N: Number of RCC Patients with TT within the venous system; a: Mean; m: Median; HR: Hazard Ratio; CI: Confidence Interval; vs: Versus; ---: No Data.

prognostic factor of RCC invading venous system, the way it affects the course of disease still remains unclear and debatable [9-15]. Some available data suggest a negative prognostic value of vena caval involvement by TT, especially at the level above the diaphragm as compared to TT limited to renal vein only [9-11,16]. However, other study groups have failed to confirm this [12-15]. The reason of conflicting findings between studies reporting on the prognostic value of the TT extent could possibly be due to differences in terms of the inclusion criteria and number of study subjects, as well as, different operative techniques, duration of follow-up, but mainly due to study analyses adjusting for other clinico-pathological factors. A comparison between prognostic value in terms of mortality between the TT limited to the renal vein versus TT within the IVC based on all relevant studies has been shown in Table 1.

Venous wall cancer invasion

As opposed to the extent of TT, there is no doubt about the poor prognostic value of direct venous wall cancer invasion, which worse than the sole presence of TT within the vessel lumen (Table 2) [13,20,23,35-37].

Tumour size

Tumour size has been recognised as a negative prognostic factor in patients with RCC and TT extending into the venous system [13,23,24,26,28]. Table 3 presents studies which have identified tumour size as an important parameter in terms of survival. So far, no positive correlation between the tumour size and the RCC disease course has been shown, whereas the lack of prognostic value has been reported by Lambert et al. in their study on 118 RCC patients with TT extending into the venous system. In their report tumour size negatively correlated with overall survival in univariate analysis. However, a multivariate analysis failed to confirm this [39].

Regional lymph nodes and distant metastases

Presence of metastases to regional lymph nodes at the time of diagnosis with RCC is an independent negative prognostic factor in terms of survival in patients with or without TT [9,12,30-32,40-

42]. An association between the extent of TT within the IVC and the regional lymph nodes involvement, hence a more advanced disease, has been reported by Gettman et al. [33], Bissad et al. [43], Glazer et al. [40], as well as the Martinez-Salamanca team [27]. The latter study was a multicentre retrospective analysis of 1,215 patients, who underwent combined radical nephrectomy and thrombectomy in 11 urology centers in Europe and the USA. Higher level TT correlated more often with the regional lymph node involvement (TT within the RV: 20%, TT within the IVC below the diaphragm: 32%, TT within the IVC above the diaphragm: 36%).

However, these observations have not been confirmed by other researchers [12,44], hence bringing argument favouring radical treatment in all patients with confirmed TT (regardless TT extent), who are in good general condition, and have no metastases.

Cancer spread to the regional lymph nodes is considered an unfavourable prognostic sign significantly lowering survival in RCC patients [45,46]. These patients have 5-30% 5-year survival rate [47,48], whereas 5-year survival of those who undergo additional extended lymphadenectomy is: 52% (N1) vs 72%(N0), and 5-year cancer specific survival: 22% (N1) vs 78% (N0), proving lymphadenectomy very advantageous in terms of survival [45,46].

Similar to RCC without TT, further cancer spread to the lymph nodes significantly lowers survival in subjects with RCC and concomitant TT. Their 5-year cancer specific survival is 0-27%, as compared to those of N0: 17-63% [27,28,33,49].

Distant metastases carry a very grim prognosis whether or not TT is present [50-52]. The 5-year survival rates of N0M0 vs N1M1 patients with TT confined to the RV are 55% vs 35%, respectively; whereas in patients with TT confined to the infradiaphragmatic IVC the 5-year survival rates are: 55% vs 24%, and in patients with TT confined to the supradiaphragmatic IVC the 5-year survival rates are: 36% vs 23%, respectively for the N0M0 and N1M1 disease stages [27]. Table 4 shows negative impact of distant metastases on overall survival in the RCC patients with confirmed TT within the venous system.

Table 4: Negative impact of distant metastases on overall survival in renal cancer patients with tumour thrombus extending into the venous system.

Author, year	N	Follow-up (months)	Multivariate analysis cM1 vs. cM0 HR (95%CI)	Overall survival cM0 vs. cM1 (%)
Tang et al. [16]	143	45 (m)	4.14 (2.17–7.93)	---
Antonelli et al. [17]	147	40.3	4.97 (2.62-9.43)	---
Nakayama et al. [18]	61	33.7 (m)	6.0 (2.2-16.6)	50 months: 78 vs.35
Haddad et al. [53]	166 of TT above the diaphragm	27.8 (m)	2.3 (1.2-4.6)	5-year:42 vs. 7
Tilki et al. [19]	1774	63.3 (s)	cM1 vs.cM0: 0.4 (0.3-0.5)	---
Cho et al. [20]	124	29.0 (m)	3.8 (1.8-8.0)	5-year: 64 vs. 18
Ali et al. [22]	50	38.0 (a)	---(---)	5-year: 62 vs. 0
Whitson et al. [38]	1875	12.0 (m)	3.3 (2.6-4.8)	12 months: 90 vs. 60
Hirono et al. [23]	280	40.4 (m)	---(---)	5-year: 51 vs. 31
Vergo et al. [15]	50	26.0 (m)	---(---)	5-year:50 vs. 7
Miyake et al. [24]	135	32.7 (a)	5.3 (---)	---
Spiess et al. [25]	56	42.0 (m)	2.9 (1.6-5.3)	---
Sidana et al. [26]	132	30.3 (a)	2.2 (1.1-4.4)	5-year: 43 vs. 22
Wagner et al. [13]	1192	61.4 (m)	---(---)	---
Lambert et al. [39]	118	17.8 (m)	---(---)	5-year: 60 vs.---
Gettman et al. [33]	303	90 (m)	---(---)	5-year: 42 vs. 7

Key: N: Number of RCC patients with TT within the venous system; cM0: No Metastases Clinically Present; cM1: Metastases Clinically Present; a: Mean; m: Median; HR: Hazard Ratio; CI: Confidence Interval; vs: Versus; ---: No Data.

Cytoreductive nephrectomy

The advantage of thrombus extraction in patients with metastatic disease has not been clearly explained yet. This is mainly due to the fact that postoperative patient’s survival does not justify such an extensive surgery, which in itself carries a very high perioperative risk of death. Staehler et al. have reported a significantly worse survival of patients with metastatic disease and concurrent tumour thrombus (TT) (mean postoperative survival: 13months, 2-year survival rate was 26%) compared to those with TT but no metastases (34% 5-year postoperative survival rate) [34]. However, other authors reported much better results. Zisman et al. observed the 2-year survival rate as high as 76% in patients with non-metastatic disease and TT within the IVC, and 43% in those with metastatic disease and concurrent TT [49]. In the study by Parekh et al. the reported 3-year postoperative survival rates were 64% and 74%, respectively in subjects with metastatic disease and concurrent TT, and those without metastases but a TT present (p=0.16) [54].

Considering a high risk of complications and perioperative mortality, particularly in those individuals with level IV TT (tumour thrombus extending into the right atrium), as well as the fact that a metastatic disease does not necessarily mean a much shorter survival, the authors of this book chapter have opted to carry on performing cytoreductive nephrectomy combined with thrombectomy in all patients with levels 0-III TT, and only in those with level IV TT whose ECOG performance status is 0 or 1. The remainder of patients is treated palliatively.

Perirenal fat invasion

There is large body of evidence supporting the poor prognostic value of perirenal fat cancer invasion on survival [13,17,19,29,30,33]. However, it is still unknown whether perirenal fat invasion is an

independent prognostic factor only in patients with TT confined to the RV regardless lymph node and/or distant metastases, and not in subjects with non-metastatic disease (N0M0) who have TT confined to the IVC, as shown by Glazer [40], Gettman et al [33], and Wagner et al [13]. Contrasting findings have been reported by Leibovich et al [30], Bertini et al [55], and Tilki et al [19] who proved that perirenal fat invasion in patients with RCC and TT is a universal prognostic factor regardless the extent of TT.

Histological factors

Histological subtype of renal cell carcinoma (RCC): Few studies have reported on possible relationship between the RCC histological subtype and survival [56,57]. The chromophobe RCC (chRCC) has more favourable prognosis than the papillary type, whereas the clear cell RCC (cRCC) bears the worst prognosis. Of note, this correlation was only present in univariate analyses and disappeared after regression analyses, which took into account stage of the disease [56,57]. Despite there is no consensus regarding prognosis of different histological RCC subtypes, a locally advanced pRCC is generally considered to carry a better prognosis than if metastatic [58].

Several groups of researchers have recently examined the prognostic value of major histological RCC subtypes in subjects with established TT within the venous system [13,57-59]. Cianco et al analysed histological data of 87 RCC patients with TT (including 25 subjects with cRCC), who underwent radical nephrectomy [59]. In multivariate analysis the presence of non-clear cell RCC was associated with worse outcome in terms of prognosis and survival (hazard ratio (HR)=2.4, p=0.03). However, this observation was not confirmed by either Wagner et al [13], and Kaushik et al. [58].

Margulis et al. analysed the relationship between the histological RCC subtypes and survival in 2,157 RCC patients (245 cases of pRCC), of which 20 had a confirmed TT [60]. An unpaired comparison

Table 5: Effect of tumour thrombus consistency on overall and cancer specific survival in patients with RCC and venous tumour thrombus.

Author, year	Solid TT	Friable TT	5-year CSS; Solid TT vs. Friable TT (%)	5-year OS; Solid TT vs. Friable TT (%)	Multivariate analysis Solid TT vs. Friable TT HR (p value)
Antonelli et al. [17]	79	68	61 vs. 60	59 vs. 57	1.03 (0.54-1.97)
Weiss et al. [66]	130	70	---	89 vs. 29	1.3 (0.227)
Bertini et al. [55]	107	67	47 vs. 21	---	0.6 (0.021)

Key: TT: Tumour Thrombus; CSS: Cancer Specific Survival; OS: Overall Survival; HR: Hazard Ratio.

revealed that the 5-year cancer specific survival was worse in the pRCC subtype group as compared to the cRCC subtype group (35% vs. 66%, $p=0.01$). Similar results came from a multicentre study of 1,774 RCC patients with TT [18]. The histological subtypes within the study cohort were as follows: cRCC (89.9%), pRCC (8.5%), and chRCC (1.6%), and the estimated Cancer Specific Survival (CSS) rates were 54%, 36%, and 59%, respectively. In univariate analysis pRCC had statistically significantly worse survival rate than cRCC. The difference was still apparent despite limiting the analysis to N0M0 subjects. Multivariate analysis showed, however, that the presence of pRCC was an independent prognostic factor for CSS. A multicentre study led by Tilki et al, which analysed data of 2,017 patients who underwent radical nephrectomy and thrombectomy, revealed that pRCC was indeed an independent poor prognostic factor (HR=1.61; CI=1.09-2.37), when compared with the cRCC subtype [42].

Interesting data in terms of relationship between the RCC histological subtype and survival have been reported by Kim et al. from their study on 74 RCC patients with concomitant TT (66 x cRCC, 12 x pRCC (4 x pRCC type 1, 8 x pRCC type 2) [61]. Type 2 pRCC was shown to harbour worse 5-year survival rates when compared with cRCC (0% vs. 53%). These results need to be interpreted with caution since this was a retrospective analysis on a small group of patients, plus the targeted treatment offered to those with a metastatic disease was not taken into consideration.

Moreover, some rarer histological subtypes of RCC i.e. Bellini duct carcinoma, renal medullary carcinoma, as well as sarcomatoid foci have been recognised as independent negative prognostic factors [38,62]. In the largest published study reporting mortality data of 1,875 RCC patients with TT from the SEER database led by the National Cancer Institute in the USA, the presence of Bellini duct carcinoma or sarcomatoid cancer foci proved independently unfavourable in terms of prognosis following multivariate regression analysis (HR=2.2 (CI=3.3)) [38].

Tumour grade

Tumour grade is typically assessed according to the Fuhrman classification system [62]. Several studies on RCC patients with or without TT have proven that tumour grade is an independent prognostic factor in terms of long-term survival [8,15,20,256,27,38,53,69]. Survival falls with worsening tumour grade. Hirono et al. [23] have reported a total 5-year survival rate of 53% in RCC patients with TT (for G1 and G2 tumours), and 37% 5-year survival rate for G3 tumours according to the Hermanek classification [65].

Tumour thrombus consistency

Association between the tumour thrombus (TT) consistency and survival in RCC patients was for the first time reported by Bertini

et al. in 2011 [55]. In both N0M0 and metastatic disease stage, the friable TT consistency carried worse prognosis than the solid TT variant. Weiss et al. have indeed confirmed these observations, however, in their analysis TT consistency was not an independent prognostic marker of survival among patients with RCC [65]. In a retrospective study by Antonelli et al. the univariate analysis showed that the presence of friable TT correlated with some poor prognostic markers of survival (symptoms, distant metastases and lymph node involvement, greater tumour size, higher TT extent, necrosis and microvascular invasion), as well as worse the cancer specific and the overall survival. However, the predictive value of TT consistency on survival could not be replicated in multivariate analysis [16]. Table 5 shows the effect of TT consistency on overall survival in patients with RCC and TT within the venous system.

Tumour necrosis

The presence of coagulative tumour necrosis is considered a negative prognostic marker of survival in all RCC patients with or without TT. In a multivariate regression analysis Haddad et al. have studied the presence of tumour necrosis as a poor prognostic marker of survival in patients with RCC and TT, HR=3.1 (1.4-6.7) [53]. Additionally, Blute et al. have reported 5-year CSS rates as 25% and 61% respectively for subjects with and without tumour necrosis within the TT [32].

Molecular factors

The usefulness of molecular factors in predicting the disease course in patients with RCC and TT has not been so far examined on a large scale. Laird et al. have analysed the proteomic markers expression such as: Ki67, p53, VEGF1, SLUG and SNAIL in RCC patients without TT and distant metastases, RCC patients with TT, and RCC patients with distant metastases. They have found that the expression was statistically greater in those with metastatic disease compared to patients with or without TT [67]. There were no differences in biomarker expression, however, between subjects with TT and those with distant metastases.

The expression analysis of eight different onco-micro RNAs in RCC patients with or without TT was first performed by Vergho et al.. They have proven that the expression of three microRNAs: miR-21, miR-126 and miR-221 was significantly greater in patients with TT compared to those without TT [68]. Moreover, by determining the level of miR-21, miR-221, and let-7b expression they were able to identify with 94% accuracy those individuals with TT either within the RV or IVC, and hence confirmed the utility of microRNA expression analysis as prognostic factors in patients with RCC and TT regardless the clinico-pathological features. However, due to limited number of patients participating in this study, the results should be interpreted with caution.

Laboratory studies and other prognostic factors

Laboratory studies have not been so far subject to the great amount of attention in terms of prognostic usefulness in RCC patients with TT. Multivariate analysis by Nakayama et al. showed that elevated levels of lactic dehydrogenase and C reactive protein significantly correlated with poor prognosis in this group of patients [17]. Haddad et al. reported that preoperatively raised levels of alkaline phosphatase correlated with poor prognosis in patients with RCC and TT within the IVC extending beyond the level of hepatic veins [53]. Additionally Abel et al. reported that low preoperative levels of albumin in the serum were independently correlated with 90-day postoperative mortality in patients with RCC and TT within the IVC extending beyond the level of hepatic veins [69].

An interesting relationship between patient's body mass index (BMI) and survival, as well as disease recurrence in patients with RCC and TT was reported by Cho et al. [20]. A BMI lower than 23 kg/m² negatively correlated with cancer specific survival, as well as cancer recurrence. Whereas, obesity was independently associated with better outcomes in terms of survival and the risk of future recurrence. Similar observations were reported by Spiess et al. who showed that BMI > 30 kg/m² was associated with greater survival [25]. The mechanisms responsible for these observations remain unclear. Several proteins and other mediators such as leptin and/or adiponectin have been proposed to possibly play a role as substances produced by the adipose tissue and slowing the RCC progression. Another explanation could be that low BMI is a marker of cachexia in those patients with advanced disease.

Conclusion

Recent years have brought a better understanding of the prognostic factors influencing the course of RCC associated with TT. Similar to RCC with no venous involvement, TT associated with RCC also heralds three major categories of prognostic factors, which can help predict its course. Anatomical factors of the highest prognostic potential include extent of tumour thrombus, venous wall cancer invasion, and metastases to the regional lymph nodes or distant organs. Whereas the most important histological prognostic factors include RCC subtype, tumour grade and presence of tumour necrosis, sarcomatoid features, microvascular, as well as the renal collecting system cancer invasion. Some molecular factors seem also promising. However, in majority of cases the evidence is based on retrospective and limited in size studies. Therefore, further research preferably multicenter and prospective is needed to better understand the factors negatively affecting outcome in patients with RCC and TT.

References

- Blute ML, Leibovich BC, Lohse CM, Cheville JC, Zincke H. The Mayo Clinic experience with surgical management, complications and outcome for patients with renal cell carcinoma and venous tumor thrombus. *BJU Int.* 2004; 94: 33-41.
- Martínez-Salamanca JI, Linares E, González J, Bertini R, Carballido JA, Chromecki T, et al. Lessons learned from the International Renal Cell Carcinoma-Venous Thrombus Consortium (IRCC-VTC). *Curr Urol Rep.* 2014; 15: 404.
- Woodruff DY, Van Veldhuizen P, Muehlebach G, Johnson P, Williamson T, Holzbeierlein JM. The perioperative management of an inferior vena caval tumor thrombus in patients with renal cell carcinoma. *Urol Oncol.* 2013; 31: 517-521.
- Ljungberg B, Campbell SC, Choi HY, Jacqmin D, Lee JE, Weikert S, et al. The epidemiology of renal cell carcinoma. *Eur Urol.* 2011; 60: 615-621.
- Boorjian SA, Sengupta S, Blute ML. Renal cell carcinoma: vena caval involvement. *BJU Int.* 2007; 99: 1239-1244.
- Reese AC, Whitson JM, Meng MV. Natural history of untreated renal cell carcinoma with venous tumor thrombus. *Urol Oncol.* 2013; 31: 1305-1309.
- Whitson JM, Reese AC, Meng MV. Population based analysis of survival in patients with renal cell carcinoma and venous tumor thrombus. *Urol Oncol.* 2013; 31: 259-263.
- Pantuck AJ, Zisman A, Belldgrun AS. The changing natural history of renal cell carcinoma. *J Urol.* 2001; 166: 1611-1623.
- Haferkamp A, Bastian PJ, Jakobi H, Pritsch M, Pfitzenmaier J, Albers P, et al. Renal cell carcinoma with tumor thrombus extension into the vena cava: prospective long-term followup. *J Urol.* 2007; 177: 1703-1708.
- Belis JA, Kandzari SJ. Five-year survival following excision of renal cell carcinoma extending into inferior vena cava. *Urology.* 1990; 35: 228-230.
- Martínez-Salamanca JI, Linares E, González J, Bertini R, Carballido JA, Chromecki T, et al. Lessons learned from the International Renal Cell Carcinoma-Venous Thrombus Consortium (IRCC-VTC). *Curr Urol Rep.* 2014; 15: 404.
- Moizadeh A, Libertino JA. Prognostic significance of tumor thrombus level in patients with renal cell carcinoma and venous tumor thrombus extension. Is all T3b the same? *J Urol.* 2004; 171: 598-601.
- Wagner B, Patard JJ, Méjean A, Bensalah K, Verhoest G, Zigeuner R, et al. Prognostic value of renal vein and inferior vena cava involvement in renal cell carcinoma. *Eur Urol.* 2009; 55: 452-459.
- Klatte T, Pantuck AJ, Riggs SB, Kleid MD, Shuch B, Zomorodian N, et al. Prognostic factors for renal cell carcinoma with tumor thrombus extension. *J Urol.* 2007; 178: 1189-1195.
- Vergho DC, Loeser A, Kocot A, Spahn M, Riedmiller H. Tumor thrombus of inferior vena cava in patients with renal cell carcinoma - clinical and oncological outcome of 50 patients after surgery. *BMC Res Notes.* 2012; 5: 5.
- Tang Q, Song Y, Li X, Meng M, Zhang Q, Wang J, et al. Prognostic Outcomes and Risk Factors for Patients with Renal Cell Carcinoma and Venous Tumor Thrombus after Radical Nephrectomy and Thrombectomy: The Prognostic Significance of Venous Tumor Thrombus Level. *Biomed Res Int.* 2015: 163423.
- Antonelli A, Sodano M, Sandri M, Tardanico R, Yarigina M, Furlan M, et al. Venous tumor thrombus consistency is not predictive of survival in patients with renal cell carcinoma: A retrospective study of 147 patients. *Int J Urol.* 2015; 22: 534-539.
- Nakayama T, Saito K, Fujii Y, Abe-Suzuki S, Nakanishi Y, Kijima T, et al. Pre-operative risk stratification for cancer-specific survival in patients with renal cell carcinoma with venous involvement who underwent nephrectomy. *Jpn J Clin Oncol.* 2014; 44: 756-761.
- Tilki D, Nguyen HG, Dall'Era MA, Bertini R, Carballido JA, Chromecki T, et al. Impact of histologic subtype on cancer-specific survival in patients with renal cell carcinoma and tumor thrombus. *Eur Urol.* 2014; 66: 577-583.
- Cho MC, Kim JK, Moon KC, Kim HH, Kwak C. Prognostic factor for Korean patients with renal cell carcinoma and venous tumor thrombus extension: application of the new 2009 TNM staging system. *Int Braz J Urol.* 2013; 39: 353-363.
- Pirola GM, Saredi G, Damiano G, Marconi AM. Renal cell carcinoma with venous neoplastic thrombosis: a ten years review. *Arch Ital Urol Androl.* 2013; 85: 175-179.
- Ali AS, Vasdev N, Shanmuganathan S, Paez E, Dark JH, Manas D, et al. The surgical management and prognosis of renal cell cancer with IVC tumor thrombus: 15-years of experience using a multi-specialty approach at a single UK referral center. *Urol Oncol.* 2013; 31: 1298-1304.

23. Hirono M, Kobayashi M, Tsushima T, Obara W, Shinohara N, Ito K, et al. Impacts of clinicopathologic and operative factors on short-term and long-term survival in renal cell carcinoma with venous tumor thrombus extension: a multi-institutional retrospective study in Japan. *BMC Cancer*. 2013; 13: 447.
24. Miyake H, Terakawa T, Furukawa J, Muramaki M, Fujisawa M. Prognostic significance of tumor extension into venous system in patients undergoing surgical treatment for renal cell carcinoma with venous tumor thrombus. *Eur J Surg Oncol*. 2012; 38: 630-636.
25. Spiess PE, Kurian T, Lin HY, Rawal B, Kim T, Sexton WJ, et al. Preoperative metastatic status, level of thrombus and body mass index predict overall survival in patients undergoing nephrectomy and inferior vena cava thrombectomy. *BJU Int*. 2012; 110: E470-474.
26. Sidana A, Goyal J, Aggarwal P, Verma P, Rodriguez R. Determinants of outcomes after resection of renal cell carcinoma with venous involvement. *Int Urol Nephrol*. 2012; 44: 1671-1679.
27. Martínez-Salamanca JI, Huang WC, Millán I, Bertini R, Bianco FJ, Carballido JA, et al. International Renal Cell Carcinoma-Venous Thrombus Consortium. Prognostic impact of the 2009 UICC/AJCC TNM staging system for renal cell carcinoma with venous extension. *Eur Urol*. 2011; 59: 120-127.
28. Klaver S, Joniau S, Suy R, Oyen R, Van Poppel H. Analysis of renal cell carcinoma with subdiaphragmatic macroscopic venous invasion (T3b). *BJU Int*. 2008; 101: 444-449.
29. Ficarra V, Galfano A, Guillé F, Schips L, Tostain J, Mejean A, et al. A new staging system for locally advanced (pT3-4) renal cell carcinoma: a multicenter European study including 2,000 patients. *J Urol*. 2007; 178: 418-424.
30. Leibovich BC, Cheville JC, Lohse CM, Zincke H, Kwon ED, Frank I, et al. Cancer specific survival for patients with pT3 renal cell carcinoma-can the 2002 primary tumor classification be improved? *J Urol*. 2005; 173: 716-719.
31. Kim HL, Zisman A, Han KR, Figlin RA, Beldegrun AS. Prognostic significance of venous thrombus in renal cell carcinoma. Are renal vein and inferior vena cava involvement different? *J Urol*. 2004; 171: 588-591.
32. Blute ML, Leibovich BC, Lohse CM, Cheville JC, Zincke H. The Mayo Clinic experience with surgical management, complications and outcome for patients with renal cell carcinoma and venous tumour thrombus. *BJU Int*. 2004; 94: 33-41.
33. Gettman MT, Boelter CW, Cheville JC, Zincke H, Bryant SC, Blute ML. Charlson co-morbidity index as a predictor of outcome after surgery for renal cell carcinoma with renal vein, vena cava or right atrium extension. *J Urol*. 2003; 169: 1282-1286.
34. Staehler G, Brkovic D. The role of radical surgery for renal cell carcinoma with extension into the vena cava. *J Urol*. 2000; 163: 1671-1675.
35. Ljungberg B, Stenling R, Osterdahl B, Farrelly E, Aberg T, Roos G. Vein invasion in renal cell carcinoma: impact on metastatic behavior and survival. *J Urol*. 1995; 154: 1681-1684.
36. Manassero F, Mogorovich A, Di Paola G, Valent F, Perrone V, Signori S, et al. Renal cell carcinoma with caval involvement: contemporary strategies of surgical treatment. *Urol Oncol*. 2011; 29: 745-750.
37. Hatcher PA, Anderson EE, Paulson DF, Carson CC, Robertson JE. Surgical management and prognosis of renal cell carcinoma invading the vena cava. *J Urol*. 1991; 145: 20-23.
38. Whitson JM, Reese AC, Meng MV. Population based analysis of survival in patients with renal cell carcinoma and venous tumor thrombus. *Urol Oncol*. 2013; 31: 259-263.
39. Lambert EH, Pierorazio PM, Shabsigh A, Olsson CA, Benson MC, McKiernan JM. Prognostic risk stratification and clinical outcomes in patients undergoing surgical treatment for renal cell carcinoma with vascular tumor thrombus. *Urology*. 2007; 69: 1054-1058.
40. Glazer AA, Novick AC. Long-term followup after surgical treatment for renal cell carcinoma extending into the right atrium. *J Urol*. 1996; 155: 448-450.
41. Libertino JA, Zinman L, Watkins E Jr. Long-term results of resection of renal cell cancer with extension into inferior vena cava. *J Urol*. 1987; 137: 21-24.
42. Tilki D, Hu B, Nguyen HG, Dall'Era MA, Bertini R, Carballido JA, et al. Impact of Synchronous Metastasis Distribution on Cancer Specific Survival in Renal Cell Carcinoma after Radical Nephrectomy with Tumor Thrombectomy. *J Urol*. 2015; 193: 436-442.
43. Bissada NK, Yakout HH, Babanouri A, Elsalamony T, Fahmy W, Gunham M, et al. Long-term experience with management of renal cell carcinoma involving the inferior vena cava. *Urology*. 2003; 61: 89-92.
44. Montie JE, el Ammar R, Pontes JE, Medendorp SV, Novick AC, Strem SB, et al. Renal cell carcinoma with inferior vena cava tumor thrombi. *Surg Gynecol Obstet*. 1991; 173: 107-115.
45. Bazzi WM, Sjoberg DD, Feuerstein MA, Maschino A, Verma S, Bernstein M, et al. Long-Term Survival Rates after Resection for Locally Advanced Kidney Cancer: Memorial Sloan Kettering Cancer Center 1989-2012 Experience. *J Urol*. 2015; 193: 1911-1917.
46. Capitanio U, Suardi N, Matloob R, Roscigno M, Abdollah F, Di Trapani E, et al. Extent of lymph node dissection at nephrectomy affects cancer-specific survival and metastatic progression in specific sub-categories of patients with renal cell carcinoma (RCC). *BJU Int*. 2014; 114: 210-215.
47. Phillips CK, Taneja SS. The role of lymphadenectomy in the surgical management of renal cell carcinoma. *Urol Oncol*. 2004; 22: 214-223.
48. Campbell SC, Lane BR. Malignant renal tumours. W: Wein AJ, Kavoussi LR, Novick AC, Partin AW, Peters CA, editors. *Campbell's urology*. 10th edn. Saunders, Philadelphia. 2012; 1413-1474.
49. Zisman A, Wieder JA, Pantuck AJ, Chao DH, Dorey F, Said JW, et al. Renal cell carcinoma with tumor thrombus extension: biology, role of nephrectomy and response to immunotherapy. *J Urol*. 2003; 169: 909-916.
50. Simmons MN, Weight CJ, Gill IS. Laparoscopic radical versus partial nephrectomy for tumors >4 cm: intermediate-term oncologic and functional outcomes. *Urology*. 2009; 73: 1077-1082.
51. Nadler RB, Loeb S, Clemens JQ, Butler RA, Gonzalez CM, Vardi IY. A prospective study of laparoscopic radical nephrectomy for T1 tumors--is transperitoneal, retroperitoneal or hand assisted the best approach? *J Urol*. 2006; 175: 1230-1233.
52. Flanigan RC, Mickisch G, Sylvester R, Tangen C, Van Poppel H, Crawford ED. Cytoreductive nephrectomy in patients with metastatic renal cancer: a combined analysis. *J Urol*. 2004; 171: 1071-1076.
53. Haddad AQ, Wood CG, Abel EJ, Krabbe LM, Darwish OM, Thompson RH, et al. Oncologic outcomes following surgical resection of renal cell carcinoma with inferior vena caval thrombus extending above the hepatic veins: a contemporary multicenter cohort. *J Urol*. 2014; 192: 1050-1056.
54. Parekh DJ, Cookson MS, Chapman W, Harrell F Jr, Wells N, Chang SS, et al. Renal cell carcinoma with renal vein and inferior vena caval involvement: clinicopathological features, surgical techniques and outcomes. *J Urol*. 2005; 173: 1897-1902.
55. Bertini R, Roscigno M, Freschi M, Strada E, Angiolilli D, Petralia G, et al. Impact of venous tumour thrombus consistency (solid vs friable) on cancer-specific survival in patients with renal cell carcinoma. *Eur Urol*. 2011; 60: 358-365.
56. Cheville JC, Lohse CM, Zincke H, Weaver AL, Blute ML. Comparisons of outcome and prognostic features among histologic subtypes of renal cell carcinoma. *Am J Surg Pathol*. 2003; 27: 612-624.
57. Patard JJ, Leray E, Rioux-Leclercq N, Cindolo L, Ficarra V, Zisman A, et al. Prognostic value of histologic subtypes in renal cell carcinoma: a multicenter experience. *J Clin Oncol*. 2005; 23: 2763-2771.
58. Kaushik D, Linder BJ, Thompson RH, Eisenberg MS, Lohse CM, Cheville JC, et al. The impact of histology on clinicopathologic outcomes for patients with renal cell carcinoma and venous tumor thrombus: a matched cohort analysis. *Urology*. 2013; 82: 136-141.

59. Ciancio G, Manoharan M, Katkooi D, De Los Santos R, Soloway MS. Long-term survival in patients undergoing radical nephrectomy and inferior vena cava thrombectomy: single-center experience. *Eur Urol.* 2010; 57: 667-672.
60. Margulis V, Tamboli P, Matin SF, Swanson DA, Wood CG. Analysis of clinicopathologic predictors of oncologic outcome provides insight into the natural history of surgically managed papillary renal cell carcinoma. *Cancer.* 2008; 112: 1480-1488.
61. Kim KH, You D, Jeong IG, Kwon TW, Cho YM, Hong JH, et al. Type II papillary histology predicts poor outcome in patients with renal cell carcinoma and vena cava thrombus. *BJU Int.* 2012; 110: E673-678.
62. Yazici S, Inci K, Bilen CY, Gudeloglu A, Akdogan B, Ertoy D, et al. Renal cell carcinoma with inferior vena cava thrombus: the Hacettepe experience. *Urol Oncol.* 2010; 28: 603-609.
63. Fuhrman SA, Lasky LC, Limas C. Prognostic significance of morphologic parameters in renal cell carcinoma. *Am J Surg Pathol.* 1982; 6: 655-663.
64. Kuroda N, Ohe C, Mikami S, Inoue K, Nagashima Y, Cohen RJ, et al. Multilocular cystic renal cell carcinoma with focus on clinical and pathobiological aspects. *Histol Histopathol.* 2012; 27: 969-974.
65. Hermanek P, Sigel A, Chlephas S. Histological grading of renal cell carcinoma. *Eur Urol.* 1976; 2: 189-191.
66. Weiss VL, Braun M, Perner S, Harz A, Vorreuther R, Kristiansen G, et al. Prognostic significance of venous tumour thrombus consistency in patients with renal cell carcinoma (RCC). *BJU Int.* 2014; 113: 209-217.
67. Laird A, O'Mahony FC, Nanda J, Riddick AC, O'Donnell M, Harrison DJ, et al. Differential expression of prognostic proteomic markers in primary tumour, venous tumour thrombus and metastatic renal cell cancer tissue and correlation with patient outcome. *PLoS One.* 2013; 8: e60483.
68. Verghe DC, Kneitz S, Kalogirou C, Burger M, Krebs M, Rosenwald A, et al. Impact of miR-2, miR-126 and miR-221 as prognostic factors of clear cell renal cell carcinoma with tumor thrombus of the inferior vena cava. *PLoS One.* 2014; 9: e109877.
69. Abel EJ, Carrasco A, Karam J, Tamboli P, Delacroix S, Vaporciyan AA, et al. Positive vascular wall margins have minimal impact on cancer outcomes in patients with non-metastatic Renal Cell Carcinoma (RCC) with tumour thrombus. *BJU Int.* 2014; 114: 667-673.