

A Case Report on Ulcerative Colitis with
Interventional OutcomesSandeep RJ¹, Hari HC², Jyothsna RD² and Mahender V^{2*}¹Department of Gastroenterology, Rohini Super Specialty Hospital, India²Department of Pharmacy Practice, St. Peter's Institute of Pharmaceutical Sciences, India

Article Information

Received date: Nov 15, 2016

Accepted date: Dec 21, 2016

Published date: Dec 28, 2016

*Corresponding author

Mahender V, Department of Pharmacy Practice, St. Peter's Institute of Pharmaceutical Sciences, India, Email: mahi.reddy125@gmail.com

Distributed under Creative Commons CC-BY 4.0

Keywords Ulcerative colitis; Drug-drug interactions; Adverse effect; Colonoscopy

Abstract

Ulcerative Colitis (UC) is a mucosal disease that usually involves the rectum and extends proximally to involve all or part of the colon. Main causes are gut microbiota, dysregulation of the host's immune system, genetic susceptibility and environmental factors. Active disease can be associated with a rise in acute phase reactants [C - reactive protein (CRP)], platelet count and Erythrocyte Sedimentation Rate (ESR) and a decrease in hemoglobin. Colonoscopy is used to assess disease activity and is often performed before treatment. In this case, recurrence UC was observed and it was treated with suitable therapy but some drug interactions like metronidazole additive effect with ofloxacin results in ST-T elevation and adverse effects like abdominal pain, burning pain in midsternal area radiating to epigastric region [Calcium+Vitamin-D] were seen. Those are monitored by the alternative therapy like dose management and drug alterations.

Introduction

Ulcerative Colitis (UC) is a mucosal disease that usually involves the rectum and extends proximally to involve all or part of the colon. About 40-50% of patients limited to the rectum and rectosigmoid, 30-40% extending beyond the sigmoid but not the whole colon and 20% have a total colitis. When the whole colon is involved, the inflammation extends 1-2 cm into the terminal ileum and is of little clinical significance [1].

Epidemiology

The global prevalence of UC has seen a discernible shift in the past decade. UC once considered to be common in the Western population has witnessed a relative stable or decreasing trend in Western European region [2]. However, its prevalence has seen an upsurge in previously low incidence areas, such as Asia, Eastern Europe and North Indians. Except for a couple of studies from North India in 1965 and 2003 [3-8] there is a dearth of reports on the present prevalence pattern of UC in India. Prevalence of ulcerative colitis to be predominant at the young age (<35 years). Further, gluten-rich diet and out- side food were found to be important factors responsible for increased prevalence. Non- smokers/ex-smokers were found to be high in terms of UC prevalence [9].

Etiology

A consensus hypothesis is that in genetically predisposed individuals, both exogenous factors (e.g., normal luminal flora) and host factors (e.g., intestinal epithelial cell barrier function, innate and adaptive immune function) cause a chronic state of dysregulated mucosal immune function that is further modified by specific environmental factors (e.g., smoking). Although chronic activation of the mucosal immune system may represent an appropriate response to an unidentified infectious agent, a search for such an agent has thus far been unrewarding [1].

Pathophysiology

Antibodies and B-cells: An increase of lymphocytes, especially activated T-cells and IgG containing B-cells, is seen in the colonic mucosa. This may induce the increased production of antibodies directed against intestinal antigens and auto antigens that may contribute to the pathogenesis of this disease.

Cytokines and T-cells: Defective mucosal immunoregulation, including abnormal changes of T-cells, B-cells, granulocytes, macrophages and the cytokines and chemokines produced by these cells resulting in uncontrolled and sustained inflammation [10].

Clinical Presentation

The major symptoms of UC are diarrhea, rectal bleeding, tenesmus, passage of mucus and crampy abdominal pain. The severity of symptoms correlates with the extent of disease. Although UC can present acutely, symptoms usually have been present for weeks to months. Occasionally,

Table 1: Ulcerative colitis: Disease presentation.

	Mild	Moderate	Severe
Bowel movements	<4 per day	4-6 per day	>6 per day
Blood in stool	Small	Moderate	Severe
Fever	None	37.5°C mean	>37.5°C mean
Tachycardia	None	<90 mean pulse	>90 mean pulse
Anemia	Mild	>75%	>75%
Sedimentation rate	<30 mm		>30 mm
Endoscopic appearance	Erythema, decreased vascular pattern, fine granularity	Marked erythema, coarse granularity absent vascular markings, contact bleeding, no ulcerations	Spontaneous bleeding, ulcerations

diarrhea and bleeding are so intermittent and mild that the patient does not seek medical attention (Table 1).

Laboratory, Endoscopic and Radiographic Features

Active disease can be associated with a rise in acute phase reactants [C - reactive protein (CRP)], platelet count and Erythrocyte Sedimentation Rate (ESR) and a decrease in hemoglobin. Fecal calprotectin levels correlate well with histologic inflammation, predict relapses and detect pouchitis. Sigmoidoscopy is used to assess disease activity and is often performed before treatment. If the patient is not having an acute flare, colonoscopy is used to assess disease extent and activity [1].

Treatment

Therapeutic options can be divided into those that attempt to modify the presumed etiopathogenesis of UC and those that attempt to control the symptoms. Most patients with UC experience relapse and disease progression during their clinical course. Therapy for UC has been categorized an induction therapy, maintenance therapy, treatment for refractory disease and surgery. Efficacious acute therapy and safe maintenance therapy are essential for the medical treatment of UC. Physicians should treat patients according to the revised guidelines prepared by the Ministry of Health and Welfare disease study group in 1998, taking into account the severity, extent and type of disease in individual cases. Aminosalicylate preparations (5-ASA), corticosteroids and immunomodulators are the three main classes of agents used in the medical treatment of UC. Antispasmodics (primarily anticholinergic agents) and antidiarrheal preparations are recommended to improve the symptoms that accompany UC. Low doses of antidepressants are occasionally employed to ameliorate Inflammatory Bowel Syndrome (IBS) symptoms in patients with UC [10].

Complications

- Only 15% of patients with UC present initially with catastrophic illness. Massive hemorrhage occurs with severe attacks of disease in 1% of patients and treatment for the disease usually stops the bleeding. However, if a patient requires 6-8 units of blood within 24-28 h, colectomy is indicated.
- Perforated bowel-chronic inflammation of the intestine may weaken the intestinal wall to such an extent that a hole develops
- Toxic megacolon- severe inflammation leads to rapid enlargement of the colon [11].

Case Report

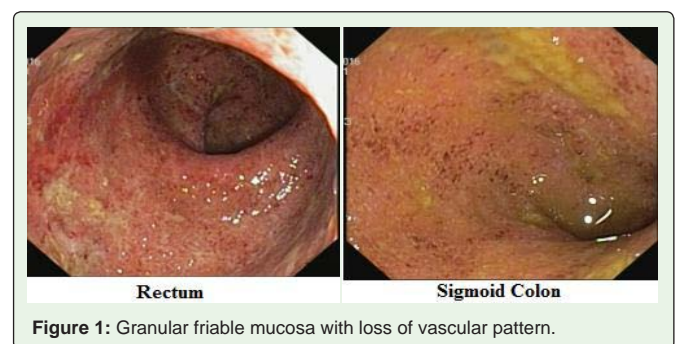
A 45 year adult female patient, weighing about 54kg admitted in a Tertiary Care Hospital of Gastroenterology ward with the complaints of loose stools for every 15 minutes since 1 month with mucous and blood, abdominal pain and nausea. Previously she was suffered with Ulcerative Colitis (UC) with similar complaints one year back and recovered by taking medications for about 6months, family history was unknown.

Day-1: On examination was normal and Vital signs of elevated temperature (99°F), symptoms was treated with the Ofloxacin 200mg BID, Metronidazole 5mg/ml TID, Hydrocortisone-100mg BID, Mesalamine 800mg TID, Calcium+vitamin-D 50mg. IV fluids- DNS and RL 1 pint and advices of complete blood picture (Hemoglobin count-11.5gm%), ESR (34mm/hour), Serum electrolyte estimation (Normal), sigmoidoscopy (Small hemorrhoids-UC) (Figure 1).

Day-2: C/o- Neck pain, general weakness, abdominal pain, loose motions for every 10 minutes with blood. Advices are thyroid profile test (normal), 2D echo (Sclerotic aortic valve and Mild Tricuspid valve regurgitation) ECG (ST-T elevation), Trop-T (negative), CPK-MB (negative) and Hydrocortisone changed to Prednisolone 40mg OD, continued the same medications.

Day-3: C/o- Neck pain, chest pain at right side, burning pain in midsternal area radiating to epigastric, loose motions 6 episodes at night with blood, mild abdominal pain. Stop Calcium+Vitamin-D (because acute gastritis observed) Sucralfate-O-Gel 10ml TID, Ofloxacin/ornidazole 200 /500mg OD, Prednisolone 40mg OD and continued the same medication.

Day-4: C/o- Loose motions with blood 6 episodes, pain in abdomen and continued the same medication.



Day-5: C/o- Loose motions with blood 3 episodes at night and continued the same medication.

Day-6: C/o- Loose motions with blood were decreased and patient was kept on observation for one day and discharged with stable condition.

Role of pharmacist in improving patient health and decrease prescription errors

Interventions

Drug interaction: On Day-2 Drug-Drug interaction was found and it was a major interaction.

Metronidazole+Ofloxacin: It shows additive ST-T elevation and it is clinically managed by ECG Monitoring and alteration of dose of any drug, in this patient Metronidazole 5mg/ml TID reduced to BID.

ADR: On Day-3 Calcium+Vitamin-D 500mg OD causes acute gastritis (Mild abdominal pain, burning pain in midsternal area radiating to epigastric region) so it was stopped but in the discharge medication chart it was prescribed to maintain vitamin-D levels in UC disease condition.

Points to patient by clinical pharmacist: Maintain normal body weight, high intake of fiber containing foods, consume diet rich in antioxidants, fruits, vegetables, decrease intake of spicy food & potassium intake, high intake fluid to overcome fluid imbalance.

Discussion

Limited data suggest that metronidazole may rarely prolong the QT interval of the electrocardiogram. In general, the risk of an individual agent or a combination of agents causing ventricular arrhythmia in association with QT prolongation is largely unpredictable but may be increased by certain underlying risk factors such as congenital long QT syndrome, cardiac disease and electrolyte disturbances (e.g., hypokalemia, hypomagnesemia) [12]. But in this case from day 1 to day last serum electrolytes are normal and absence of past cardiac diseases. So it was mainly due to the drug interaction of metronidazole additive effect with ofloxacin results in ST-T elevation but no elevation/prolongation of QT interval. Thus, vitamin D deficient IBD patients are at an increased risk of fractures and low bone density, especially if they have longstanding disease, or have long courses of steroids [13]. But in this case Calcium+Vitamin-D 500mg OD causes Mild abdominal pain, burning pain in midsternal area radiating to epigastric region. So it was discontinued for few days and then added in the discharge medication chart to maintain vitamin-D levels.

Conclusion

In this case, recurrence UC was observed and it was treated with suitable therapy but some drug interactions like metronidazole additive effect with ofloxacin results in ST-T elevation but no elevation/prolongation of QT interval and adverse effect like abdominal pain, burning pain in midsternal area radiating to epigastric region [Calcium+Vitamin-D] were seen and those are monitored by the alternative therapy like dose management and drug alterations.

References

- Dan LL, Anthony SF. Harrison's-Gastroenterology and Hepatology. McGraw-Hill Professional Publishing, 2010; 17: 175-181.
- Molinie F, Gower-Rousseau C, Yzet T, Merle V, Grandbastien B, et al. Opposite evolution in incidence of Crohn's disease and ulcerative colitis in Northern France (1988-1999). *Gut*. 2004; 53: 843-848.
- Sincic BM, Vucelic B, Persic M, Brncic N, Erzen DJ, et al. Incidence of inflammatory bowel disease in Primorsko-goranska County, Croatia, 2000-2004: A prospective population-based study. *Scand J Gastroenterol*. 2006; 41: 437-444.
- Lakatos PL, Fischer S, Lakatos L. Is the epidemiology of inflammatory bowel disease changing in Eastern Europe? *Scand J Gastroenterol*. 2006; 41: 870-871.
- Thia KT, Loftus EV Jr, Sandborn WJ, Yang SK. An update on the epidemiology of inflammatory bowel disease in Asia. *Am J Gastroenterol*. 2008; 103: 3167-3182.
- Sood A, Midha V, Sood N, AS Bhatia, G Avasthi. Incidence and prevalence of ulcerative colitis in Punjab, North India. *Gut*. 2003; 52: 1587-1590.
- Siew CN. Changing epidemiology and future challenges of inflammatory bowel disease in Asia. *Intes Research*. 2010; 8: 1-8.
- Tandon BN, Mathus AK, Mohapatra LN, HD Tandon, KL Wig. A study of the prevalence and clinical pattern of non-specific ulcerative colitis in northern India. *Gut*. 1965; 6: 448-453.
- Sivaram Gunisetty, Santosh Kumar Tiwari, Avinash Bardia, Meka Phanibhushan, Vishnupriya Satti, et al. The epidemiology and prevalence of Ulcerative colitis in the South of India. *Open Journal of Immunology*. 2012; 4: 144-148.
- Toshifumi HIBI. Pathogenesis and Treatment of Ulcerative Colitis. *JMAJ*. 2003; 46: 258-260.
- Ephgrave K. Extra intestinal manifestations of Crohn's disease. *Surg Clin North Am*. 2007; 87: 673-680.
- Kounas SP, Letsas KP, Sideris A, Efraimidis M, Kardaras F. QT interval prolongation and torsades de pointes due to a coadministration of metronidazole and amiodarone. *Pacing Clin Electrophysiol*. 2005; 28: 472-473.
- Reich KM, Fedorak RN, Madsen K, Kroeker KI. Vitamin D improves inflammatory bowel disease outcomes: Basic science and clinical review. *World J Gastroenterol*. 2014; 20: 4934-4947.