

Indications and Clinical Utility of  
Sternal Aspirates in Patients with  
Multiple Myeloma and Other Plasma Cell  
DyscrasiasJozef Malysz<sup>1\*</sup>, Nicole Leeper<sup>2</sup>, Cinda M Boyer<sup>3</sup>, Joseph J Drabick<sup>4</sup> and Giampaolo Talamo<sup>5</sup><sup>1</sup>Associate Professor, Hematopathology, Penn State Milton S Hershey Medical Center/PennState Hershey Cancer Institute, USA<sup>2</sup>Laboratory Associate, Department of Pathology, Penn State Milton S Hershey Medical Center, USA<sup>3</sup>Basic Research Scientist, Special Hematology/Department of Pathology, Penn State Milton S Hershey Medical Center, USA<sup>4</sup>Professor and Division Chief, Division of Hematology-Oncology, Penn State Milton S Hershey Medical Center/PennState Hershey Cancer Institute, USA<sup>5</sup>Associate Professor of Medicine, Division of Hematology-Oncology, Penn State Milton S Hershey Medical Center/PennState Hershey Cancer Institute, USA

## Article Information

Received date: Sep 21, 2017

Accepted date: Nov 10, 2017

Published date: Nov 15, 2017

## \*Corresponding author

Jozef Malysz, Associate Professor,  
Hematopathology, Penn State Milton  
S Hershey Medical Center/PennState  
Hershey Cancer Institute, 500 University  
Drive, Hershey, PA 17033, USA,  
Tel: 717-531-1676; Fax: 717-531-7741;  
Email: jmalysz@pennstatehealth.psu.  
edu

Distributed under Creative Commons  
CC-BY 4.0

**Keywords** Sternal aspirate; Bone  
marrow biopsy; Multiple myeloma;  
Plasma cell dyscrasia; Amyloidosis

## Abstract

**Background:** A Bone Marrow (BM) evaluation is often required in patients with plasma cell dyscrasias, at the time of initial presentation for diagnostic purposes and risk stratification, and during the follow up for an accurate assessment of the response to therapy. In the vast majority of cases, the preferred site for obtaining a BM specimen is the posterior superior iliac crest. The role of sternal aspirates has fallen out of favor in 21<sup>st</sup> century medical practice. However, in certain clinical situations it appears to be the easiest site for specimen collection. Our study was designed to answer a set of basic clinical questions such as whether sternal Bone Marrow Aspirate (BMA) can provide reliable and sufficient specimen for morphologic, immunophenotypic and molecular evaluation of patients with clinical suspicion of plasma cell dyscrasias.

**Methods:** We reviewed indications, performed BM biopsies and obtained BMA from sternum in 51 patients with Multiple Myeloma (MM) and other plasma cell dyscrasias.

**Results:** No significant complications were observed. The most common indication for the sternal aspirates were: inability to reach the pelvic bone due to morbid obesity (65% of cases), followed by other factors, such as tetraplegia/immobility, pelvic fractures, infections, or radiotherapy. The concordance with the disease status, as defined by the presence or absence of a detectable paraprotein, was excellent, observed in 91.7% of samples.

**Conclusions:** Sternal aspirates provided satisfactory samples not only for morphologic evaluation, but also for ancillary studies, such as flow cytometry, metaphase cytogenetics, and Fluorescence *In Situ* Hybridization (FISH) studies.

## Background

Plasma cell dyscrasias are hematologic disorders that include Monoclonal Gammopathy of Undetermined Significance (MGUS), Multiple Myeloma (MM), Solitary Plasmacytoma (SP), Extramedullary Plasmacytoma (EMP), primary AL amyloidosis, Monoclonal Immunoglobulin Deposition Disease (MIDD), and Plasma Cell Leukemia (PCL). A bone marrow evaluation is routinely required for all patients with these conditions, both as preferred specimen for diagnostic purposes and risk stratification, and during the follow up to evaluate course of the disease and response to therapy [1]. Bone marrow samples can be obtained by aspiration and trephine biopsy. In the vast majority of cases, the preferred site for a bone marrow aspirate and biopsy is the posterior superior iliac crest of the pelvis. Sternal aspirates can provide an excellent samples of the cellular components of the bone marrow, but they are rarely performed, usually only in situations of extreme technical difficulties in obtaining BM biopsy from traditional location, for example when patients are morbidly obese or immobile, with a skin or soft tissue infection over the posterior pelvis, or in case of a previously irradiated pelvis [2]. It is unclear whether BMA of the sternal marrow provides representative specimens satisfactory for the evaluation of patients with plasma cell dyscrasias. In fact, the medical literature describing the use of sternal aspirates was published more than 60 years ago [3-5], and their value in the assessment of immunophenotypic and cytogenetic studies of plasma cell dyscrasias has not been reported. In this study, we evaluated indications and outcomes of 51 consecutive sternal aspirates in patients with plasma cell neoplasms.

**Methods**

We identified and retrospectively reviewed data of all patients with a diagnosis of plasma cell dyscrasias followed at our institution between July 2008 and February 2016. Among 1,109 patients, we found 51 who underwent a sternal aspirate for marrow evaluation, and we reviewed their electronic medical records. Sternal aspirates were performed by one of the authors (GT) with a previously described technique [2]. Aspirates were obtained from the medial part of the manubrium of the sternum, at the level of the first intercostal space, as shown in Figure 1. The periosteum was anesthetized with 5 mL of 1% lidocaine. The needle with a secured guard was advanced to penetrate approximately 5 mm of bone beyond the depth of the periosteum. The BM aspirate underwent morphological evaluation by a pathologist, and quantification of plasma cells was obtained by differential count of 200 nucleated marrow cells in each sample.

Flow cytometry was performed on heparinized bone marrow samples using a 6-color BDFACS Canto flow cytometer (BD Biosciences, San Jose CA). Marrow aspirates were stained with fluorescein-conjugated antibodies to the cell surface antigens CD19, CD20, CD33, CD38, CD45, CD56, CD117, CD138, and cytoplasmic kappa and lambda light chains (BD Biosciences). Red blood cells were lysed with the Fix and Perm Cell Permeabilization Kit (Life Technologies, Frederick MD). Data was collected on the flow cytometer (200,000 events per tube) and analyzed using FCS Express analysis software (DeNovo Software Version 3, Los Angeles CA). Flow cytometric data was interpreted by a hematopathologist in conjunction with bone marrow aspirate smears.

The BM aspirate was defined as “involved” when flow cytometry was positive for monotypic plasma cells (regardless of the percentage of plasma cells in the differential count), and “uninvolved” when the flow cytometry was negative. Metaphase cytogenetics and FISH were ordered only in cases with a positive flow cytometry. Paraproteins were detected by a panel of laboratory tests done in all patients, which included quantitative immunoglobulins, serum free light chains, Serum Protein Electrophoresis (SPEP) with quantification of the M component, serum immunofixation (IFE), and urine immunofixation (uIFE) in a random sample.

**Table 1:** Indications for sternal aspirates in 51 patients with plasma cells dyscrasias.

Indication	Number and % of Patients
<b>Related to the Disease</b>	
- BM biopsy from pelvis negative at baseline	3 (6%)
<b>Related to the Procedure</b>	
- BM biopsy from pelvis unsuccessful	2 (4%)
<b>Related to the Anatomy</b>	
- Distorted pelvic anatomy	1 (2%)
- Acute Pelvic fracture	1 (2%)
- Previous pelvic RT	1 (2%)
- Cellulitis of tissues around pelvis	1 (2%)
<b>Related to Other Patient Variables</b>	
- Obesity	33 (65%)
- Paraplegia/tetraplegia due to SCC	3 (6%)
- Immobility from endotracheal intubation	2 (4%)
- Immobility due to other factors	2 (4%)
- Severe orthopnea	2 (4%)

**Results**

Sternal aspirates were performed in 51 of 1,109 (4.6%) patients with plasma cell dyscrasias; 19 male patients (37%) and 32 female patients (63%). Median age at diagnosis was 61 years (range, 38-86). The clinicopathological diagnosis was MM (28 pts), MGUS (15), smoldering myeloma (4), AL amyloidosis (1), SP (1), EMP (1), and MIDD (1). The secreted paraprotein type was IgG-kappa (14 pts), IgA-lambda (10), IgA-kappa (8), IgG-lambda (7), kappa light chain (6), lambda light chain (4), IgD-lambda (1), and IgM-kappa (1). The sternal aspirate was done at various stages of the disease course: at diagnosis (32 pts), remission after conventional chemotherapy (6), remission after an autologous stem cell transplant (6), and at disease relapse or progression (7). The indications for obtaining the sternal aspirates are shown in Table 1. In 3 patients with MM, the initial BM biopsy from the pelvis was negative, but a repeated aspirate from the sternum provided the diagnosis. In the majority of cases (33 patients, 65%), the reason for obtaining a sternal aspirate was morbid obesity (class III). In these patients, the needle used for the pelvic biopsy was unable to reach the bone, due to the abundance of subcutaneous tissues. Seven patients were unable to be placed in lateral decubitus or prone position, due to various reasons (endotracheal intubation, or paraplegia/tetraplegia from MM-related spinal cord compression), and only the sternal area could be easily approached. In other 2 patients, a sternal aspirate was performed in a sitting position, due to inability to lie down because of severe orthopnea.

In 3 of 51 cases (5.9%), the sternal aspirates resulted in a “dry tap” (no marrow sample could be obtained). No significant complications were observed. Specifically, none of our patients required medical evaluation for hematomas, infections, or fractures at the aspiration site. The sternal BM was found to be involved by clonal plasma cells in 36 patients (70.6%). In these patients, the mean percentage of plasma cells detected was 21.4% (SD 26.3, range 0-90) by morphologic analysis, and 8% (SD 16.6, range 0-80) by flow cytometry. Cytogenetic analysis and FISH were performed in 29 patients. Metaphase cytogenetics were normal in all patients, except for 2 cases, which revealed a complex karyotype. FISH was positive in 21 of 29 (72.4%) evaluable patients, with the following findings in various combinations: monosomy 13 (10 pts), 1q21+ (7), trisomies (6), t(11;14) (5), 17p- (4), atypical IgH rearrangement (4), t(4;14) (3), and monosomy 16 (1). We analyzed the concordance between the presence of a paraprotein (in either blood or urine) and the involvement of the BM biopsy, and we found that the findings were concordant: both positive and both negative in 44 of 48 (91.7%) evaluated cases (Table 2). A discrepancy was found in 4 cases. In 1 patient, the sternal aspirate showed MM, but serum

**Table 2:** Concordance between presence of paraproteins and involvement of sternal aspirate in 48 patients with plasma cell dyscrasias.

Paraprotein*	Sternal Marrow**	N. PTS
positive	positive	31 (65%)
positive	negative	3 (6%)
negative	positive	1 (2%)
negative	negative	13 (27%)

\* Detected in blood and/or urine by quantitative immunoglobulins, serum free light chains, SPEP, IFE, and uIFE.

\*\* Defined by the results of flow cytometry for plasma cells.

and urine were negative for a paraprotein. This patient was diagnosed with nonsecretory MM. In other 3 patients, the sternal aspirate was negative, but they had a paraprotein detected in the blood. Of note, review of their medical records showed that all 3 patients had a very low quantity (100 mg/dL or less) of IgG-kappa paraprotein found at the serum IFE/SPEP, and their other laboratory tests and clinical follow-up supported the diagnosis of MGUS.

## Discussion

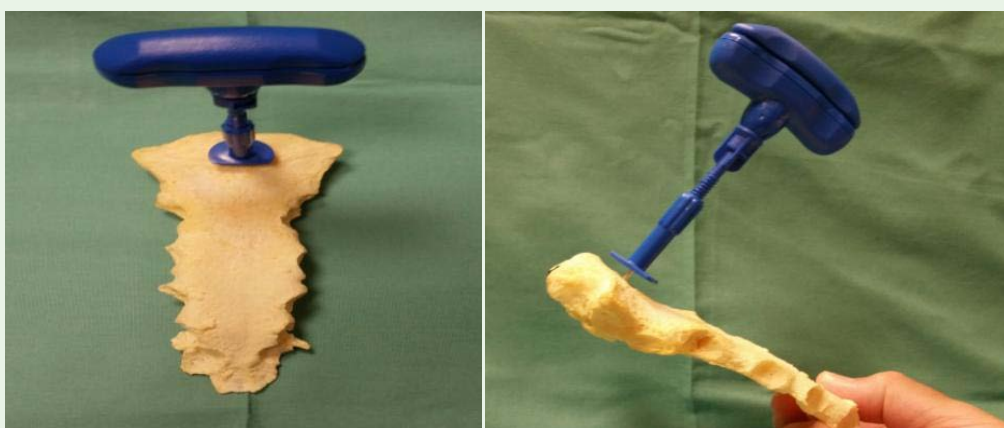
The commonly accepted method of obtaining a BM sample from patients with plasma cells dyscrasias and other hematologic disorders is an aspirate and biopsy from the posterior superior iliac crest of the pelvis, and sternal aspirates are only rarely performed. The technique of aspiration of sternal bone marrow was first introduced by Arinkin in 1929 [6], and the first sternal aspiration on a patient with MM was performed at the Mayo Clinic in 1939 [4]. The use of sternal aspirates in MM has not been widely accepted, for various reasons. Some experts are afraid of false negative results, because the marrow involvement in MM may be patchy, whereas others wrote guidelines that discourage the use of the sternal approach, due to the bone resorption associated with this cancer [7]. Yet, there are clinical situations where the sternal approach should be considered, as indicated by our series of 51 patients, namely patient immobility, due to paraplegia or tetraplegia from spinal cord compression, endotracheal intubation, local factors related to the pelvis, such as an pelvic fracture, active infection of the skin or soft tissues or other conditions, which may prevent safe and reasonably easy pelvic approach. Most common indication for sternal aspirates, in our experience, was morbid obesity. In 33 of 51 patients, the needle used for the BM biopsy did not reach the periosteum, due to the abundance of subcutaneous tissues in the posterior pelvis. This issue is particularly important, not only because of the current epidemic of obesity in developed countries, but also because of know association between MM and obesity [8].

The procedure of a sternal aspirate is simple and easy to perform, it does not cause any significant complications and no significant difference in patients discomfort was noted if proper technique was applied. We did not encounter sternal bleeding/hematomas, infections, sternal fractures, or other possible adverse events among 51 procedures performed. However, we are aware that accidents may

result if improper technique is applied, for example by pushing the needle too deep without a guard in place. The needle could puncture intrathoracic organs, in particular large vessels or the heart with potential complications of significant bleeding, hemopericardium and/or cardiac tamponade [9-11]. It is interesting to note that the appropriate site for the sternal puncture is controversial, because some authors recommend to perform BM biopsy in the middle part of the manubrium, at the level of the first intercostal space [11], whereas others do it in the midsternum, at the level of the second or third intercostal space, just to one side of the midline [12]. We used the first approach, due to the fact that potential for complications is minimized at that site and the bone is thickest at the manubrium level (Figure 1).

To the best of our knowledge, there are no prospective studies that have compared sternal versus iliac aspirates in humans, and this is understandable, due to increased potential for complications and patient discomfort if BM biopsy procedure was performed concomitantly at two different sites. Veterinary literature has provided randomized data that showed sternal aspirates provide samples equivalent or even superior in quality to those from the iliac crest in dogs [13] or the iliac tuber coxae in horses [14].

The most important limitation of the sternal approach is due to the fact that sternum is not recommended for the core biopsy and allows only obtaining of marrow aspirates. A trephine biopsy should never be performed on the sternum due to anatomically thin bone (approximately 1 cm thickness in adults), and potential for significant procedure related morbidity related to its proximity to blood vessels, pleura, lung, and heart. This may lead to significant bleeding with or without cardiac tamponade, pneumothorax, and/or sternal fractures [15]. There are several disadvantages of obtaining an aspirate alone: for example, it does not retain the architectural framework of the tissue, it may not represent all marrow cells (see below), and/or may result in a “dry tap”, when no marrow sample is obtainable by aspiration. In our experience, “dry tap” occurred in 3 patients, and in these cases, a trephine biopsy from another bone became necessary. Historically, the most common causes of a dry tap are poor technique, or intrinsic marrow condition such as fibrosis, marrow necrosis, and/or metastatic tumor infiltration.



**Figure 1:** Position of the BM biopsy needle in a sternum. Notice the presence of the adjustable depth guard, which is removed when using the posterior iliac crest approach, but for patient safety must remain in place during the sternal approach. Please note that the thickness of the manubrium is significantly greater than the lower sternum.

An aspirate allows enumeration of marrow plasma cells, best achieved by differential count. This is essential to diagnosis, classification, and monitoring of plasma cell dyscrasias (for example, it allows the distinction between MM and benign MGUS, based on the presence of more than 10% clonal plasma cells). However, the quantification of the plasma cell population in the BM is provided more precisely by the trephine biopsy than the aspirate, which tends to underestimate percentage of plasma cells, primarily due to hemodilution of the BMA specimens. An aspirate may underestimate the number of plasma cells also due to patchy distribution of plasma cells in patients with plasma cell dyscrasias, or the malignant plasma cells may remain attached to the reticulum fibers in the stromal marrow. Trephine biopsy allows CD138 staining, which consistently demonstrates a greater percentage of plasma cell population as compared with the aspirate. In a study of 59 MM patients, the median percentage of plasma cell infiltrate was 29% and 50% in the aspirate and biopsy, respectively [16]. Of note, flow cytometry of the aspirate further underestimates the number of marrow plasma cells. Our results are in agreement with those data, because we found a mean percentage of plasma cells of 21.4% and 8% by morphologic analysis of the aspirate and flow cytometry, respectively. The decreased number of plasma cells detected by flow cytometry is presumably due to the fact that the BM smears contain plasma cells associated with lipid-enriched spicules, whereas the flow cytometry is performed on the marrow fluid, which contains a lower number of lipid-adhesive plasma cells [17]. In our experience, dilution effects and loss of plasma cells during the processing procedures of the flow cytometry also plays a role. Mindful of those factors and despite limitations, marrow aspirates are usually sufficient for the diagnosis of plasma cell dyscrasias including the initial diagnosis of MM, if other specimen is difficult or impossible to obtain. In a comparative study of 31 MM patients, aspirates had a specificity and sensitivity of 100% and 88.5%, respectively, and trephine biopsy identified additional cases in only 7.7% of patients which were missed on aspirate [18]. However, that study did not evaluate the role of flow cytometry, which can increase the diagnostic accuracy.

While the quantification of BM plasma cells is better assessed by the biopsy, the aspirate is usually superior to the trephine biopsy in defining their morphologic features [16]. The morphology of plasma cells is important in the work-up of MM. Based on the degree of maturation, malignant plasma cells can be mature, intermediate, immature, and plasmablastic, and this distinction in patients with MM correlates with their clinical outcomes and prognosis [19].

Another limitation of obtaining only aspirates in plasma cell dyscrasias, without trephine biopsy is the absence of stromal tissue that can be stained with Congo red stain for the detection of amyloid deposits; however, previous studies have shown that amyloid deposits can occasionally be observed even in marrow aspirates, as pink or purple amorphous masses with entrapped plasma cells [20]. Our study included only one patient with amyloidosis, and therefore we cannot make any conclusion on this issue.

Our results suggest that in selected cases, diagnosis and assessment of disease progression and/or response to therapy could be done safely and accurately with sternal aspirates if posterior iliac crest aspirate and biopsy cannot be performed. The concordance between a positive or negative paraprotein study in serum and/or

urine, and the involvement of the sternal marrow was very high at 91.7%. The 4 cases which presented an apparent discordance could be explained: in one case, the paraprotein was absent and the sternal aspirate was involved, confirming plasma cell dyscrasia which was classified as non-secretory MM, and therefore the pelvic aspirate and biopsy would not have changed the diagnosis and management. In the other 3 patients, there was a very small amount (<100 mg/dL) of paraprotein of IgG-kappa type, and the rest of the laboratory data and clinical follow-up suggested that they had MGUS. Even in these cases the pelvic approach would not have changed the diagnosis and management. Some authors argue that at such low levels of IgG paraprotein, a BM biopsy may not even be necessary [21]. We found good concordance between clinical findings, laboratory results, and sternal aspirate analysis in all cases. Importantly, our study showed that sternal aspirates can provide adequate samples for ancillary tests, such as metaphase cytogenetics and Fluorescence *In Situ* Hybridization (FISH), which are essential for risk stratification in MM and other plasma cell dyscrasias.

## Conclusion

In the absence of randomized and prospective studies, our retrospective analysis suggests that a sternal aspirate alone can be sufficient for the initial diagnosis and follow-up of plasma cell dyscrasias in patients for whom posterior iliac crest biopsy is contraindicated or technically very challenging. We found good concordance between clinical findings, laboratory results, and sternal aspirate analysis in all cases. Sternal aspirates provide adequate samples for ancillary tests, such as metaphase cytogenetics and FISH.

## Key Message

In selected patients for whom posterior iliac crest marrow biopsy is medically contraindicated or technically very difficult to perform, evaluation of marrow for diagnosis, disease progression or response to therapy can be done safely and accurately with sternal aspirates instead.

## References

1. Anderson KC, Alsina M, Atanackovic D, Biermann JS, Chandler JC, Costello C, et al. Multiple Myeloma, Version 2.2016: Clinical Practice Guidelines in Oncology. *J Natl Compr Canc Netw*. 2015; 13: 1398-1435.
2. Bain BJ. Bone marrow aspiration. *J Clin Pathol*. 2001; 54: 657-663.
3. Falconer EF, Leonard ME. The value of sternal marrow aspiration as a method of bone marrow biopsy. *Ann Intern Med*. 1941; 15: 446-458.
4. Bayrd ED. The bone marrow on sternal aspiration in multiple myeloma. *Blood*. 1948; 3: 987-1018.
5. Mendell TH, Meranze DR, Meranze T. The clinical value of sternal bone marrow puncture. *Ann Intern Med*. 1942; 16: 1180-1196.
6. Arinkin ML. Die intravitale Untersuchungs Methodik des Knochenmarks. *Folia Haematol*. 1929; 38: 159-233.
7. Lee SH, Erber WN, Porwit A, Tomonaga M, Peterson LC. ICSH guidelines for the standardization of bone marrow specimens and reports. *Int J Lab Hematol*. 2008; 30: 349-364.
8. Carson KR, Bates ML, Tomasson MH. The skinny on obesity and plasma cell myeloma: a review of the literature. *Bone Marrow Transplant*. 2014; 49: 1009-1015.
9. Bain BJ. Bone marrow biopsy morbidity and mortality. *Br J Haematol*. 2003; 121: 949-951.



10. Bhootra BL. Fatality following a sternal bone marrow aspiration procedure: a case report. *Med Sci Law*. 2004; 44: 170-172.
11. Santavy P, Troubil M, Lonsky V. Pericardial tamponade: a rare complication of sternal bone marrow biopsy. *Hematol Rep*. 2013; 5: e13.
12. Neumark E. Sternal marrow biopsy. *Postgrad Med J*. 1949; 25: 478-482.
13. Defarges A, Abrams-Ogg A, Foster RA, Bienzle D. Comparison of sternal, iliac, and humeral bone marrow aspiration in Beagle dogs. *Vet Clin Pathol*. 2013; 42: 170-176.
14. Delling U, Lindner K, Ribitsch I, Jülke H, Brehm W. Comparison of bone marrow aspiration at the sternum and the tuber coxae in middle-aged horses. *Can J Vet Res*. 2012; 76: 52-56.
15. van Marum RJ, te Velde L. Cardiac tamponade following sternal puncture in two patients. *Neth J Med*. 2001; 59: 39-40.
16. Stifter S, Babarović E, Valković T, Seili-Bekafigo I, Stemberger C, Nacinović A, et al. Combined evaluation of bone marrow aspirate and biopsy is superior in the prognosis of multiple myeloma. *Diagn Pathol*. 2010; 5: 30.
17. Nadav L, Katz BZ, Baron S, Yossipov L, Polliack A, Deutsch V, et al. Diverse niches within multiple myeloma bone marrow aspirates affect plasma cell enumeration. *Br J Haematol*. 2006; 133: 530-532.
18. Goyal S, Singh UR, Rusia U. Comparative evaluation of bone marrow aspirate with trephine biopsy in hematological disorders and determination of optimum trephine length in lymphoma infiltration. *Mediterr J Hematol Infect Dis*. 2014; 6: e2014002.
19. Bartl R, Frisch B, Fateh-Moghadam A, Kettner G, Jaeger K, Sommerfeld W, et al. Histologic classification and staging of multiple myeloma. A retrospective and prospective study of 674 cases. *Am J Clin Pathol*. 1987; 87: 342-355.
20. Chopra A, Anand M, Kumar R, Kalita D, Raina V. Unusual sighting: amyloid deposits in bone marrow aspirate in multiple myeloma. *Indian J Pathol Microbiol*. 2008; 51: 562-563.
21. Mangiacavalli S, Cocito F, Pochintesta L, Pascutto C, Ferretti V, Varettoni M, et al. Monoclonal gammopathy of undetermined significance: a new proposal of workup. *Eur J Haematol*. 2013; 91: 356-360.