SMGroup

SM Journal of Gynecology and Obstetrics

Research Article

# Clinical Application of the Gynecologic Imaging Reporting and Data System (Gi-Rads) for the Evaluation of Adnexal Masses

**Orozco Fernández R[1,2]*, Peces Rama A[1], Llanos Llanos MC[1], Martínez Mendoza A[1], Machado Linde F[1] and Nieto Díaz A[1]**

[1]*Hospital Clínico Universitario Virgen de la Arrixaca de Murcia*
[2]*HM Hospital Universitario Puerta del Sur*

**Article Information**

Received date: Nov 05, 2015
Accepted date: Nov 11, 2015
Published date: Nov 26, 2015

***Corresponding author(s)**

Orozco Fernández R, Hospital Clínico Universitario Virgen de la Arrixaca de Murcia, Spain, Email: rof1986@gmail.com



## Abstract

**Introduction:** Transvaginal ultrasound is the main reference technique in the evaluation of adnexal masses. Based on the Breast Imaging Reporting and Data System (BIRADS) classification Amor et al. suggested adapting this system to gynecologic ultrasound for the evaluation of adnexal masses: Gynecologic Imaging Reporting and Data System (GI-RADS) and based on recognition patterns and criteria recommended by the IOTA group.

**Materials and methods:** A retrospective observational study was performed on women with adnexal masses who were diagnosed and operated consecutively at the Virgen de la Arrixaca Clinical University Hospital in Murcia between January 2013 and December 2014. All patients underwent transvaginal or transrectal ultrasound. GI-RADS1 was not included (no mass). GI-RADS2 and 3 lesions were classified as benign and GI-RADS4 and 5 as probably malignant.

**Results:** 387 patients, mean age 43 (13- 88), 246 premenopausal (63.5%) and 142 postmenopausal (36.5%).387 masses were classified: 3 GI-RADS2 (0.7%), 316 GI-RADS3 (811.7%), 20 GI-RADS4 (5.1%) and 48 GI-RADS5 (12.4%). GI-RADS2, none was malignant. GI-RADS3, 3.1% were malignant. GI-RADS4, 60% were malignant and GI-RADS5, 91.7% were positive for malignancy. Sensitivity 84.9% (95%CI 74.3–91.6%), Specificity 96.3% (95%CI 93.6-97.9%); LR+ 22.7 (CI95% 12.9–39.9), LR- 0.2 (95%CI 0.1-0.3); Odds Ratio 144.2 (95%CI 59.4 – 349.8). Area under the ROC curve 0.90.

**Conclusion:** The GI-RADS reporting system has proved to perform well as a diagnostic system and it seems to be useful in everyday clinical practice. However, it would be advisable to check the classification criteria for GI-RADS 3 and 4 in order to achieve greater diagnostic reliability.

## Introduction

Transvaginal ultrasound is the main reference technique in the evaluation of adnexal masses. When it is performed by expert examiners, subjective impressions are associated with a high sensitivity and specificity in the identification of malignancy, which is extremely useful for surgical approaches [1-3].

However, there are not always expert examiners available for the evaluation of adnexal masses. Therefore, many systems such as simple descriptors [4], mathematical models [5] and linear regression models [6] have been described.

Based on the Breast Imaging Reporting and Data System (BIRADS) classification developed by the American College of Radiology in 1993, that classifies breast lesions effectively according to the level of suspicion for malignancy [7,8], in 2009 Amor et al. suggested adapting this system to gynecologic ultrasound for the evaluation of adnexal masses, also known worldwide as Gynecologic Imaging Reporting and Data System (GI-RADS) and based on recognition patterns and criteria recommended by the International Ovarian Tumor Analysis (IOTA) [9].

## Materials and methods

A retrospective observational study was performed on 387 women who were diagnosed and operated consecutively at the Virgen de la Arrixaca Clinical University Hospital in Murcia (HCUVA) between January 2013 and December 2014.

All patients were chosen at the Gynecology Ultrasound Unit and underwent transvaginal or transrectal ultrasound in the event of the patient's inability or refusal to undergo a first approach, using General Electric Voluson E8 ultrasound machine. The ultrasound examinations were carried out by two ultrasound expert physicians and sonographers (M.C.L.L., A.M.M.) and two medical residents (R.O.F., A.P.R.) under the supervision of the above physicians, following the recognition patterns and applying the GI-RADS system afterwards.

Table 1. **GI-RADS classification system for adnexal masses [11].**

| GI-RADS grade | Diagnosis | Est. prob. malignancy | Detail |
|---|---|---|---|
| 1 | Definitive benign | 0% | Normal ovaries identified and no adnexal mass seen |
| 2 | Very probably benign | < 1% | Adnexal lesions thought to be of functional origin, e.g. follicles, corpora lutea, hemorrhagic cysts |
| 3 | Probably benign | 1–4% | Neoplastic adnexal lesions thought to be benign, such as endometrioma, teratoma, simple cyst, hydrosalpinx, paraovarian cyst, peritoneal pseudocyst, pedunculated myoma, or findings suggestive of pelvic inflammatory disease |
| 4 | Probably malignant | 5–20% | Any adnexal lesion not included in GI-RADS 1–3 and with one or two findings suggestive of malignancy* |
| 5 | Very probably malignant | > 20% | Adnexal masses with three or more findings suggestive of malignancy* |

* Thick papillary projections, thick septa, solid areas with/without ascites, defined according to the International Ovarian Tumor Analysis criteria[11], and vascularization within solid areas, papillary projections or central area of a solid tumor on Color or Power Doppler assessment [6]

The GI-RADS reporting system includes five grades (table 1).

Lesions classified as GI-RADS 1 lesions were not included as most of them were not operated on. GI-RADS 2 and 3 lesions were classified as benign and GI-RADS 4 and 5 lesions were probably malignant (positive on ultrasound).

The gold standard that confirmed them were the histological results provided by the Anatomical Pathology Services, following the criteria of the World Health Organization (WHO) [12], and malignant tumors were staged according to the criteria of the International Federation of Gynecology and Obstetrics (FIGO) [13]. Tumors of borderline histology were classified as malignant tumors.

The statistical data analysis was performed with IBM SPSS Statistics 22.

A descriptive analysis of the lesions was performed together with sensitivity, specificity, Odds Ratio and ROC curve analysis, and the analysis of surgeries and age groups to test if GI-RADS system is applicable as a report method for clinical decision-making in adnexal masses.

## Results

A total of 387 patients with adnexal masses were entered into the study. All patients were referred to the HCUVA Ultrasound Unit, the mean age being 43 years (age range between 13 and 88 years), of which 246 were premenopausal (63.5%) and 141 postmenopausal women (36.5%).

The prevalence of malignant tumors was 16.8%, the mean presentation age for malignant lesions being 52.06 years.

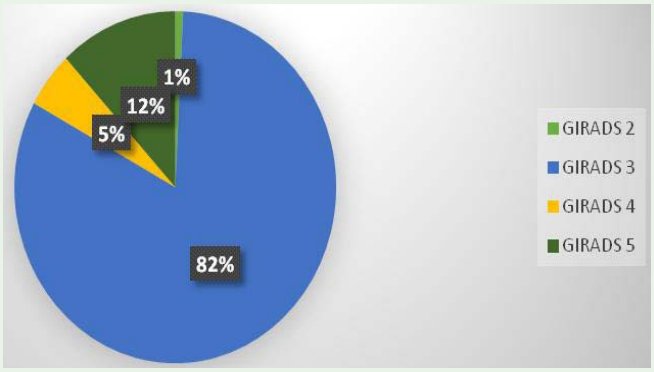


**Figure 1:** Chart showing the distribution of adnexal masses assessed according to GI-RADS criteria.

Regarding the surgical techniques applied, 44.7% underwent laparotomy and 55.3% a laparoscopy. 9.5% of the malignant adnexal masses were managed laparoscopically.

Of the 387 adnexal masses assessed, 3 (0.7%) were classified as GI-RADS 2, 316 (81.7%) as GI-RADS 3, 20 (5.1%) as GI-RADS 4 and 48 (12.4%) as GI-RADS 5 (Figure 1).

Of the GI-RADS 2, none was malignant.

Of the 316 cases classified as GI-RADS 3, 3.1% were malignant [10] or classified false-negative in our study and represented 2.5% of the whole sample.

Of the GI-RADS 4, 60% were malignant; and of the GI-RADS 5, 91.7% of the cases were positive for malignancy. (table 2).

The overall sensitivity of the technique for diagnosis of malignancy was 84.9% (CI 95% 74.3 – 91.6 %) and specificity was 96.3% (CI 95% 93.6 – 97.9%); LR+ 22.7 (12.9 – 39.9), LR- 0.2 (0.1-0.3); and diagnostic Odds Ratio of 144.2 (59.4 – 349.8).

The ROC curve analysis obtained at the end of the study showed an area under the curve value of 0.90. (Figure 2)

Finally, the results of the histological study showed that endometrioma, being the most common lesion, was found in 24.5% of the total cases. Of the histologically malignant lesions, the most frequent lesion found was the Primary Ovarian Carcinoma. (Table 3).

## Discussion

The diagnosis and correct classification of adnexal masses are one of the most important issues in everyday gynecological practice. It seems to be obvious that the ultrasound evaluation of these masses has to be the first diagnostic test to be performed for an accurate classification [1-3].

Table 2. **GI-RADS classification according to the Anatomical Pathology diagnosis.**

| | | Pathology | | Total |
|---|---|---|---|---|
| | | benign | malignant | |
| GI-RADS | GI-RADS 2 | 3 | 0 | 3 |
| | GI-RADS 3 | 306 | 10 | 316 |
| | GI-RADS 4 | 8 | 12 | 20 |
| | GI-RADS 5 | 4 | 44 | 48 |
| Total | | 321 | 66 | 387 |

The overall sensitivity of the technique for diagnosis of malignancy was 84.9% (CI 95% 74.3 – 91.6 %) and specificity was 96.3% (CI 95% 93.6 – 97.9%); LR+ 22.7 (12.9 – 39.9), LR- 0.2 (0.1-0.3); and diagnostic Odds Ratio of 144.2 (59.4 – 349.8).

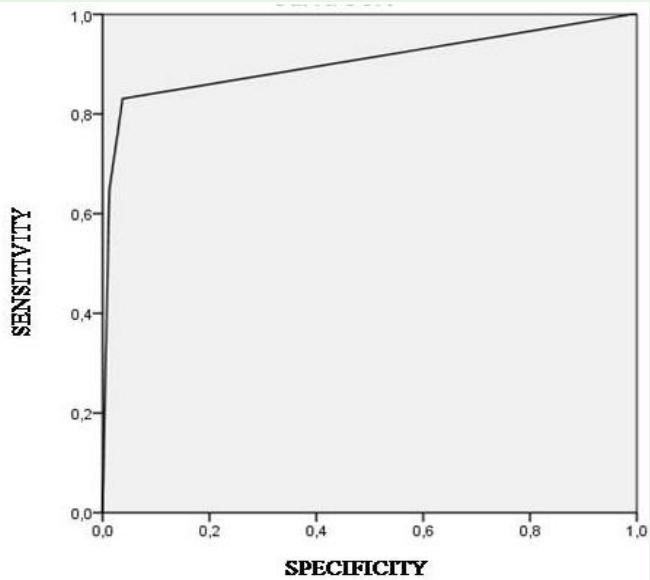


**Figure 2:** ROC curve for sensitivity and specificity of ultrasound diagnosis of malignant adnexal masses.

Ultrasound reports have to show clear and detailed information in order to avoid any misunderstanding [14]. Therefore, multiple systems have been developed to score and classify adnexal masses in order to avoid these errors and standardize diagnostic criteria [15-17]. Inappropriate reporting may cause anxiety in the patient and lead to unnecessary additional tests or surgery [18]. For this reason, Amore et al. suggested using a new reporting system to classify adnexal masses, also known as GI-RADS and based on the internationally accepted BIRADS for classifying breast lesions [9].

In the present study, sensitivity for predicting malignancy was 84.3% and specificity was 96.3%.The lack of higher sensitivity figures reported could be due to the complexity of some of the masses assessed. This is the reason why 12 false-positive and 10 false-negative cases were reported in our population. However, there may be a risk of selection bias, due to the high prevalence of malignant lesions found (16.8%), especially considering that consecutive sampling was performed on patients referred to the Ultrasound Unit for subjective evaluation by an expert after an inconclusive diagnosis.

Among the false positives, most of them showing patterns mentioned by Alcázar, et al. in an article published in 2012 about specific diagnostic performance [19], there was a Pelvic Inflammatory Disease (PID) that was originally considered borderline; two ovarian fibromas diagnosed as borderline tumors; two mucinous cystadenomas with important vascularization considered primary carcinomas; and three serous cystadenomas, two hyalinized myomas, an endometrioma and a hydrosalpinx were originally thought to be borderline.

Among the false negatives, an article written by Moszynski, et al. confirms that subjective ultrasound evaluation of adnexal masses has a high specificity [20]. However, among those considered benign tumors, some malignant tumors can still be found especially within the unexpected population, as for example in premenopausal patients [21]. In our sample, 10 false negatives were found as follows: a granulosa cell tumor diagnosed as a tubo-ovarian abscess, a Leydig cell tumor thought to be a fibroma; an endometrioid carcinoma diagnosed as a suspected benign tumor; a primary ovarian carcinoma suspected to be an ovarian torsion; a dysgerminoma diagnosed as a suspected benign tumor; two primary ovarian carcinomas diagnosed as suspected benign tumors; another primary ovarian carcinoma classified as a myoma; and two borderline tumors considered mucinous tumors.

Table 3. **Anatomical Pathology diagnosis according to the GI-RADS classification.**

| Diagnosis | GI-RADS | | | | Total | Percentage |
|---|---|---|---|---|---|---|
| | GI-RADS 2 | GI-RADS 3 | GI-RADS 4 | GI-RADS 5 | | |
| Borderline | 0 | 4 | 6 | 3 | 13 | 3.3% |
| Metastatic carcinoma | 0 | 0 | 0 | 2 | 2 | 0.5% |
| Primary carcinoma | 0 | 6 | 6 | 38 | 50 | 12.8% |
| Fallopian tube carcinoma | 0 | 0 | 0 | 1 | 1 | 0.2% |
| Cystadenoma | 0 | 87 | 2 | 2 | 91 | 23.5% |
| PID | 0 | 2 | 1 | 0 | 3 | 0.7% |
| Endometrioma | 0 | 94 | 1 | 0 | 95 | 24.5% |
| Fibroma | 0 | 25 | 2 | 1 | 28 | 7.1% |
| Hydrosalpinx | 0 | 3 | 1 | 0 | 4 | 1% |
| Myoma | 0 | 2 | 1 | 1 | 4 | 1% |
| Functional cyst | 2 | 0 | 0 | 0 | 2 | 0.5% |
| Hemorrhagic cyst | 1 | 0 | 0 | 0 | 1 | 1% |
| Paraovarian cyst | 0 | 5 | 0 | 0 | 5 | 1.2% |
| Teratoma | 0 | 88 | 0 | 0 | 88 | 22.7% |
| Total | 3 | 316 | 20 | 48 | 387 | 100% |

The results achieved in our study confirm previous literature. Thus, in 2009 Amor, et al. published an article in which they described the GI-RADS classification, a prospective study of 187 adnexal masses where the prevalence of malignant tumors was 13.4%, reaching a sensitivity of 92% and a specificity of 97% [9].

Later in 2011, the same team published a new multicentric prospective study of 432 adnexal masses assessed with ultrasound according to the GI-RADS classification, which resulted in a sensitivity of 99.1% and 85.9% [11].

In a recent study performed by Rams, et al. in 2015, 98 adnexal masses were assessed using the GI-RADS reporting system, which revealed the best results with a sensitivity of 100% and a specificity of 89.2%.

In our study, the main difficulty encountered when identifying malignant lesions in order to reduce false negatives may have been due to the uncommon histology of some tumors.

The hospital where the study has been performed (HCUVA), is a tertiary referral center with a specific Gynecology Oncology division (an "Oncology Centre" as it was defined by the IOTA Consortium [22] and specifics units where patients with persistent adnexal masses are followed. This could explain the high prevalence of GI-RADS 3 tumors (84.12%), so this can also be an important factor involved on reduce the clinical significance of the study.

Gynecologic Imaging Reporting and Data System (GI-RADS) is one more of the multiple methods being developing to improve an accurate adnexal masses study and diagnosis. Different studies as the Prostate, Lung, Colorectal and Ovarian (PLCO) Cancer Screening Trial is a large population-based randomized trial designed and sponsored by the National Cancer Institute (NCI) in the United States to determine the effects of screening on cancer-related mortality

and secondary endpoints [23]. PLCO trial has shown us screening difficulties with current techniques [24]. Others like IOTA group studies in Europe give us valuable tools in this field. IOTA group ADNEX model can be an useful tool for predict if the adnexal mass is a benign or malign one [22] which seems to perform similar to, or even slightly better than, both LR2 (AUC 0.92) and simple rules previous models [25].

## Conclusion

GI-RADS reporting system has proved to perform well as a report system and ultrasound evaluation of adnexal masses, and it seems to be useful in everyday clinical practice as well as for clinical decision-making. However, it would be advisable to check the classification criteria for GI-RADS 3 and 4 in order to achieve greater diagnostic reliability.

Data given in our study series enhance previous literature.

## References


1. Berlanda N, Ferrari MM, Mezzopane R, Boero V, Grijuela B, Ferrazzi E, et al. Impact of a multiparameter, ultrasound-based triage on surgical management of adnexal masses. Ultrasound Obstet Gynecol. 2002; 20: 181-185.
2. Guerriero S, Ajossa S, Garau N, Piras B, Paoletti AM, Melis GB. Ultrasonography and color Doppler-based triage for adnexal masses to provide the most appropriate surgical approach. Am J Obstet Gynecol. 2005; 192: 401- 406.
3. Alcázar JL, Royo P, Jurado M, Minquez JA, Garcia-Manero M, Laparte C, et al. Triage for surgical management of ovarian tumors in asymptomatic women: assessment of an ultrasound-based scoring system. Ultrasound Obstet Gynecol. 2008; 32: 220-225.
4. Granberg S, Wikland M, Jansson I. Macroscopic characterization of ovarian tumors and the relation to the histological diagnosis: criteria to be used for ultrasound evaluation. Gynecol Oncol. 1989; 35: 139-144.
5. Alcázar JL, Mercé LT, Laparte C, Jurado M, López-García G. A new scoring system to differentiate benign from malignant. Am J Obstet Gynecol. 2003; 188: 685-692.
6. Alcázar JL, Errasti T, Laparte C, Jurado M, López-García G. Assessment of a new logistic model in the preoperative evaluation of adnexalmasses. J Ultrasound Med. 2001; 20: 841- 848.
7. D'Orsi CJ, Kopans DB. Mammographic feature analysis. Semin Roentgenol. 1993; 28: 204-230.
8. American College of Radiology. BI-RADS: ultrasound. In: Breast Imaging Reporting and Data System: BI-RADS Atlas. 4th ed. Reston, VA: American College of Radiology; 2003.
9. Amor F, Vaccaro H, Alcázar JL, León M, Craig JM, Martínez J. Gynecologic imaging reporting and data system: A new proposal for classifying adnexal masses on the basis of sonographic findings. J Ultrasound Med. 2009; 28: 285-291.
10. Timmerman D, Valentin L, Bourne TH, Collins WP, Verrelst H, Vergote I. Terms, definitions and measurements to describe sonographic features of adnexal tumors: A consensus opinion from the International Ovarian Tumor Analysis (IOTA) Group. Ultrasound Obstet Gynecol. 2000; 16; 505.
11. Amor F, Alcázar JL, Vaccaro H, León M, Iturra A. GI-RADS reporting system for ultrasound evaluation of adnexal masses in clinical practice: A prospective multicenter study. Ultrasound in Obstetrics and Gynecology. 2011; 38: 450-455.
12. Scully RE, Sobin LH. WHO histological classification of ovarian tumors. World Health Organization: Geneva, 1999.
13. Heintz AP, Odicino F, Maisonneuve P, Quinn MA, Benedet JL, Creasman WT, et al. Carcinoma of the ovary. FIGO 6th Annual Report on the Results of Treatment in Gynecological Cancer. Int J Gynaecol Obstet. 2006; 95: S161-S192.
14. Timor-Tritsch IE, Goldstein SR. The complexity of a "complex mass" and the simplicity of a "simple cyst." J Ultrasound Med. 2005; 24: 255-258.
15. Jacobs I, Oram D, Fairbanks J, Turner J, Frost C, Grudzinskas JG. A risk of malignancy index incorporating CA 125, ultrasound and menopausal status for the accurate preoperative diagnosis of ovarian cancer. Br J Obstet Gynaecol. 1990; 97: 922-929.
16. Sassone AM, Timor-Tritsch IE, Artner A, Westhoff C, Warren WB. Transvaginal sonographic characterization of ovarian disease: evaluation of a new scoring system to predict ovarian malignancy. Obstet Gynecol. 1991; 78: 70-76.
17. DePriest PD, Shenson D, Fried A, Hunter JE, Andrews SJ, Gallion HH, et al. A morphology index based on sonographic findings in ovarian cancer. Gynecol Oncol. 1993; 51: 7-11.
18. Brown DL, Dudiak KM, Laing FC. Adnexal masses: US characterization and reporting. Radiology. 2010; 254: 342-354.
19. Alcázar JL, Auba M, Ruiz-Zambrana A, Olartecoechea B, Diaz D, Hidalgo JJ, et al. Ultrasound assessment in adnexal masses: An update. Expert Rev Obstet Gynecol. 2012; 7: 441- 449.
20. Moszynski R, Zywica P, Wojtowicz A, Szubert S, Sajdak S, Stachowiak A, et al. Menopausal status strongly influences the utility of predictive models in differential diagnosis of ovarian tumors: an external validation of selected diagnostic tools. Ginekol Pol. 2014; 85: 892-899.
21. Moszynski R, Szpurek D, Szubert S, Sajdak S. Analysis of false negative results of subjective ultrasonography assessment of adnexal masses. Ginekol Pol. 2013; 84: 102-107.
22. Van Calster B, Van Hoorde K, Valentin L, Testa AC, Fischerova D, Van Holsbeke C, et al. Evaluating the risk of ovarian cancer before surgery using the ADNEX model to differentiate between benign, borderline, early and advanced stage invasive, and secondary metastatic tumours: prospective multicentre diagnostic study. BMJ. 2014; 349: g5920.
23. Prorok PC, Andriole GL, Bresalier RS, Buys SS, Chia D, Crawford ED, et al. Design of the Prostate, Lung, Colorectal and Ovarian (PLCO) Cancer Screening Trial. Control Clin Trials. 2000; 21: 273S – 309S.
24. Buys SS, Partridge E, Black A, Johnson CC, Lamerato L, Isaacs C, et al. Effect of screening on ovarian cancer mortality: The prostate, lung, colorectal and ovarian (PLCO) cancer screening randomized controlled trial. JAMA. 2011; 305: 2295–2303.
25. Testa A, Kaijser J, Wynants L, Fischerova D, Van Holsbeke C, Franchi D, et al. Strategies to diagnose ovarian cancer: new evidence from phase 3 of the multicentre international IOTA study. Br J Cancer. 2014; 111: 680-688.