

Robotic Bilateral Transabdominal
Adrenalectomy in Obese PatientsZuliang Feng^{1*}, David P Feng², Jessica W Levine¹ and Carmen C Solorzano³¹Department of Perioperative Services, Vanderbilt University Medical Center, USA²Department of Biology, Belmont University, USA³Division of Surgical Oncology and Endocrine Surgery, Vanderbilt University Medical Center, USA

Article Information

Received date: Jul 31, 2017

Accepted date: Aug 10, 2017

Published date: Aug 19, 2017

*Corresponding author

Zuliang Feng, Department of
Perioperative Services, Vanderbilt
University Medical Center, Nashville,
TN, USA, Tel: 615-403-1508;
Email: zuliang.feng@vanderbilt.edu

Distributed under Creative Commons
CC-BY 4.0

Keywords Da Vinci Robotic System;
Cushing's Disease; Transabdominal
Bilateral Adrenalectomy; Morbidly Obese;
Super Obese; Minimally Invasive

Abbreviations RBTA: Robotic Bilateral
Transabdominal Adrenalectomy; BMI:
Body Mass Index; SO: Severely Obese;
MO: Morbidly Obese; OT: Operation
Time; RA: Robotic Adrenalectomy; LA:
Laparoscopic Adrenalectomy

Abstract

Introduction: Central obesity is a side effect of Cushing's disease. Patients with pituitary-based tumors who have failed other surgical and medical treatments often face the option of bilateral end organ (adrenalectomy) removal.

Methods: In the past two years, four obese patients underwent robotic bilateral transabdominal adrenalectomy (RBTA) at our institution. One patient was obese (body mass index (BMI) 30.6 kg/m²), another was severely obese (BMI 37 kg/m²), another morbidly obese (BMI 40.4 kg/m²) and one was super-obese (BMI 53.2 kg/m²).

Results: The operative times for the super obese, morbidly obese, severely obese and obese patients were 350, 310, 202 and 165 minutes, respectively. Removal of the left adrenal gland took longer (average 133 minutes) than right side (average 90 minutes). Blood loss was minimal (<25 ml). There was a minor liver laceration in the super obese patient. No other complications were observed at a median follow-up of 10 months. The obese and severely obese patients were discharged post-op day 1 and 2; the morbidly and super obese patients were discharged post-op day 4.

Conclusion: Despite the higher anesthetic risks, difficulties with positioning, thick abdominal walls and limited working space in obese patients, RBTA is a safe and effective method to remove the adrenal glands allowing this subset of patients the opportunity to undergo minimally invasive surgery.

Introduction

Obesity is a significant problem in the United States, proving to effect the quality of life of many individuals. Currently, the BMI classifications are: obese (BMI > 30 kg/m²), severely obese (SO) (BMI > 35 kg/m²), morbidly obese (MO) (BMI > 40 kg/m²) and super obese (BMI > 50 kg/m²).

Cushing's syndrome is a rare condition resulting from excess cortisol production. The signs and symptoms of Cushing's syndrome include "moon facies", plethora, central obesity, increased blood pressure, thinning fragile skin and purple striae. The most common cause of Cushing's syndrome is an ACTH producing pituitary adenoma. When other surgical or medical treatments have proved unsuccessful in controlling pituitary-based Cushing's, a bilateral adrenalectomy is an option [1,2].

Worldwide, transabdominal laparoscopic or posterior retroperitoneoscopic are two of the more common approaches to adrenal removal [3]. The transabdominal approach is commonly used to perform bilateral transabdominal adrenalectomy [4,5] but the main disadvantage to this method, particularly in obese patients, is the need to reposition the patient for the contralateral side. Previous studies showed that the retroperitoneoscopic approach is safe and feasible for patients with prior extensive abdominal surgery [6] and for bilateral adrenalectomy [7,8,9]. The retroperitoneoscopic approach circumvents the need for repositioning [7] but the disadvantage for this technique is that it requires the prone position. Morbidly or super obese patients have multiple comorbid conditions including respiratory conditions that limit their ability to tolerate the prone or jack-knife positions or the increased CO₂ insufflation pressures that are required for such approach. Furthermore, all patients with Cushing's syndrome have extensive retroperitoneal fat and the posterior approach is made more difficult by such disadvantageous morphometric characteristics [7,10].

Patients

Between July 2015 and April 2017, four patients (75% female) with refractory Cushing's disease underwent RBTA. Their BMIs are listed in Table 1. One patient had intestinal malrotation.

Surgical Procedure

All procedures started on the right side. The authors believe that the left side is surgically more challenging than the right and prefer to start with the side that will be easier. Figure 1 shows the typical appearance of a super obese patient with Cushing's syndrome prior to positioning. Patients are placed in left lateral decubitus and the abdomen is prepped and draped. The Optiview technique

Table 1: Demographics and Operative Characteristics.

No	sex	Age	BMI(kg/m ²)	OR Time (mins)	Console Time (mins)	Re-osition Time (mins)	G land Size (L/R)(cm)	G land Weight (L/R)(cm)	length of Hospital Stay (days)
1	F	29	30.6	165	114	20	7.2/6.5	16.1/12.3	1
2	F	26	37.0	202	150	21	7.9/7.1	22.9/25.8	2
3	M	60	0.4	310	261	30	6.5/6	76/26	4
4	F	43	53.2	350	300	35	7.0/5.0	114.5/44.7	4

with a 10/12mm trocar is used to enter the abdomen in the subcostal area at or around the mid-clavicular line and approximately 5 cm away from the costal margin (camera position). Two 8 mm robotic trocars were placed and triangulated with the camera port (1 medial sub-xiphoid and 1 lateral subcostal) as displayed in Figure 2. Two additional 5mm assistant ports, one medially and above the right robotic arm and one periumbilical, were also placed (in one case these two ports were re-used for work on the contralateral side). After trocar placement, the robot was docked (Intuitive Surgical, Sunnyvale, CA, USA) (Figure 3). The 8 mm robotic Cardiere forceps were used utilized in the left robotic arm and the robotic cautery hook in the right arm. With the 30-degree camera with the angle of the scope peering downward, the procedure began by mobilizing the liver, taking down the triangular ligament and opening the peritoneal reflection and retroperitoneum. Dissection started laterally, moved superiorly, and then proceeded medially identifying the adrenal gland. The plane between the adrenal gland and the vena cava was carefully dissected and revealed the right adrenal vein. The right adrenal vein was circled with the robotic hook, clipped with 5mm “green” Hem-o-lok clips (Teleflex Medical, Morrisville, NC, USA) and divided by the first assistant through the 5mm periumbilical port. After the right adrenal gland was removed from the retroperitoneum, it was placed into an Endopouch Retriever (Ethicon Endo-surgery, Cincinnati, OH, USA) and the pouch string was exteriorized through the subxiphoid assistant port and secured to the skin (and later removed after completion of the contralateral side). In one patient, the subxiphoid and periumbilical assistant ports were temporary closed with staples and covered for sterility and used subsequently for the left adrenalectomy.

The patient was repositioned in right decubitus with the left side up. The left adrenalectomy began by entering the abdomen using the Optiview technique and we triangulated two robotic 8 mm ports and the 2 assistant port sites were added as explained above. The splenic flexure of the colon was mobilized and the kidney and

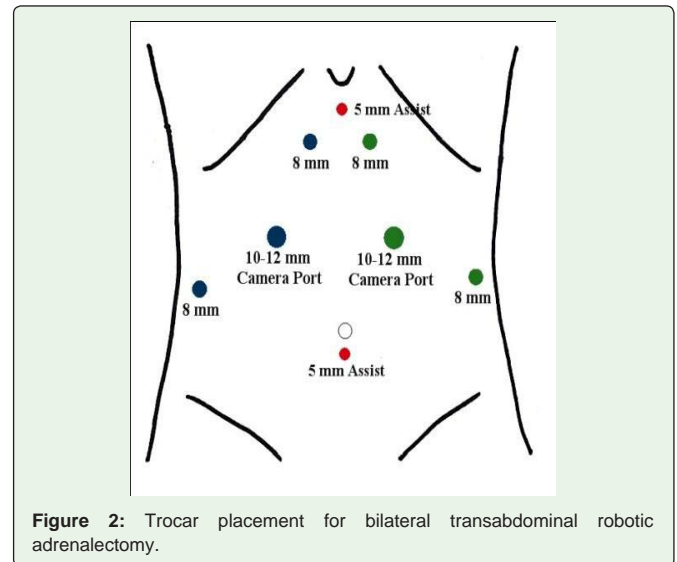


Figure 2: Trocar placement for bilateral transabdominal robotic adrenalectomy.

retroperitoneum exposed. The attachments between the spleen and the kidney were dissected and the spleen and pancreas were medialized. The adrenal tissue was identified and further separated from the pancreas superiorly, continuing the dissection medially and inferiorly until the adrenal vein was found. The adrenal vein was encircled, clipped and divided in the same fashion as explained above for the right side. The adrenal gland was then separated with a rim of surrounding fat of the retroperitoneum and placed in an Endopouch. Both bags were then removed through the camera port incision. After that, all CO2 was evacuated and the remaining port sites closed. All patients were extubated successfully prior to transferring to the post-anesthesia care unit. Intensive care was not necessary following these procedures.

Results

All four patients underwent RBTA. Table 1 shows the total operative and console times. Operative times and console times increased as the BMI increased. The gland sizes were measured as follows (left/right): patient #1, 7.2/6.5 cm; patient #2, 7.9/7.1 cm; patient #3, 6.5/6.0; and 7.0/5.0 cm for patient #4. The gland weights were (left/right): 16.1/12.3 grams for patient #1, 22.9/25.8 grams for patient #2, 76/26 grams for patient #3, and 114.5/44.7 grams for patient #4. Blood loss in all patients was minimal. The super-obese patient suffered a small liver laceration due to a large and difficult to retract fatty liver. The laceration was controlled with pressure and a Surgicel Nu-Knit hemostatic sheet. There were no other complications. Length of hospital stay per patient is listed in Table 1. At a mean follow up of 10 months all patients have been successfully treated.

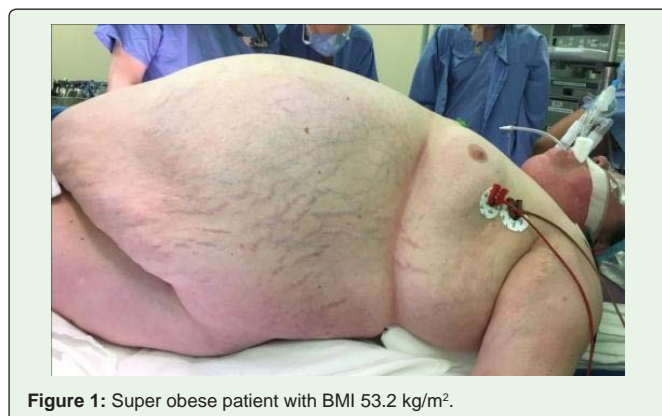

Figure 1: Super obese patient with BMI 53.2 kg/m².



Figure 3: Robotic docking and trocar placement for transabdominal adrenalectomy in a super obese patient.

Discussion

Previous studies have described the difficulties of laparoscopic and robotic-assisted surgical procedures in morbid and super-obese patients [11,12,13]. Obese patients undergoing adrenalectomy have a greater rate of comorbid disease and higher risk of perioperative complications [14]. Recent data suggest that robotic-assisted adrenalectomy has some advantages when compared to straight laparoscopy in select morbid and super obese patients [13,15]. Advantages of the robotic approach in such patients include: high-definition and 3D visualization, the ability to retract more effectively with ergonomic advantage, 360 degree instrument-wrist motion and the ability to reach and visualize tissues in tight spaces [15].

In this study, we demonstrate favorable overall operative times and outcomes in patients undergoing BTRA when compared to the published unilateral adrenalectomy outcomes of non-obese patients (factoring out repositioning time from total operative time and dividing by two). Like others, we found laterality affected operative time. A prior study of non-obese patients showed skin-to-skin operative times for left and right adrenalectomy of 55 and 77 minutes, respectively [16]. Our skin-to-skin average operative time was 133 minutes (left side) and 90 minutes (right side), but for the obese patient with lower BMI of 30.6 kg/m², it was 65 minutes (left side) and 59 minutes (right side). Other studies of robotic adrenalectomy on obese patients found similar operative times to our current study. Brunaud et al [17] reported that their skin-to-skin operative time on the left side to be 103 minutes and 91 mins for the right while Aksoy et al [15] reported 179 minutes (left side) and 194 minutes (right side). In these two latter studies the maximal BMI was 42 kg/m² and 47.1 kg/m².

A recent study by Erbil et al. demonstrated a positive association between BMI and increased postoperative complications, operating times, and hospital stay. The authors suggested that increased intra-abdominal and retroperitoneal fat is responsible for these findings [18]. In the super obese patients the difficulties with intraoperative exposure due to enlarged liver, colon, omentum, and thick abdominal walls lead to decreased ability to identify anatomic landmarks, limited working space, and, hence, prolonged operative times. As expected, the current study demonstrates increasing overall operative,

console, and repositioning times associated with rising BMIs. The retroperitoneal dissection of a relatively normal adrenal gland in a “sea of fat,” a finding that is characteristic of pituitary based Cushing’s disease, can be a challenge to even the most experienced adrenal surgeon. The surgeon cannot and must not leave any adrenal tissue or the cortisol may remain high and the operation will fail. The authors believe that in these difficult morbid and super-obese patients, the robotic approach allows for successful en-block wide dissection of the adrenal gland and the surrounding retroperitoneal tissue.

In the current case series, we used a 10/12 cm trocar for the robotic camera, two 5 mm trocars for the assistant and two regular robotic 8mm trocars in all patients except for the super obese patient. For this patient, we used extra-long trocars. In the past, we have had problems with short ports becoming dislodged. We have since solved the problem by using the extra-long trocars in all super obese patients.

Previous reports have shown that perioperative outcomes were similar between laparoscopic and robotic adrenalectomy in obese patients [15,17]. Aksoy et al (15) reported mean operative times of 186.1 minutes in Robotic Adrenalectomy (RA) group and 187.3 minutes in the Laparoscopic Adrenalectomy (LA) group, hospital stay was 1-3 days (RA) and 1-5 days (LA) (maximum BMI of 47.1). In their robotic series, Brunaud et al. [17] reported mean operative times of 104 minutes in RA and 87 minutes in LA (maximum BMI of 42) with average hospital stay of 6.3 days in RA and 6.7 days in LA. The current study demonstrates that operation time, intra-operative complications and post-operative hospital stay correlates positively with rising BMI. Total console times for RBTA in super (300 minutes) and morbidly obese (265 minutes) patients were significantly longer than in obese (114 minutes) and severely obese patients (150 minutes). Post-operative hospital stay was longer in morbidly and super obese patients. The one minor complication occurred in the super obese patient.

Conclusion

Despite the high anesthetic risks, difficulty of operative positioning, thick abdominal wall and limited working space, the RBTA can be a safe and effective procedure in obese patients. This approach allows completion of a minimally invasive adrenalectomy in this challenging patient population with excellent results.

References

- Nieman L, Cutler GB. Cushing’s syndrome. In: Degroot LJ, Besser M, Burger HG et al, eds. *Endocrinology*. 3rd ed. Philadelphia, PA: WB Saunders; 1995; 1741-1769.
- Newell-Price J. Cushing’s syndrome. *Clin Med*. 2008; 8: 204-208.
- Gumbs AA, Gagner M. Laparoscopic adrenalectomy. *Best Pract Res Clin Endocrinol Metab*. 2006; 20: 483-499.
- Takata MC, Kebebew E, Clark OH, Duh QY. Laparoscopic bilateral adrenalectomy: results for 30 consecutive cases. *Surg Endosc*. 2008; 22: 202-207.
- Walz MK, Alesina PF, Wenger FA, Deligiannis A, Szuczik E, Petersenn S, et al. Posterior retroperitoneoscopic adrenalectomy—results of 560 procedures in 520 patients. *Surgery*. 2006; 140: 943-950.
- Miccoli P, Materazzi G, Brauckhoff M, Ambrosini CE, Miccoli M, Dralle H. No outcome differences between a laparoscopic and retroperitoneoscopic approach in synchronous bilateral adrenal surgery. *World J Surg*. 2011; 35: 2698-2702.

7. Berber E, Mitchell J, Milas M, Siperstein A. Robotic Posterior Retroperitoneal Adrenalectomy: Operative Technique. *Arch Surg*. 2010; 145: 781-784.
8. Dickson PV, Alex GC, Grubbs EG, Jimenez C, Lee JE, Perrier ND. Robotic-Assisted Retroperitoneoscopic Adrenalectomy: Making a Good Procedure Even Better. *The American Surgeon*. 2013; 79: 84-89.
9. Feng Z, Solorzano CC. Bilateral Robotic Transabdominal Adrenalectomy in a patient with known Intestinal Malrotation. *Journal of Robotic Surgery*. 2017.
10. Myśliwiec P, Marek-Safiejko M, Łukaszewicz J, Safiejko K, Kozłowski R, Wojskowitz P, et al. Videoscopic adrenalectomy - when does retroperitoneal seem better? *Videosurgery Miniinv*. 2014; 9: 226-233.
11. Bhatia P, Bindal V, Singh R, Gonzalez-Heredia R, Kalhan S, Khetan M, et al. Robot-Assisted Sleeve Gastrectomy in Morbidly Obese Versus Super Obese Patients. *JLS*. 2014; 18: 1-6.
12. Parikh MS, Shen R, Weiner M, Siegel N, Ren CJ. Laparoscopic bariatric surgery in super-obese patients (BMI>50) is safe and effective: a review of 332 patients. *Obes Surg*. 2005; 15: 858-863.
13. Almeida OD. Robotic Hysterectomy Strategies in the Morbidly Obese Patient. *JLS*. 2013; 17: 418-422.
14. Dancea HC, Obradovic V, Sartorius J, Woll N, Blansfield J. Increased complication rate in obese patients undergoing laparoscopic adrenalectomy. *JLS*. 2012; 16: 45-49.
15. Aksoy E, Taskin HE, Aliyev S, Mitchell J, Siperstein A, Berber E. Robotic versus laparoscopic adrenalectomy in obese patients. *Surg Endosc*. 2013; 27: 1233-1236.
16. Malley D, Boris R, Kaul S, Eun D, Muhletaler F, Rogrs C, et al. Synchronous Bilateral Adrenalectomy for Adrenocorticotrophic-Dependent Cushing's Syndrome. *JLS*. 2008; 12: 198-201.
17. Brunaud L, Bresler L, Ayav A, Zarnegar R, Raphoz AL, Levan T, et al. Robotic-assisted adrenalectomy: what advantages compared to lateral transperitoneal laparoscopic adrenalectomy? *Am J Surg*. 2008; 195: 433-438.
18. Erbil Y, Barbaros U, Sari S, Agcaoglu O, Salmaslioglu A, Ozarmagan S. The effect of retroperitoneal fat mass on surgical outcomes in patients performing laparoscopic adrenalectomy: the effect of fat tissue in adrenalectomy. *Surg Innov*. 2010; 2: 114-119.