

Comprehensive Approach to the  
Treatment of Temporomandibular  
Disorder with Severe Pain SyndromeOlga A Shakhmetova<sup>1\*</sup> and Tatiana MSinitsina<sup>2</sup><sup>1</sup>Sogaz International Medical Center, St. Petersburg, Russia<sup>2</sup>General Practice Dentistry Department North-Western State Medical University (NWMSU) named after I.I. Mechnikov, Kirochnaya Street 41, St. Petersburg, 193015, Russia

## Article Information

Received date: Feb 24, 2017

Accepted date: Apr 21, 2017

Published date: Apr 27, 2017

## \*Corresponding author

Olga A. Shakhmetova, Sogaz International Medical Center, MalayaKoniushennaya 8, Saint Petersburg, 191186, Russia, Tel: +7 800 333 0 888; Email: olga\_shahmetova@mail.ru

Distributed under Creative Commons CC-BY 4.0

Keywords TMD; MRI; Injections of BTX-A; masticatory muscles

Article DOI 10.36876/smmd.1015

## Abstract

The article presents the results of comprehensive approach to the treatment of temporomandibular dysfunction (TMD, which consisted in combination of occlusal therapy and muscle status correction with Botulinum Toxin A (BTX-A) injections or using centrally acting muscle relaxants. The study included 111 patients, 81 women and 30 men aged 18 to 45 years. According to the results of the clinical examination all patients were divided into two groups. The main group (91 patients) included patients with clinical signs of TMD. The control group (20 patients) consisted of patients without clinical signs of dysfunction and without malocclusion. The groups were comparable in sex and age. Patients of the main group were divided into 2 subgroups: in the first sub group the patients received centrally action muscle relaxants (71 people), in the second the patients were treated with BTX-A injections into masticatory muscles (20 people). In both subgroups the treatment included occlusal therapy. All patients were subjected to Magnetic Resonance Imaging (MRI) of the TMJ and masticatory muscles, as well as ultrasonography and surface Electromyography (EMG) of the masticatory muscles before and after treatment. As a result, a significant reduction in the pain syndrome, an improvement in the interrelation of intraarticular TMJ elements and a change in the structure of the masticatory muscles was revealed. The best results were achieved in the group with injections of BTX-A into the masticatory muscles. Electromyographic indexes have approached the values of the norm. The clinical signs of TMD decreased or reduced.

## Introduction

Temporomandibular dysfunction is a symptom complex, often found in the everyday practice of a dentist. Its prevalence among patients who applied for dental care, according to various sources, ranges from 31% to 85% [1,2]. Many publications have been devoted to the methods of diagnosis and treatment of TMD [3].

In the development of TMD occlusal, somatic, psychological and other factors are considered to be the main factors. When considering etiopathogenesis, most authors prefer one leading factor. So Khvatova and Silinin their studies pointed to the occlusal factor as the leading one. Some researchers identify connective tissue diseases as the main etiopathogenetic cause of TMD development [4-10]. In connective tissue dysplasia, the synthesis of enzymes and coenzymes changes, the spatial orientation of collagen and structural proteins is disrupted, which, as a consequence, leads to irreversible changes in the ligament apparatus of the Temporomandibular Joint (TMJ).

Other researchers cite data on the primary role of the psychological factor, which can cause hypertension of the masticatory muscles and is expressed by the pain symptom. Myofascial pain syndrome caused by muscle hypertension affects up to 70% of patients with dysfunction of the TMJ. Moreover, the predominance of women in the sample is associated with their greater emotional lability than men [1].

Literature survey shows that hypertonicity and spasm of the masticatory muscles have multifaceted pathogenetic mechanisms. There are contradictory data on the role of the muscular component in the development of TMD in the literature. Thus, the cause of TMD can be occlusal, psychological, muscular factors, or their combination. The complexity of the therapy for the TMD is that all these causes can aggravate the course of the disease and lead to the emergence of new factors that increase the weight of treatment. In addition, there are difficulties in objectifying the pathology of masticatory muscles, associated with the fact that for their research, the clinical method and surface electromyography are mainly used. To date, there is no single standard in the treatment of hypertension of masticatory muscles and other functional disorders of muscle genesis.

Some authors speak of success in occlusive therapy [11]. Others prefer osteopathic correction [12]. In foreign sources, there is evidence of successful correction of the abnormal state of masticatory muscles in patients with TMD with BTX-A [13].

OPEN ACCESS

ISSN: 2576-5442

In connection with the foregoing, there is a need to develop methods for objective diagnosis of TMD, clarifying the etiopathogenesis of this disease, creating an effective technique for its treatment.

**Materials and Methods**

The study included 111 patients, 81 women and 30 men aged 18 to 45 years. As a result of the clinical examination, all patients were divided into two groups. The main group (91 patients) included patients with clinical signs of TMD. The control group (20 patients) consisted of patients without clinical signs of dysfunction and without malocclusion. The groups were comparable in sex and age.

Methods of clinical examination included: specification of occlusion, measuring the range of mouth opening (in mm), auscultation of the TMJ, and evaluation of the trajectory of the lower jaw (presence or absence of deviation). Patients who complained of pain were separated on three groups:

Mild pain - 1-4\10 point of Visual Analogue Scale (VAS),

Moderate pain - 5-7\10 point of VAS,

Severe pain - 8-10\10 point of VAS.

Pain intensiveness was measuring in palpation of masseter, temporal, lateral and medial pterygoid muscles were performed (Table 1).

All patients of the main and control groups, before and after treatment, underwent magnetic resonance imaging (MRI) of the TMJ and masticatory muscles. The study was performed on a Signa Infinity 1.5T (GE, USA) tomograph from the right and left sides in the sagittal and coronal planes using pulse sequences PD and GE IP in 2 stages in the position of closed and open mouth and parameters: cutting thickness 2 mm, interval 0.2 mm, study time 1 pulse sequence 2.5 min. For a clearer visualization of the lateral, medial pterygoid and masseter muscles in the coronal plane, the scanning zone was enlarged. When analyzing tomograms, the position of the condyle, disc, the presence or absence of effusion in the capsule of the joint was evaluated. The MR images also examined the structure and attachment of the masticatory muscles: the transverse diameter of the abdomen of the muscles, the points of attachment of the muscles, the number of beams, and the intensity of the image were determined.

Surface Electromyography (EMG) of the masticatory muscles was carried out according to the protocol proposed on the basis of the University of Milan, using the portable eight-channel electromyograph Easy Myo (TFR, Italy). The summary biopotential of the four superficial masticatory muscles (m. masseter dexter et sinister, m. temporalis dexter et sinister) was recorded with bipolar disposable electrodes, which were placed in the projection of the middle of the muscle belly, parallel to its fibers with an interelectrode distance of 20 mm.

**Table 1:** Scale of masticatory muscles palpation pain intensity.

Intensity of pain	Points
No pain	0
Mild pain (1-4\10 point of VAS)	1
Moderate pain (5-7\10 point of VAS)	2
Severe pain (8-10\10 point of VAS)	3

After the analog signal was received, a special computer program (DAQ) processed it. The information was displayed in a graphic and digital form.

The following indices were evaluated:

- The POC index is a measure of the symmetry of the muscular activity distribution, in the existing occlusion. The average value of the POC norm is 80-90%.
- The ASIM index is an index of the total activity of the masseter and temporal muscles on one side relative to the total activity of similar muscles on the other. Norm variety is from -10 % to + 10 %.
- The index ATTIV is an indicator of the activity measure m. masseter with respect to m. temporalis on both sides. Norm variety is from -10 % to + 10 %.
- The index TORQ characterizes the diagonal displacement of the lower jaw in one direction or the other with maximum compression of the jaws. Normally this figure should not exceed 10 %.
- Index IMPACT indicates the degree of muscle activation with maximum compression of the jaws with respect to the activation data when squeezed on cotton rolls. Norm variety is equal to 100-120 %.

Ten patients in the main group underwent ultrasonography of masseter. The Philips Cleave 650 (Netherlands) was used with the sensor - V6-2. To evaluate the Young's modulus of elasticity, shear wave elastography was used, which made it possible to quantify the elasticity in different parts of the muscles.

At the first (orthodontic) stage of treatment, patients received a smooth hard splint on the lower jaw. The patients received the prescription to use the splint at night, and also 4 hours in the afternoon during 2 weeks. At the end of this period, the occlusal lining was applied to the splint made of fast-setting plastic, in order to stabilize the lower jaw in a therapeutic position. The therapeutic position was determined based on the TMJ MRI data and corresponded to the anterior symmetrical position of the condyles of the TMJ. The aim was to decompress the TMJ. Wear schedule was 24 hours a day. During the treatment, the occlusal lining was corrected to change the position of the lower jaw. The necessity and frequency of such corrections was determined by the dynamics of clinical data (the decrease or absence of clicks in the TMJ, changes in the range of mouth opening, pain syndrome). At the initial stages of treatment, the interval between visits ranged from two to three weeks. The duration of occlusal splint therapy averaged 5.1 ± 0.32 months.

As a result of treatment, 71.4% of patients had a reduction or complete reduction of clicks in the TMJ. In 95.6% of cases, range of mouth opening increased. Reduction of pain during palpation of masticatory muscles was noted in 9.9% of the study group. At the same time, in 45.09% of cases in patients who did not have palpation pain of m. masseter, and in 41.67% with painless palpation of m. pterygoideus lateralis revealed pain in these muscles in 2 months after the commencement of splint-therapy.

Despite the fact that the TMJ has reliably revealed a decrease in the severity of clinical symptoms, the pain symptom caused by the

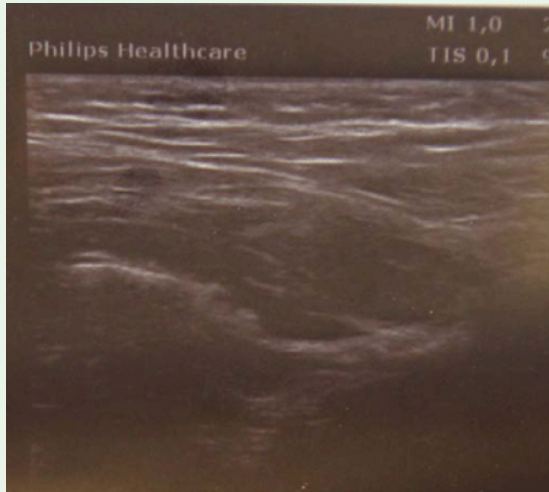

Figure 1: Ultrasonography image of lateral pterygoid muscle.

hypertonicity of the masticatory muscles resulting in the formation of trigger points significantly reduced the quality of life and led to increase the number of complaints. This symptomatology is associated with the previously compensated overload of the muscular complex. As a result of a sharp change in occlusal contacts and passive stretching of the masticatory muscles, the myostatic reflex was triggered and manifested in an increased masticatory muscles tone and led to the collapse of the compensatory mechanism, which determined the transition of latent trigger points to active and, consequently, clinical manifestation of myofascial pain syndrome.

The presence of complaints about periodic headaches (19.78%), migratory pain in the face, neck and TMJ (14.28%), with painless palpation of the TMJ, are apparently connected with this phenomenon.

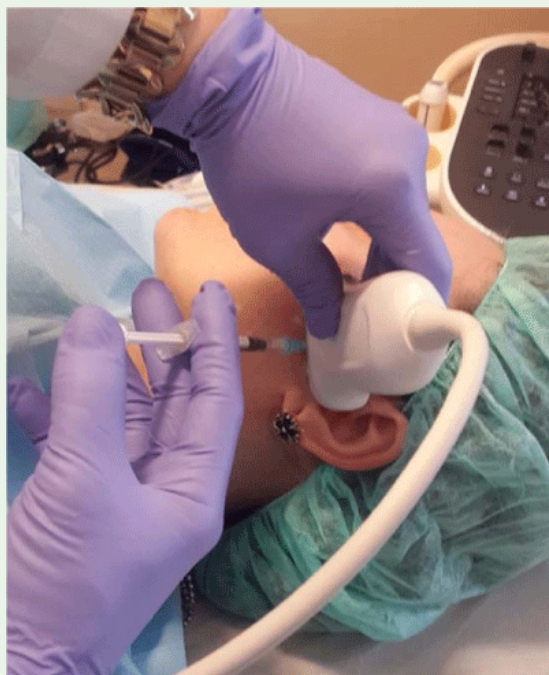

Figure 2: Injection of BTX-A into the lateral pterygoid muscle.

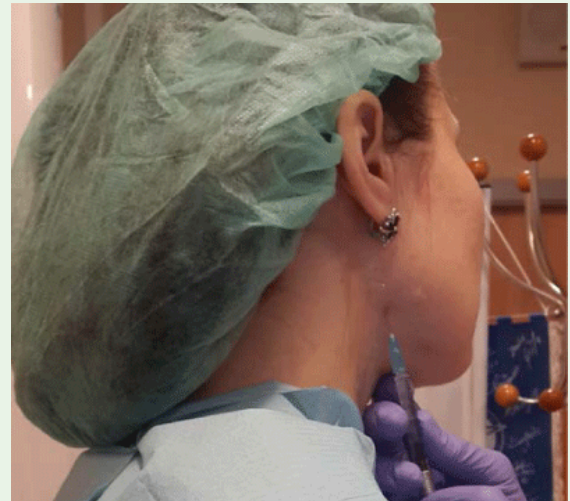

Figure 3: Injection of BTX-A into the lateral pterygoid muscle.

After 6-8 weeks from the splint treatment start, relaxation of the affected muscles was carried out by intramuscular injection of BTX-A under ultrasonography guidance. The target muscles: m. pterygoideus lateralis, m. pterygoideus medialis, m. masseter, m. temporalis. The protocol of manipulation was individual for each patient. The target muscles, the degree of their tension, the intensity of the pain syndrome, the type of movement of the lower jaw, the results of MRI were taken into account. The total BTX-A (incobotulotoxin) dose was 100 units. The dose was selected according to the recommendations of Pictorial Atlas of Botulinum Toxin Injection, Wolfgang Jost, 2008.

Injection of BTX-A in m. pterygoideus lateralis was performed under ultrasonography guidance (Figure 1). The dose of the drug for administration was 15-30 units. The injection point was the point located 3 cm anterior to the tragus along the lower edge of the zygomatic bone (Figure 2). Injection m. pterygoideus medialis needs BTX-A 10-20 units. The needle is inserted in the region of the angle of the mandible, moving it inward parallel to the inner surface of the mandible (Figure 3).

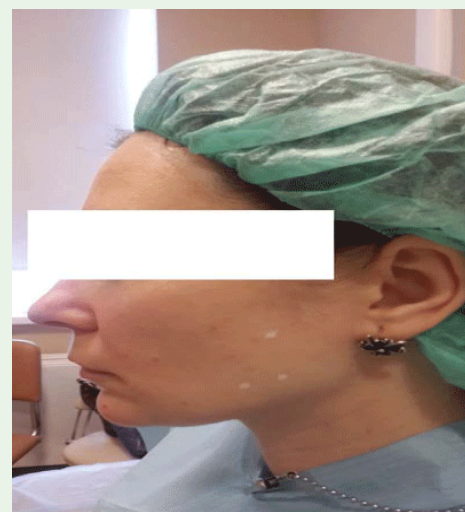

Figure 4: Injection of BTX-A into masseter.



**Table 2:** Electromyographic indices before and after treatment.

Electromyographic indices	Before treatment	After treatment
POC temporalis (%)	70.92±4.03	83.5±0.89
POC masseter (%)	72.44±3.11	84.7±1.83
POC med (%)	71.68±3.16	81.9±1.54
ASIM	4.44±7.05	1.54±2.1
ATTIV (%)	-19.69±6.97	2.7±1.56
TORQ (%)	2.67±4.32	-0.064±1.96
IMPACT (%)	93.29±8.18	118.2±6.18

To select injection points (usually 3 points) of m. masseter, the results of the clinical examination were used. The classical scheme of injections of this muscle was edited according to the location of the trigger points. For the injection of this superficial muscle, guidance was not used. The dose of the drug was 15-20 units (Figure 4).

The BTX-A injection in m. temporalis was carried out basing on clinical data such as painful palpation and hypertrophy. Number of injection points was 1-3. The total dose was 5-15 units.

As side effects, only the appearance of small hematomas at injection sites was noted. Most often (up to 90%), this complication occurs when the temporal muscle is injected. There were no other side effects or complications of therapy. After the completion of splint therapy, the patients underwent orthodontic or prosthetic treatment to fix the achieved result.

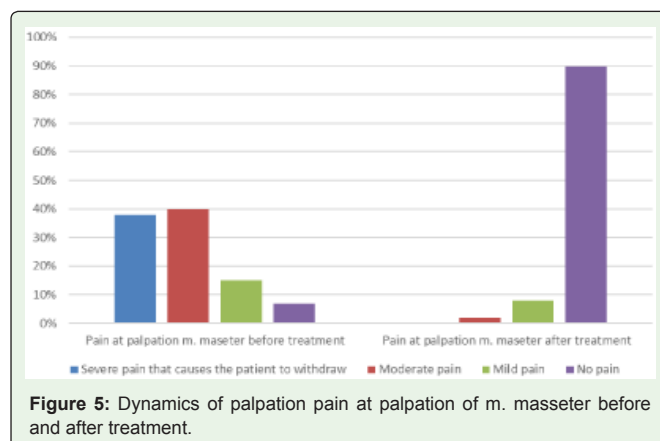
The data was processed using the Statistical for Windows 6.0 program. The arithmetic mean (M) and the mean error of the arithmetic mean (m) were calculated. Student's t-test, X<sup>2</sup> Pearson's criterion, Wilcoxon on rank-based U-test, Gamma criterion, Fisher's exact method, two-sample z-test, one-way analysis of variance, and correlation analysis. The differences were considered to be significant at p < 0.05.

**Results**

The results of comprehensive treatment were evaluated 4-6 months after its onset. The increase in the range of mouth opening

**Table 3:** The number of hypointensive MR sites of various muscles in the main and control groups of patients.

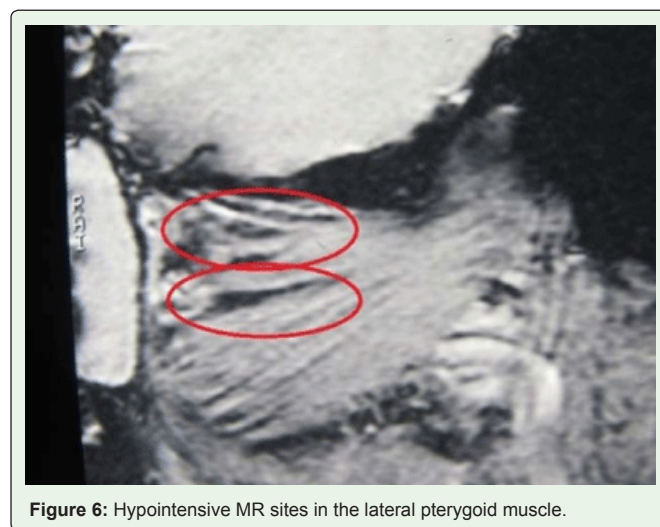
Muscles	The number of hypointensive MR sites	
	Before treatment	After treatment
m. masseter dexter (M±m)	1,85±0,12	0,73±0,28
m. masseter sinister (M±m)	1,89±0,14	0,68±0,23
m. pterygoideuslateralisdexter (lower beam)(M±m)	3,18±0,16	1,28±0,23
m. pterygoideus lateralis sinister (lower beam)(M±m)	3,21±0,17	0,95±0,25
m. pterygoideuslateralisdexter (upper beam)(M±m)	1,26±0,11	0,36±0,18
m. pterygoideus lateralis sinister (upper beam)(M±m)	1,89±0,1	0,32±0,14
m. pterygoideusmedialisdexter (M±m)	2,95±0,16	1,16±0,28
m. pterygoideusmedialis sinister (M±m)	1,87±0,15	1,05±0,28



was noted in 95% of the patients in the group with comprehensive treatment. In 85% there was a decrease in pain symptoms at rest. In 90% of cases, the TMJ clicks reduction was observed. The repeated palpation of the masticatory muscles revealed the decrease in pain intensity (Figure 5). There was also a significant improvement in the standardized electromyographic parameters (at p > 0.05) (Table 2).

Before the treatment the MRI of TMJ revealed multiple (more than 3) hypointensive MR sites in the area of the tendon-muscle junction and in the middle of the muscle belly in all patients (Figure 6). Such sites were localized in m.pterygoideus lateralis et medialis, as well as in m.masseter. Patients with palpation pain of the masticatory muscles in all cases demonstrated the presence of similar sites, the number of which exceeded 3. In 86.81% of cases (for m.masseter) and 75.82% (for m. pterygoideus lateralis) with the detection of hypointense sites with the radiation method, muscle palpation was painful. Statistically significant differences in the number of sites between the main and control groups were found (Table 3).

With an increase in the diameter of the m. masseter belly, the Impact index increases (Gamma = 0, 27). An inverse relationship (p < 0.05) was found between the number of hypo intense MR sites in the masticatory muscles and the value of the Attiv index. The presence of hypo-intensive MR sites in m. masseter leads to a decrease in the standardized m. masseter activation index with respect to m. temporal



**Figure 6:** Hypointensive MR sites in the lateral pterygoid muscle.

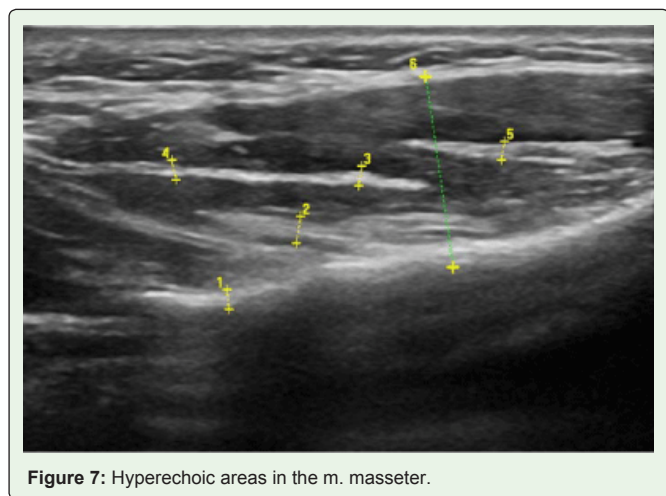

Figure 7: Hyperechoic areas in the m. masseter.

is. This is confirmed by the coefficient of rank correlation between the Impact value and the number of such sites (Gamma = - 0.38). The presence of hypo intense sites in m. masseter reduces the degree of activation of these muscles and is a marker of the pathological process caused by their functional disorders.

To verify the results of MR- and EMG- studies, an ultrasonography study of masseter in 10 patients of the main group was performed. In each case, hyper echoic sites were found to have the similar localization and equal number to the hypo intense sites identified by the MRstudy. When using the elastography method, it was revealed that these areas have a 3-4 times higher density than normal muscle tissue has (Figure 7).

A statistically significant decrease in the number of local seals was revealed after treatment by BTX-A injection (Table 4). When re-measuring the diameter of the m. masseter belly in 45% of cases showed a decrease in its diameter. This phenomenon is associated with the presynaptic blockade of a part of the motor units and, as a result, the reduction of hypertrophy of the muscle fibers. Similar changes in m. pterygoideus lateralis et medialis were not observed.

Table 4: Change in the number of hypointensive MR sites in muscles before and after treatment.

Muscles	The number of hypointensive MR sites	
	Before treatment	After treatment
m. masseter dexter (M±m)	1,85±0,12	0,73±0,28
m. masseter sinister (M±m)	1,89±0,14	0,68±0,23
m. pterygoideuslateralisdexter (lower beam)(M±m)	3,18±0,16	1,28±0,23
m. pterygoideus lateralis sinister (lower beam)(M±m)	3,21±0,17	0,95±0,25
m. pterygoideuslateralisdexter (upper beam)(M±m)	1,26±0,11	0,36±0,18
m. pterygoideus lateralis sinister (upper beam)(M±m)	1,89±0,1	0,32±0,14
m. pterygoideusmedialisdexter (M±m)	2,95±0,16	1,16±0,28
m. pterygoideusmedialis sinister (M±m)	1,87±0,15	1,05±0,28

All subjects had a high level of personal anxiety according to the Spielberger-Hanin scale that was 72.5%.

### Conclusion

1. The results of the study show that the treatment of patients with TMD and severe chronic pain syndrome gives a positive result in an interdisciplinary approach. The interdisciplinary approach includes participation of an orthodontist adjusting occlusion on one hand, and participation of a neurologist addressing the local myofascial pain syndrome and the mechanisms of central sensitization, on the other hand.
2. As a result of the interdisciplinary approach to treatment, there has been a significant improvement in clinical data (reduction of pain syndrome, increase in the volume of active movements in the TMJ, the formation of a mandible close to the physiological pattern, regression of the temporomandibular joint disc displacement, which in turn stops the process of its degeneration), as well as the normalization of standardized electromyographic indicators on the background of therapy.
3. Patients with chronic prosopalgia had a high level of personal and situational anxiety. This fact can be considered as a consequence of chronic pain sensitization, leading to functional disorders of the nervous system, or, as a premorbidity to chronic pain.
4. In the patients with TMD, the masticatory muscles undergo specific morphometric changes with typical presence of hypo intense MR sites, the number of which correlates with the severity of the pain symptomatology. In the ultrasonography study, hyper echoic regions are identified, which number and localization is similar to hypo intense MR sites. Their density is 5-6 times higher than those of the surrounding muscle tissue. These areas are hypertonic loci and are myofascial trigger points.

### References

1. De Kanter RJ, Truin G.J, Burgesdijk RC, Kalsbeek H, Käyser AF. Prevalence in the Dutch adult population and a meta-analysis of signs and symptoms of temporomandibular disorders. *J Dent Res.* 1993; 11: 1509-1517.
2. Petrosov J.A. Diagnosis and prosthetic treatment of temporomandibular joint diseases. *Soviet Cuban.* 2007; 304.
3. Bjornland T, Gjaerum A.A, Moystad A. Osteoarthritis of the temporomandibular joint: an evaluation of the effects and complications of corticosteroid injection compared with injection with sodium hyaluronate. *J oral Rehabil.* 2007; 34: 583-589.
4. Lepilin A. V, Konnov V V, Bagaryan E. F, Arushanyan A R. Clinical manifestations of the pathology of the temporomandibular joint and masticatory muscles in patients with impaired occlusion of teeth and dentition. *J SaratovskiyScientific medical.* 2010; 2: 405-410.
5. Silin AV, Lila A M. Complex treatment of musculo-articular dysfunction of the temporomandibular joint in patients with malocclusion. *J Institute of dentistry.* 2009; 1: 39-41.
6. Hvatova V. A. Gnatological aspects of orthodontic treatment. *J Maestro of dentistry.* 2004; 3: 69-72.
7. Dolgalev A. A., Usmanskaya Y. I. Effect of connective tissue dysplasia on the development of TMJ dysfunction. *J Med Vestnikof North Caucasus.* 2013; 4: 65-68.
8. Jerjets W, Madland G, Feinmann C. *J Oral Surg Oral Med Oral Pathol Oral RadiolEndod.* 2007; 3: 367-373.

9. Orlova O. R, Mingazova L R. Myofascial facial pain syndrome: new aspects of the clinic, pathogenesis and treatment. *J New in Dentistry*. 2003; 1: 26.
10. Scoricova L.A. Clinical forms of parafunction of the masticatory muscles. *J New in Dentistry*. 2000; 7: 83-85.
11. Moreno-Hay I, Okeson J P. Does altering the occlusion vertical dimension produce temporomandibular disorders? A literature review. *J Oral Rehabil*. 2015; 3.
12. Calixtre LB, Moreira R F., Franchini G H. Manual therapy for management of pain and limited range of motion in subject with signs and symptoms of temporomandibular disorder: a systematic review of randomized controlled trials. *J Oral Rehabil*. 2015; 42: 847-861.
13. Al-Ahmad H.T, Al-Qudah M A. The treatment of masseter hypertrophy with botulinum toxin type A. *Saudi Med J*. 2006; 27: 397-400.