

The Autosomal Dominant Facio-Scapulo-Limb Type 2 (The Same Disease as the FSHD1 or the Facioscapulo-peroneal Muscular Dystrophy with 4q35 Chromosomal Deletion). Some Peculiarities of the Pattern of Muscle Involvement

Valery M Kazakov^{1,2*}, Dmitry I Rudenko^{1,2}, Vladislav O Kolynin^{1,2}, Tima R Stuchevskaya^{1,2} and Alexander A Skoromets¹

¹Department of Neurology, First St. Petersburg Pavlov State Medical University, Russia

²Neuromuscular Department of City Hospital 2 of St. Petersburg, Russia

Article Information

Received date: Feb 09, 2018

Accepted date: Mar 01, 2018

Published date: Mar 07, 2018

*Corresponding author

Valery M Kazakov, Department of Neurology, First St. Petersburg Pavlov State Medical University, Russia, Tel: +7 812 323 2121; Email: valerykazakov@mail.ru

Distributed under Creative Commons CC-BY 4.0

Keywords

Facioscapulohumeral Dystrophy; Facioscapulo-peroneal Dystrophy; Scapulo-peroneal Dystrophy; Facioscapulo-humeral Dystrophy 4q35 Linked

Abbreviations

Ph: Phenotypes; FS: Facioscapular; FSP: Facioscapulo-peroneal; FSPF: Facio-Scapulo-Peroneal-Femoral (Posterior Group Of The Muscles); FSPH: Facio-Scapulo-Peroneal-Humeral; FSPFG: Facio-Scapulo-Peroneal-Femoro-Gluteal (Gluteus Maximus Muscle); FSPFGH: Facio-Scapulo-Peroneal-Femoro-Gluteo-Humeral (Biceps Brachii Muscle); FSPHFG: Facio-Scapulo-Peroneal-Humero-Femoro-Gluteal; FSLD: Facioscapulohumeral Muscular Dystrophy; FSHD: Facioscapulo-humeral Muscular Dystrophy; SPD: Scapulo-peroneal Muscular Dystrophy; F: Minimal Or Slight Affection Of The Isolated Facial Muscles or Their Parts; H: Slight Affection (Grade 4) Biceps Brachii Muscle; S: Asymptomatic Atrophy And Weakness of The Lower And Middle Parts of Trapezius Muscle; (FG): Slight Affection (Grade 4) Posterior Group of Thigh Muscles And Gluteus Maximus; Pr: Presymptomatic; № F: Number of Family; DFS: DNA Fragment Size; Kb: Kilobases; C.H: Data From Case History

Article DOI 10.36876/smmd.1024

OPEN ACCESS

ISSN: 2576-5442

Abstract

We examined 59 patients (33 symptomatic and 26 presymptomatic) from 21 autosomal dominant families with 4q35 linked muscular dystrophy with the initial involvement of the face and shoulder girdle muscles and subsequently of the peroneal group (anterior tibial) muscles. However in most symptomatic patients the dystrophic process is not limited to these anatomical regions and is gradually extended to the thighs (posterior group of the muscles, but not quadriceps), pelvic girdle (gluteus maximus, but not gluteus medius) and not always to upper arm (biceps brachii). The dynamics of the clinical muscle pattern at different stages of the disease was confirmed by CT and MRI muscle study. Thus, our clinical study, CT and MRI studies show that in observed patients there are widespread involvements of the lower limb muscles. In this connection, the inaccuracy of the term "facio-scapulo-humeral (FSH)" or "Facio-Scapulo-Peroneal (FSP)" or "scapulo-peroneal with minimal/slight affection of facial muscles [(F)SP]" muscular dystrophy becomes evident. The term "Facioscapulohumeral Muscular Dystrophy, type 2 (FSLD2), descending with a "jump" with initial (F)SP or FSP phenotypes with 4q35 deletion" would be more correct. The (F)SP or the FSP phenotypes constituted merely a stage in the development of FSLD2. In many observed patients we revealed a very slight weakness (or atrophy) of individual mimic muscles or their parts, especially during the scapulo-peroneal phenotype stage of the disease. A usually slight degree of weakness of the biceps brachii muscles was followed as a rule by the weakness of the peroneal group, posterior group of the thigh and gluteus maximus muscles. We suppose the FSLD2 is an independent form of the muscular dystrophy.

Introduction

Some authors suppose that the Scapulo-peroneal Muscular Dystrophy (SPD) with or without affection of the facial muscles is probably a variant of the Facioscapulo-humeral Muscular Dystrophy (FSHD) [1-5]. Others suppose that SPD is probably an independent form of the disease [6-12]. It is not clear what degree of affection of isolated mimic muscles must be in the SPD patient in order to add the word "facio" to the name "scapulo-peroneal"? It is unclear when biceps brachii muscles are involved in the dystrophic process in a patient with SPD, as well: is it before or after an affection of the lower limb muscles. Besides, authors have various opinions on the time of involvement of the peroneal group muscles. Some authors [10,11,13] suppose that the peroneal group muscles are the first to be involved in the dystrophic process.

The aim of the investigation was to clarify the sequence of separate muscles and muscle groups involvement, and to establish the phenotypes of the muscle weakness at different stages of the facioscapulohumeral, type 2 muscular dystrophy (FSLD2) linked with chromosome 4q35.

Patients and Methods

59 patients from 21 autosomal dominant FSLD2 families were examined. Among 59 patients, 33 (55, 9%) (12 men and 21 women; 24-86 years old) were symptomatic and 26 (44.06%) (9 men and 17 women; 6-30 years old) were presymptomatic (Pr). Among 33 symptomatic patients 25 (75.5%) had a Severe Degree of the Disease (SDD), 7 (21.2%) - a moderate (MoDD) and 3 (9%) - a mild (MDD) degree of the disease. We can observe the dynamic pattern of the muscle affection (the myogenic phenotype) and the disease severity in 24 FSLD2 patients who were re-examined

(V. Kazakov) after 3-22.5 years (11 men), 24-37 years old (11 men) and 43-49 years old (3 men) (Table 1). The diagnosis of FSLD2 was confirmed in all the patients by molecular genetic analysis of the isolated DNA which was performed by the EcoRI/BlnI double digestion using the p13E-11 (D4F104S) probe and other 4q35 markers (D4S139, D4S153) in the Department of Neuromuscular Research, National Institute of Neuroscience, NCNP, Tokyo, Japan [14]. Moreover, in two-four members of each family the muscular dystrophy diagnosis was supported by the myopathic needle EMG and the normal motor and the sensory nerves conduction velocity ("Viking IV", Nicolet, USA and concentric needle electrodes were used), myopathic changes on the supraspinatus or tibialis anterior muscle biopsy stained by hematoxylin and eosin (in 7 families from 21) as well as on CT or MRI of the lower limbs muscle (17 patients from 21 families). To reveal the sequence of the muscle involvement and to establish the time of appearance of separate muscle and muscle group's distribution a special test questionnaire was used [15]. Muscle strength was measured manually [16] using a 10-grade scale. The investigation of the trophics and function of the muscles, and abnormal postures of separate segments of limbs and the body and muscle retractions was conducted according to Kendall and Kendall [17]. Mimic muscle strength, the disease severity degree and the degree of the Daily-Life Work Disability (DLWD) in FSLD2 patients (was) were measured according to the criteria defined by Kazakov [18,19]. Computed Tomography (CT) of lower limb muscles in the mid-sections of the thigh and lower leg was performed bilaterally on a computer tomograph (Siemens, Somatom, Germany) in axial 5mm thick slices. Abnormal signal was classified according to Hawley et al. [20]. Magnetic resonance imaging (MRI) of 20 muscles bilaterally was performed on a 1.5-tesla Siemens; Magnetom Vision system using axial T1 weighted (T1W) images. 20 sections of the muscle were analyzed with an emphasis to the mid-sections of the thighs and lower legs with 8 mm thick and the 9mm gap between the slices. Abnormal signal was classified according to Jungbluth H. et al. [21].

Results

In all the families, which had the same or different DNA Fragment Size (DFS) ranging between 13-35 kb (double digestion) and linked with 4q35, we observed the similar clinical variability of phenotype between the patients belonging both to the same family and to different ones that is within and between the families (Table 1). We found the different degrees of the mimic muscles weakness among the patients belonging to the same family. We did not encounter patients with the spared facial muscles. Among 22 patients with the developed disease including 15 with the (Facio)Scapuloperoneal [(F)SP] and 7 with the final (Facio)-Scapulo-Peroneal-Femoro (Posterior Group Of The Muscles)-Gluteo (Gluteus Maximus)-Humeral (biceps brachii, affected in a slight degree) [(F)SPFG(H)] phenotypes very slight weakness (or atrophy) of separate mimic muscles or their portions (more often orbicularis oris and orbicularis oculi) was observed. 11 other patients with the final facio-scapulo-peroneal-femoro-gluteal (FSPFG) and FSPFG(H) or FSPFGH phenotypes had severe weakness (and atrophy) of orbicularis oris or its parts, more often on one side, together with the different degrees of the weakness of one of the mimic muscles (orbicularis oculi, zygomaticus, levator labii superioris, levator anguli oris, frontalis) on the same or on another side. Some of these patients had features of the myopathic face observed only while speaking, laughing and especially smiling.

However even among the patients with a marked affection of the isolated facial muscles and with the features of myopathic face there were no persons who complained of the weakness or atrophy of the mimic muscles or changes of the facial expression. These patients as well as their parents and closest relatives did not notice the affection of the mimic muscles. The majority of the patients who had even the final FSPFGH phenotype of the disease learned about their mimic muscle disturbances for the first time from V.K. during their examination. The patients considered that in the earlier period of the disease the shoulder girdle muscles had been affected. Some of these patients even supposed that the weakness of extensors of feet was the first symptom of the disease. However, a special test questionnaire used in patients and their relatives permitted to establish that in the majority of these patients the face was affected simultaneously with the shoulder girdle muscles or even earlier, although in some patients the disease began with the abnormal posture of shoulder girdle. Thus, in many patients observed we revealed a very slight weakness of the individual mimic muscles or their portions, especially at the stage of the disease presenting the scapuloperoneal (SP) phenotype which would be more correct to refer to as a (facio)scapuloperoneal [(F)SP] phenotype.

Another clinical peculiarity of the disease studied was a very late and usually a slight affection of the upper arm (biceps brachii) muscles). In 18 of patients having a final phenotype of the disease called FSPFG or (F)SPFG the biceps brachii muscles were preserved (5 men) or were weakened (in) to a slight degree (grade 4) only on one side [9 men with (FSPFG(H) or (F)SPFG(H) phenotypes] although the disease started in childhood. Only 4 patients (from different 4 families) had severe affection (grade 2) of biceps muscles although in other relatives with final phenotypes these muscles were spared (in 3 families) or weakened in a slight degree only on one side (1 family). We could not reveal the pure facioscapulohumeral (FSH) and scapulohumeral (SH) phenotypes of the muscle weakness among 59 examined patients including Pr ones. As a rule, biceps brachii weakness appeared in patients after the appearance of weakness of lower limb (peroneal group, posterior group of the thigh) and pelvic girdle (gluteus maximus) muscles. These patients had the final phenotype FSPFG(H) or (F)SPFG(H). Only in five patients the biceps brachii muscles were affected after the severe affection of the peroneal group muscles, namely anterior tibial. These patients had a facio-scapulo-peroneal-humero-femoro-gluteal (FSPHFG) phenotype.

To illustrate this we would like to give a short description of the two typical FSLD2 families in which the patients were re-examined by V.K. after 24 -28, 35 - 37, 44 and 47 years (one patient from family 8 and other from family 2) and in which changes of the phenotype on the different stages of the FSLD2 were observed (Table 2).

Family 2, DFS 24/27 kb. The proband, III-7 (Table 2), a woman aged 73, has slept with the semi-open eyes since childhood. From early school years she had a round-shoulder and a "sunken" chest. At the age of 18 the marked weakness of extensors of the left foot appeared.

In 1960 the patient, aged 36, according to her case history, had a "pure" scapuloperoneal phenotype with minimal weakness of orbicularis oris and orbicularis oculi muscles.

During the first examination in 1969 at the age of 45 the patient

had a severe asymmetrical scapulo-peroneal phenotype with a very mild weakness of the left half of the orbicularis oris and orbital part of the orbicularis oculi muscles (Figure 1a-c). Moreover, a slight weakness of the posterior thigh and gluteus maximus muscles only on the left side was found.

On re-examination after 24 years, in 1993 (at the age of 69) her phenotype switched to an asymmetrical final facio-scapulo-peroneal-femoro-gluteo-(humeral) [FSPFG(H)] one with severe weakness of the orbicularis oris (upper part) and the orbicularis oculi (orbital part), scapulo-peroneal region and abdominal muscles and moderate weakness (grade 3+) of the posterior thigh and gluteus maximus muscles and with slight weakness (grade 4) of the biceps brachii muscle only on the left side (Figure 1d-g). The gluteus medius,

iliopsoas and quadriceps muscles strength was spared. Deep reflexes were extremely lowered. Sensation was intact. Serum CK was 36 IU (normal to 190 IU). A biopsy specimen of her supraspinatus muscle showed myopathic changes. NCV were normal. EMG showed myogenic changes. CT of the patient (at the age of 71) showed a total/severe involvement of anterior and superficial posterior compartments of lower leg muscles, semimembranosus and adductor of thighs with sparing of quadriceps, peroneus longus on the right side and deep posterior compartment of lower leg muscles (Figure 1h-i).

The patient was re-examined again after 28 years, in 1997 (at the age of 73). Her clinical phenotype of muscle weakness did not substantially change but she could not stand up on her toes.

Table 1: Myogenic Phenotype and Severity disease Dynamics Versus DFS in 27 patients with AD FSLD2.

№ F	DFS Kb	№ in pedigree	Age exm	M. Ph.	D. S. disease	DLWD	D yrs	Age Re exm	M. Ph	D.S. disease
2	24	III-7	36h	(F)SP	MoD	2	-37			
			45	(F)SP(FG)	SDD	2	28	73	FSPFG(H)	SDD
		III-10	36	(F)SP	SDD	2	37	73	(F)SP	SDD
		IV-8	6	F(S)	Pr	1	36	42	FSP	MoD
5	22	IV-7	23	(F)SP(F)	SDD	2	29	52	FSPFG(H)	SDD
		V-4	1.5	Normal			22	24	(F)SP	Pr
8	20	II-13	60	(F)SP	SDD	2	28	88	(F)SPFG(H)	SDD
		III-25	28	(F)SP	Pr	1	44	72	(F)SP	MDD
		IV-17	5.5	F(S)	Pr	1	35	41	FSP(F)	SDD
13	25	IIII-8	26h.	FSP(H)	SDD	2	-37	63	FSPHFG	SDD
18	24	III-3	18h.	F(S)	MDD	1	-49	67	FSPFG(H)	SDD
20	13	III-2	73	FSP(FG)	SDD	2	7	80	FSPFG(H)	SDD
		III-10	62	FSPH(FG)	SDD	2	3	65	FSPHFG	SDD
		IV-2	18h	FS	MDD	1	30	48	FSPFG	SDD
19	17	III-4	47h	(F)S	MDD	1	-8	55	(F)SP(FG)	SDD
		IV-2	19h	(F)SP	MDD	1	-20	39	FSPFGH	SDD
16	20	III-5	45	FSP	SDD	2	13	58	FSPFG	SDD
		IV-6	21	FSP	MoDD	2	15	3	FSP(F)	MoDD
		IV-10	17	FSPH(FG)	SDD	2	18	35	FSPHFG	SDD
21	14	II-6	49	FSP	MDD	1	11	60	FSPFG	SDD
		III-5	25	FSPFGH	SDD	3	14	39	FSPFGH	SDD
		III-7	14	(F)SP	Pr	1	12	26	(F)SP	Pr
22	20	III-1	42	FSP	MoDD	2	7	49	FSP	SDD
9a	13	IV-1	25h.	(F)S	Pr	1	-49	74	(F)SPFG	SDD
13a	23	III-1	18h.	(F)SP	Pr	1	-27	45	FSPFG	SDD
1	23	IV-42	31	FSP	Pr	1	24	55	FSP(FGH)	MoDD
15	21	V-10	10	S	Pr	1	24	34	(F)SP	Pr
	30	V-17	15	(F)S	Pr	1	24	39	(F)SP	Pr

№ F: Number of Family; DFS: DNA Fragment Size; Kb: Kilobases;

Age exm: Age Examination; M. Ph: Myogenic Phenotype; D.S. disease: Degree Severity of Disease;

DLWD: Daily-Life Work Disability; D. yrs: Duration of the Disease Before Reexamination;

Age reexam: Age of Reexamination; Pr: Presymptomatic; MDD: Mild Degree of the Disease;

MoDD: Moderate Degree of the Disease; SDD: Severe Degree of the Disease; h: myogenic phenotype [19].

Citation: Kazakov VM, Rudenko DI, Kolynin VO, Stuchevskaya TR and Skoromets AA. The Autosomal Dominant Facio-Scapulo-Limb Type 2 (The Same Disease as the FSHD1 or the Facioscapulo-peroneal Muscular Dystrophy with 4q35 Chromosomal Deletion). Some Peculiarities of the Pattern of Muscle Involvement. SM Musculoskelet Disord. 2018; 3(1): 1024. <https://dx.doi.org/10.36876/smmd.1024>

Table 2: Phenotypes (the static and dynamic muscle pattern) in patients from the families 2 and 8 with 4q 35-linked AD FSLD2.

N#F DFS, Kb	Members	Age onset yr	Age exam yr	Year exam	Phenotypes
F. 2 27/24	proband	6-10	36 ^{c.h.}	1960	(F)SP
			45	1969	(F)SP(FG)
			69	1993	FSPFG(H)
			73	1997	FSPFG(H)
	proband's brother	6-10	36	1969	(F)SP
			60	1993	(F)SP
			64	1997	(F)SP
			73	2005	(F)SP
proband's niece	<5	6	1969	(F)S	
		30	1993	FSP	
		42	2005	FSP	
		55	2015	FSP(F)G	
F. 8 23/20	proband	6-10	60	1969	(F)SP
			86	1994	FSPFG(H)
	proband's daughter	?	88	1996	FSPFG(H)
			28	1969	(F)SP
			55	1996	(F)SP
	proband's granddaughter	<5	72	2013	(F)SP
			5.5	1969	(F)S
			29	1993	FSP
32			1996	FSP	
			41	2004	FSP(F)

Thus, in this patient the severe scapuloperoneal phenotype with very slight weakness of the orbicularis oris and orbicularis oculi muscles had persisted in the clinical picture for about 10 years and then gradually passed onto final FSPFG(H) phenotype with severe weakness of the orbicularis oris muscle (upper part).

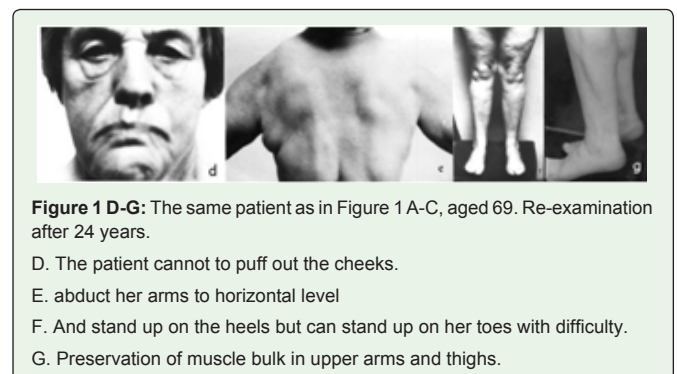
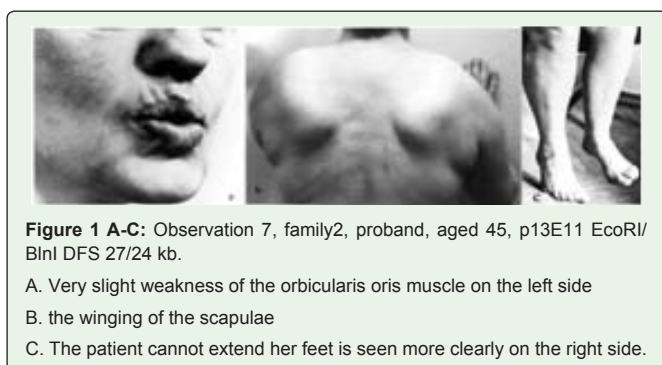
The patient worked as an engineer until 55 till retirement and continued working after that. At present (January 2005) she (aged 80) can climb the stairs with the aid of railing to the 4 floor, walk independently the streets at a short distance and she cannot use a public transport.

The proband's brother, III-10 (table 2), aged 73 and had a "sunken" chest and a "round" back since childhood. At the age of 18 the marked weakness of the extensors of the left foot appeared.

During the first examination in 1969, aged 36, he had a "pure" asymmetrical and severe (F)SP phenotype with minimal atrophy of the upper lip only on the right side and a slight weakness of the orbicularis oculi muscles (the orbital parts) (Figure 2 a-c).

On re-examination after 24 and 28 years, in 1993/97 (at the age of 60 and 64) he had the same (F)SP phenotype with a slight weakness of the orbicularis oris muscle on the right side and orbital part of orbicularis oculi muscles (2 d-g). The abdominal muscles were preserved. His deep reflexes were lowered and sensation was intact. NCV were normal. EMG showed myopathic changes.

The patient was re-examined again after 37 years in December 2005 (at the age of 73). His clinical (F)SP of muscle weakness was



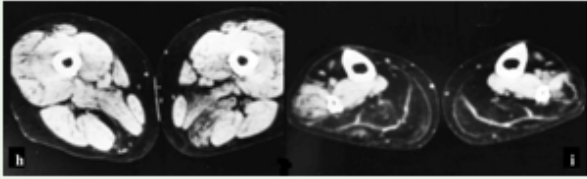


Figure 1 H-I: The same patient as in Figure 1A-G aged 71.
 H. CT of the thigh muscles. Description thigh muscle.
 I. CT of the lower leg muscles. Description of lower leg muscles.

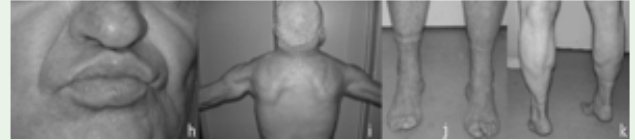

Figure 2 H-K: The same patient as in Figure 2A-G, aged 73. Re-examination after 37 years.
 H. Slight atrophy of the upper lip on the right side.
 I. The patient cannot abduct arms to horizontal level.
 J. And stand up on his heels.
 K. But can stand up on his toes.

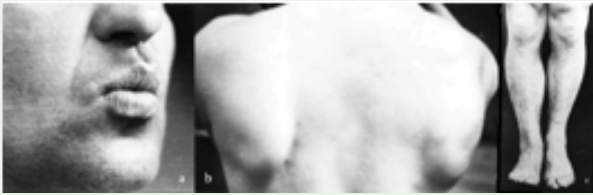

Figure 2 A-C: Observation 8, family 2, proband's brother, aged 36, DFS 27/24 kb.
 A. Minimal atrophy of the upper lip on the right side.
 B. The scapulae sharp displacement outwards and forwards, winging of the scapulae.
 C. Inability to stand up on the heels is more clearly seen the left side.

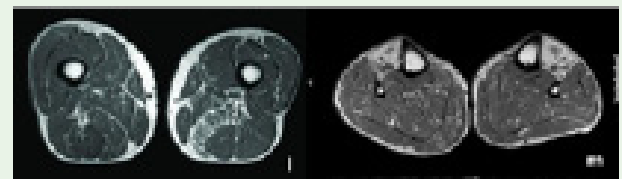


Figure 2 L-M: The same patient as in Figure 2 A-K, aged 73.
 L. MRI of thigh muscles. Description thigh muscle.
 M. MRI of lower leg muscles. Description of lower leg muscles.

not changed (Figure 2 h-k). MRI T1W images (at the age 72) showed a severe involvement of the anterior compartment of the lower leg muscles and semimembranosus and adductor magnus with sparing quadriceps, except the rectus femoris, and with sparing of the peroneus longus and deep posterior compartment of the lower leg muscles (Figure 2 l-m).

Thus, in this patient the severe scapuloperoneal phenotype with very slight weakness of the right half of the upper lip and the orbital part of the orbicularis oculi muscles has persisted in the clinical picture for more than 36 years.

The patient worked as a driver until 60 the pension time and continued working after that. At present(December 2005) he (aged 73) can walk the streets and use public transport.

The proband's niece, VI-8 (Table 2) at the first examination, in 1969 (at the age of 6) was Presymptomatic (Pr) with a Facio(Scapular) [F(S)] phenotype with slight weakness of the upper part of orbicularis

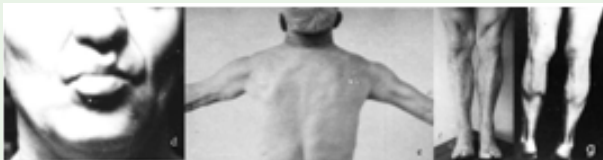

Figure 2 D-G: The same patient as in Figure 2A-C aged 60. Re-examination after 24 years.
 D. Asymmetry of the lips when puckering them to whistle.
 E. Severe weakness of the trapezius and serratus anterior muscles; slight atrophy of the triceps brachii muscles without decreasing of their strength.
 F. Inability to stand up on the heels is more clearly seen on the left side.
 G. The patient can stand up on his toes; preservation of muscle bulk in thighs.

oris muscle on the right side and severe weakness of orbital part of the orbicularis oculi muscles (Figure 3 a-b) and asymptomatic atrophy of the lower part of trapezius muscles only on the left side.

On re-examination after 24 years, in 1993 (at the age of 30) she had a "pure" asymmetrical FSP phenotype with a severe weakness of the orbicularis oris muscle on the right side and a moderate weakness of the muscles of scapuloperoneal region (Figure 3 c-e). The strength of the abdominal muscles was normal. Her deep reflexes were lowered. Sensation was normal. NCV were normal. EMG showed myopathic changes.

The patient was re-examined again after 36 years, in January 2005 (at the age of 42). Her clinical phenotype of the muscle weakness was not changed (Figure 3 f-i). MRI T1W images (at the age of 42) showed a total/severe involvement of the anterior compartment of the lower leg muscles, hamstrings and adductor longus with sparing of the

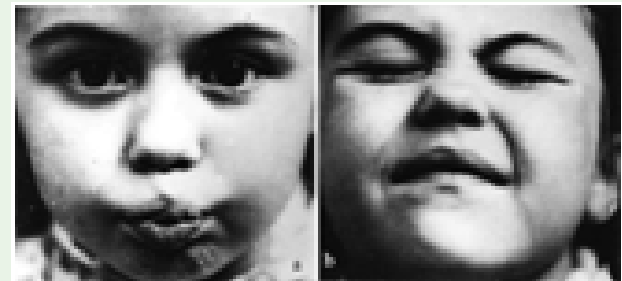

Figure 3 A-B: Observation 11, family 2, the proband's niece aged 6, DFS 27/24 kb.
 A. Very slight weakness of orbicularis oris on the right side; asymmetry of the lips when puckering them to whistle.
 B. Severe weakness of the orbital parts of the orbicularis oculi muscles; on attempting to screw up the eyes, the eyelids are not fully concealed in the depths of the eyelids.

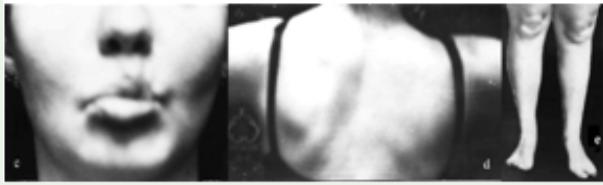


Figure 3 C-E: The same patient as in Figure 3 A-B, aged 30. Re-examination after 24 years.

- C. Severe weakness and atrophy of the upper part of orbicularis oris muscle on the right side.
- D. In abduction of the arms the scapulae recede from the chest, which is more clearly seen on the left side.
- E. Inability to stand up on the heels is seen more clearly on the left side.

quadriceps, except for the rectus femoris on the right side, and with sparing peroneus longus and deep posterior compartment of lower leg muscles (Figure 3 j-k). On re-examination in June 2016, after 47 years (at the age of 55) this patient had an extremely asymmetrical facio-scapulo-peroneal-femoro (left posterior thigh muscles) - gluteal (gluteus maximus muscles) phenotype more expressed on the left side. She had a moderate weakness of abdominal and severe weakness of the gluteus maximus muscles, but posterior thigh muscles had a moderate weakness (grade 3+) on left side only. She had a moderate lumbar lordosis. The upper arm muscles as well as gluteus medius, iliopsoas, quadriceps and right posterior thigh muscles strength were spared. Deep reflexes were extremely lowered. She could not stand up on her heels and could stand up on her toes with difficulty.

Thus, in this patient the scapuloperoneal phenotype with severe weakness of the right half of the orbicularis oris and a lesser degree of the orbital part of the orbicularis oculi muscles has persisted in the clinical picture for more than 12 years. The patient works as an engineer, walks the streets and uses a public transport (Table 2).

Family 8, DFS 23/20 kb. The proband II-13 (Table 2) a man, aged 88, has had a “sunken” chest and a round-shoulder with scapulae receding from the chest since childhood.

At the first examination in 1969 in patient, aged 60, a “pure” and a severe scapuloperoneal phenotype with a slight weakness of the orbicularis oculi (orbital part) muscles was found (Figure 4 a-d).

On re-examination after 25 and 27 years, in 1994/96 (at the age of 86 and 88) the patient had the same final FSPFG(H) phenotype with a severe affection of the orbicularis oculi (orbital part), scapuloperoneal



Figure 3 F-I: The same patient as in Figure 3 A-E, aged 42. Re-examination after 36 years.

- F. The patient cannot pucker lips to whistle.
- G. Abduct arms to vertical level.
- H. and stand up on her heels.
- I. but can stand up on her toes.

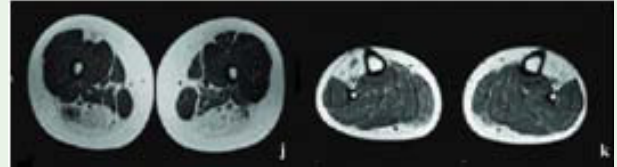


Figure 3 J-K: The same patient as in Figure 3 C-I, aged 42.

- J. MRI of thigh muscles. Description thigh muscle.
- K. MRI of lower leg muscles. Description of lower leg muscles.

region and abdominal muscles and moderate weakness (grade 3+) posterior of thigh and gluteus maximus muscles and a slight weakness (grade 4) of the biceps brachii muscle only on the left side. The gluteus medius, iliopsoas and quadriceps muscles strength was spared. He could rise from his bed and chair without assistance, could not stand up on his heels and could stand up on his toes with difficulty. His deep reflexes were extremely lowered on the arms and legs. Serum CK was 72 IU (normal to 190 IU). NCV were normal. EMG showed myogenic changes. CT (at the age of 88) showed (the) a selective affection of some thigh and lower leg muscles (Figure 4 e-f).

Thus, in this patient the severe scapuloperoneal phenotype with slight weakness of the orbital part of orbicularis oculi muscles had predominated in the clinical picture for a very long period of time and then gradually was switched to the final FSPFG(H) phenotype with severe weakness of the orbital part of orbicularis oculi muscles.

The patient worked as a sales manager until 60 retirement and continued working after that. At the age of 88 he did not use a wheelchair and could walk the streets with the aid of stick only at short distances. He died at the age of 88 from an acute ischemic stroke.

The proband’s daughter, III-25 (Table 2), aged 72, at the first examination in 1969 at the age of 28 and on re-examination after 27 and 44 years (in 1996 and 2013), at the age of 55 and 72 respectively) had the same pure (F)SP phenotype with a minimal weakness of the orbicularis oculi (the orbital part) muscles and with asymptomatic slight weakness of the lower parts of trapezius and tibialis anterior and moderate weakness of the extensor digitorum longus muscles more clear on the right side. The patient did not spot her motor disturbances and supposed that she was healthy (Figure 5 a-b).

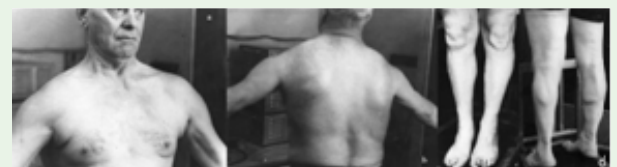

Figure 4 A-D: Observation 32, family 8, the proband aged 60, p13E11

- EcoRI/BlnI DFS 23/30 kb. Protuberance of anterior surface of medial half of the left clavicle and local hollow on the anterior surface of the chest are due to severe atrophy of the left pectoralis major muscle, especially of its sternocostal part and partly clavicular one; displacement of the shoulder girdle downwards and forwards is due to severe weakness of the muscles fixing the scapulae; preservation of muscle bulk in upper arms
- A. The patient cannot abduct his arms to horizontal level
 - B. And stand up on the heels
 - C. But can stand up on the toes.
 - D. Preservation of muscle bulk in thighs.

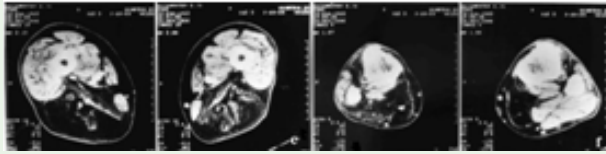


Figure 4 E-F: The same patient as in Figure 4 A-D at the age of 88. Re-examination after 28 years.

- E. CT of the thigh muscles. Description thigh muscle.
- F. CT of the lower leg muscles. Description of lower leg muscles.

The proband's granddaughter, VI-17 (Table 2), on the first examination in 1969 (at the age of 5.5) was presymptomatic with facio(scapular) [F(S)] phenotype with severe weakness of the orbital part of orbicularis oculi and very slight weakness of orbicularis oris muscles (Figure 6 a-b).

On re-examination after 24 years, in 1993 (at the age of 29) her F(S) phenotype switched to the pure FSP phenotype with severe weakness and atrophy of some facial, shoulder girdle and peroneal group muscles with a course stepping gait (Figure 6 c-e). The abdominal muscles were spared. Her deep reflexes and sensation were intact. Serum CK was 117 IU (normal to 190 IU). A biopsy specimen of her tibial anterior muscle showed myopathic changes. NCV were normal on both sides. EMG showed myogenic changes. A CT study (at the age of 31) revealed the selective fatty replacement of some lower legs and thighs muscles (Figure 6 f-g).

On re-examination of this patient after 27 years, in 1996 (at the age of 33) her clinical phenotype was the same as at the age of 29.

The patient was re-examined again after 35 years, in December 2004 (at the age of 41). Her FSP phenotype of muscle weakness switched to a facio-scapulo-peroneo-(femoral) one [FSP(F)]: the posterior group of thigh and abdominal muscles were slightly weakened (grade 4) (Figure 6 h-k). MRI T1W images (at the age of 41) showed a total/severe involvement of the anterior and the superficial posterior compartments of the lower leg muscles and hamstrings with sparing of the quadriceps, peroneus longus and deep posterior compartment of lower leg muscles (Figure 6 l-m).

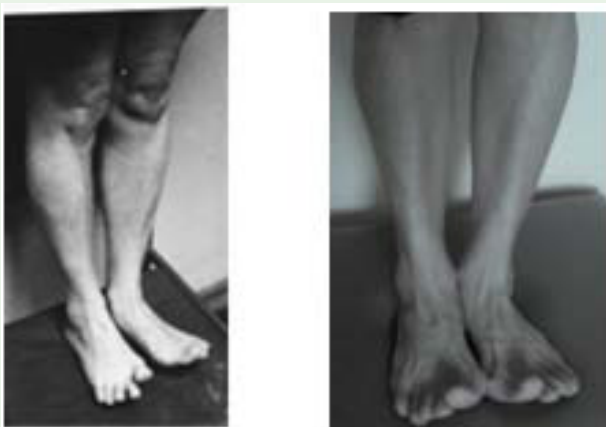

Figure 5 A-B: The proband's daughter, III-2, aged 28 (A) and 72 (B) years old. Asymptomatic slight weakness of the tibialis anterior and moderate weakness of extensor digitorum longus and extensor digitorum brevis muscles on both sides are more clearly seen on the right side.

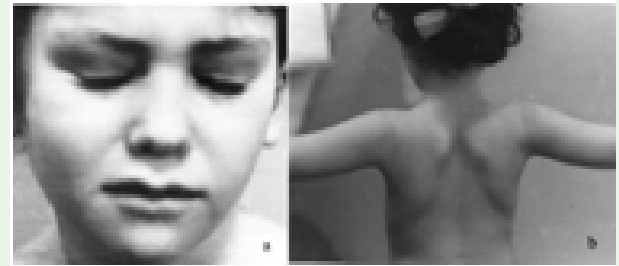

Figure 6 A-B: Observation 33, family 8, proband's granddaughter, aged 5.5, DFS 23/20 kb. No function of the orbital parts of the orbicularis oculi muscles; on attempting to crew up the eyes, eyelids only touch; there are no radial wrinkles in the external angles of the orbits, and the corrugator and procerus muscles do not contract.

- A. Crying-like face is the sign of the weakness of the orbicularis oris muscle.
- B. Slight atrophy of the middle and lower parts of trapezius muscles.

Thus, in this patient the scapuloperoneal phenotype with severe weakness of the some facial muscles had persisted in the clinical picture for about 12 years and then passed into FSP(F) phenotype. The patient works as a software specialist, walks the streets and uses public transport.

In all the other members with the developed stage of the disease from the other 19 families the same gradual transformation of the initial FSP or (F)SP phenotypes to the final ones [FSPFG or FSPFG(H)] or (F)SPFG(H) or rarely in FSPFGH and FSPHFG] was observed. However it should be emphasized that in patients who had a final phenotype the muscles fixing the scapulae (especially trapezius and serratus anterior) and the peroneal group (especially tibialis anterior, extensor digitorum longus and extensor hallucis longus) were more severely affected than the posterior group of thigh and gluteus maximus muscles. In these patients the scapulo-peroneal topography of the muscle weakness predominated in the clinical picture throughout almost all their lifetime.

In all the patients who had the final FSPFG or FSPFG(H) phenotypes the abdominal muscles were severely affected. However, in these patients the abdominal muscles were involved in a dystrophic process, usually followed by the appearance of the weakness of the individual lower limb (anterior tibial, posterior group of thigh) and

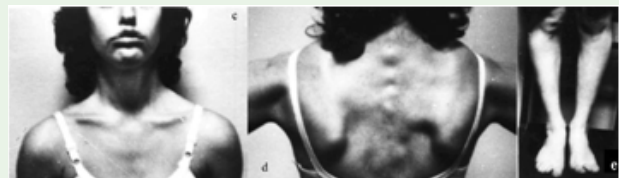

Figure 6 C-E: The same patient as in Figure 6 a-b aged 29. Re-examination after 24 years.

- A. Inability to pucker lips to whistle; protuberance of the sternum and cartilages of ribs due to severe atrophy of the sternocostal portions of pectoralis major muscles on both sides.
- B. severe involvement of trapezius muscle, the middle and lower parts; displacement of the scapulae upwards and approximation of their lower angles to the vertebral column due to the contraction of levator anguli scapulae and the remnants of rhomboid muscles.
- C. Inability to stand up on the heels; the peroneal group muscles almost do not function on both sides.

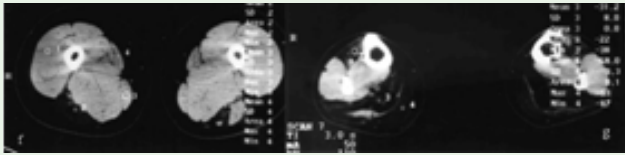


Figure 6 F-G: The same patient as a Figure 6 a-e at the age of 31.
 F. CT of the thigh muscles. Description thigh muscle.
 G. CT of the lower leg muscles. Description of lower leg muscles.

pelvic girdle (gluteus maximus) muscles; or the abdominal muscles were affected simultaneously with the involvement of the posterior group of thigh and gluteus maximus muscles. The gastrocnemius muscles were clinically involved (the patient could stand up on the toes with difficulty) in six patients with final phenotypes and in one patient with a FSPF phenotype only at the late stage of the disease.

Thus, in 21 Russian AD FSLD2 families with the same or different DFS ranging between 13-35 kb (double digestion) a great similarity of clinical manifestations among the members of the family was noted (Table 1). The same muscles and muscle groups were affected. Clinical variability of phenotypes, differing by the degree and frequency of affection of the same muscles, reflecting various stages of the disease and different expressivity of mutant gene, was always within the limits of the identical final FSPFG or FSPFG(H) phenotype (Table 1). The disease began with the initial involvement of the face and shoulder girdle muscles and sometime later of the peroneal group (anterior tibial) muscles. However, in most patients the process was not limited to those anatomical regions and was gradually extended to the thighs (posterior group of the muscles, namely), pelvic girdle (namely, gluteus maximus) and not always to upper arm (biceps brachii). Although the FSP or (F)SP phenotypes in some patients of the family could predominate in the clinical picture for many years we did not encounter the families in which the clinical picture was presented as a “pure” FSP phenotype in all the patients throughout their lifetime (Table 1).

The muscle CT and MRI in observed patients more frequently showed severe involvement of anterior compartment of lower leg muscles (tibialis anterior, extensor digitorum longus and extensor hallucis longus), posterior thigh muscles (semimembranosus, long head of biceps femoris and semitendinosus), rectus femoris and later of adductors of thighs and gastrocnemius (medial heads) and in a less degree of soleus with sparing of the peroneus longus and deep posterior compartment of the lower leg, quadriceps, gracilis and sartorius muscles.

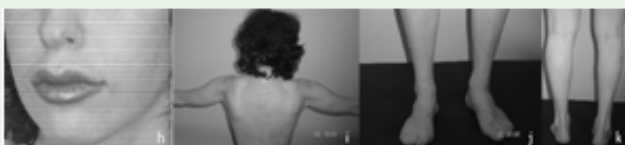

Figure 6 H-K: The same patient as in Figure 6 a-e aged 41. Re-examination after 36 years.
 H. The patient cannot pucker lips to whistle.
 I. Abduct arms to vertical level.
 J. And stand up on her heels.
 K. But can stand up on her toes.

The radiological muscle pattern does not fully correlate with the clinical pattern of the muscle weakness. In patients with a FSP phenotype the posterior of thigh and quadriceps muscles clinically had a normal strength although the total/severe involvement of some hamstrings and rectus femoris was revealed during the MRI and CT study. Also there was no full correlation between the muscle strength and the MRI and CT findings for the hamstrings, gastrocnemius and soleus muscles in some patients with final phenotypes. Asymmetry of the degree of affection in the same muscles on the right and left sides was evident.

Thus, our clinical, CT and MRI studies show that in the observed patients there are widespread involvements of the lower limb muscles. In this context, the inaccuracy of the term “facio-scapulo-humeral” or “facio-scapulo-peroneal” muscular dystrophy becomes evident. The name “facio-scapulo-limb muscular dystrophy, type 2 (FSLD2), descending with a “jump” with initial FSP or (F)SP phenotypes with 4q35 deletion, autosomal dominant” would be more correct (22).

The clinical peculiarities of FSLD2 are as follows:

1. Onset of the disease in childhood or in youth with a slight asymmetrical weakness or atrophy of some portions of separate (orbicularis oris offer) mimic muscles or with affection of individual mimic and shoulder girdle (posture abnormalities) muscles, simultaneously.
2. “Jumping” of muscle affections from the face, shoulder girdle to peroneal group (anterior tibial) of shins in the initial phase of the disease.
3. Presence of the FSP phenotype with a slight affection of the isolated mimic muscles (orbicularis oris or orbicularis oculi) or their parts for a long period of time.
4. Preservation of an upper arm (biceps brachii) muscle strength for a long period of time and involvement of these muscles in the dystrophic process, usually asymmetrical and to a slight degree, after appearance of the weakness of the individual lower limb (anterior tibial, posterior group of thigh) and the pelvic girdle (gluteus maximus) muscles and rarely - after a severe weakness of the peroneal group muscles.
5. Absence of the “pure” FSH and SH phenotypes of the muscle weakness.
6. Preservation of muscle strength during a very long period of erector spinae and absence of specific lumbar lordosis due to the weakness of these muscles, gluteus medius and absence of specific waddling gait due to the weakness of these muscles, and quadriceps femoris and absence of tendency to fall due to the weakness of these muscles.

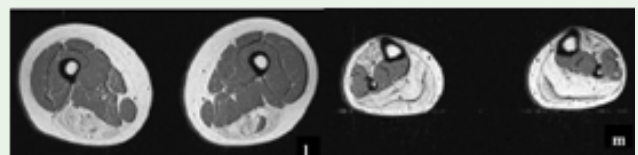


Figure 6 L-M: The same patient as a Figure 6 a-k at the age of 41.
 L. MRI of thigh muscles. Description thigh muscle.
 M. MRI of lower leg muscles. Description of lower leg muscles.

7. Mild course of the disease: the patients can walk almost all their life.

Discussion

We would like point out that some authors [13,23-27] who studied the Scapuloperoneal Dystrophy (SPD) or the Myogenic Scapuloperoneal Syndrome (MSPS) described sporadic cases usually at a certain stage of the disease without reexamination of these patients after many years in future. It is quite possible that among these patients the facial, posterior group of thigh and gluteus maximus muscles affection might appear later. Thus we suppose that these "sporadic" cases may correspond to the early stage in the development of FSLD2 assigned to 4q35 as well as other hereditary and sporadic SPD and MSPS patients in who the marked (or minimal) affection of mimic muscles was described (4,11,28 - 32). In some described patients the dystrophic process started in the foot extensors (3,4,11, 13), which is extremely unusual for FSLD2. However, on examination of some of these patients an asymptomatic weakness and atrophy of some shoulder girdle and facial muscles were found. We would like point out that some of our patients also supposed that the weakness of extensors of feet was the first symptom of the disease. However, our study shows that in FSLD2 patients an abnormal facial expression and posture of shoulder girdle may occur much earlier than the motor disorders perceptible by the patient [15,19,33].

We examined clinically and genetically the homogeneous group of the patients with FSLD2 connected with 4q35 chromosomal deletion ranging between 13-35 kb (double digestion). However, the classical FSHD (or FSLD1, gradually descending type with initial FSH phenotype – author's opinion) is associated as well with the 4q35-linked EcoRI fragment detected by p13E-11 which is usually shorter than 35 kb [2] or equal 38 kb or shorter [34]. Apparently, the 4q35 deletion is associated not only with classical FSHD (or FSLD1) but also with a FSLD2 as well as with other clinical presentations of FSHD [35-39]. Recently two homozygous patients of FSHD, who were no more severely affected than the heterozygous members of the family, have been described [40,41] and 20% individuals related to FSHD patients with 4q35 small chromosomal deletion remain asymptomatic or are minimally affected [40] and no clinical symptoms were seen in 52% parents who carried a small EcoRI fragment [42]. Similarly a pair of monozygous twins affected by FSHD who showed great variability in the clinical expression of the disease [43] and a pair of monozygous twins who were discordant for FSHD [44] was published. That is why the detected DFS cannot serve as a guideline for differentiation of FSLD2 from classical FSHD (or FSLD1) which we reported and published earlier [19].

It is possible that classical FSHD (or FSLD1-author's note) and classical SPD (or FSLD2-author's note) are the disorders resulted from the mutations in gene products that are encoded on different chromosomes [9,10]. However, an opinion exists that unrelated patients carrying the same mutation may show a discordant phenotype [45,46]. For example, mutations in the desmin, lamin A/C, caveolin-3, dysferlin and titin genes, respectively are known to cause several distinct phenotypes [45-50]. It is quite possible that classical FSHD (or FSLD1- author's note) and classical SPD (or FSLD2-author's note) are allelic diseases [51,52]. However, it should not

be ruled out that actually FSLD1 and FSLD2 are connected with the action of the same basic gene but different phenotypes may be due to an epigenic disease mechanisms changing familial gene pool [53,54].

The scapuloperoneal pattern of the muscle involvement with or without affection of the facial muscles occurs in a different of hereditary muscle diseases [48,55-57] (myopathies with acid maltase deficiency, with ragged red fibres and cardiomyopathy, with hyaline bodies, myofibrillar or desmin storage myopathy, centronuclear and nemaline myopathies) but these myopathies are not a (F) SP or FSP muscular dystrophy which differs greatly from them by characteristic static and dynamic pattern of muscle involvement and by chromosome 4q35 linked.

Conclusion

The data show that autosomal dominant FSLD2 (the same disease as a FSHD1) is a very special type of a muscular dystrophy with "hard" static and dynamic pattern of muscle weakness, with a mild course of the disease and a slight/severe and usually asymmetrical affection of the isolated facial muscles or their parts.

The FSLD2 (or FSHD1) begins from the face and shoulder girdle muscles weakness with subsequent involvement of the peroneal group (anterior tibial) muscles at the early stage. The muscles of the thigh (namely, posterior group) and pelvic girdle (namely, gluteus maximus) are involved much later and to a comparatively lesser degree than the muscles of the scapulo-peroneal region.

The scapuloperoneal phenotype with a slight affection of the isolated facial muscles which would be more correct to refer to as the (F)SP or the FSP phenotype) predominates in the clinical picture during many years and all these phenotypes constitute merely a stage in the development of FSLD2 (or FSHD1).

The biceps brachii muscle strength is preserved for a long period of time and the muscle is being involved in a dystrophic process, usually asymmetrical and to a slight degree, after appearance of the weakness of the individual lower limb (anterior tibial, posterior group of thigh) and pelvic girdle (gluteus maximus) muscles and rarely-after severe weakness of the peroneal group muscles.

In the early stage of FSLD2 (FSHD1) there is a peculiar clinical pattern of muscle affection including the upper part of orbicularis oris, lower part of trapezius and serratus anterior, sternal part of pectoralis major, latissimus dorsi, brachioradialis and tibialis anterior and preservation of iliopsoas, and especially of biceps and triceps brachii, quadriceps femoris, gluteus medius and gastrocnemius muscle strength (for a very long duration).

The probe p13E-11 can be used for detecting DFS between 13-35 kb (double digestion) for FSLD2 which are assigned to chromosome 4q35. FSLD2 (or FSHD1), descending type with a "jump, with initial FSP or (F)SP phenotypes is probably an independent form of muscular dystrophy which differs from classical FSHD (or FSLD1, gradually descending with initial FSH phenotype). It is quite possible that FSLD1 and FSLD2 (or FSHD1) are connected with the same gene mutation but they are presented by different phenotypes due to the action of different modifier genes. However, we can assume as well that FSLD1 is connected with some other basic gene than FSLD2 (or FSHD1) and that it is not linked with the chromosome 4q35.

Acknowledgment

The authors are grateful to Drs. K. Arahata† and H. Sugita and Ms. K. Goto for molecular genetic testing of the DNA samples and to the Japanese Research Fund and Japan Foundation for Aging and Health for the support of this study.

References

- Brooke MH. Facioscapulohumeral dystrophy. Scapuloperoneal dystrophy. In: Brooke MH, editor. *A Clinician's View of Neuromuscular Diseases*. Baltimore: Williams & Wilkins. 1986; 158-174.
- Padberg GW. Facioscapulohumeral muscular dystrophy. In: Emery AEH. *Neuromuscular disorders: clinical and molecular genetics*. Chichester: John Wiley & Sons. 1998; 105-121.
- Serratrice G, Pellissier JF, Pouget J, Gastaut JL, Cros D. Les syndromes scapulo-péroniers: *Rev Neurol (Paris)*. 1982; 138: 691-711.
- Serratrice G, Roux H, Aquaron R, Gambarelli D, Baret J. Myopathies scapulo-peronieres. A propos de 14 observations dont 8 avec atteinte faciale. *Sem Hop (Paris)*. 1969; 45: 2678-2683.
- Walton J, Gardner-Medwin D. The facioscapulohumeral (FSH) muscular dystrophy. Autosomal dominant scapuloperoneal myopathy. In: Walton J editor. *Disorders of Voluntary Muscle (5th ed)*, Edinburg: Churchill Livingstone. 1988; 551-554.
- Becker PE. Myopathien. In: Becker PE editor. *Humangenetik*, Stuttgart: G. Thieme. 1964; III: 411-550.
- Carroll JE. Facioscapulohumeral and scapuloperoneal syndromes. In: Vinken P J, Bruyn G W editors. *Handbook of Clinical Neurology: Diseases of Muscle*, Amsterdam: North-Holland. 1979; 40: 415-431.
- Munsat TL, Serratrice G. Facioscapulohumeral and scapuloperoneal syndromes. In: Rowland L P, DiMauro S editors. *Handbook of Clinical Neurology, Myopathies*. Amsterdam: Elsevier Science. 1992; 18: 161-177.
- Rowland LP. Molecular genetics and clinical neurology: Allelic heterogeneity, locus heterogeneity, gene-defining mutations and clinical syndromes. *Acta Cardiomiol*. 1996; VIII: 41-51.
- Tawil R, Myers GJ, Weiffenbach B, Griggs RC. Scapuloperoneal syndromes. Absence of linkage to the 4q35 FSHD locus. *Arch. Neurol*. 1995; 32: 1069-1072.
- Thomas PK, Schott GD, Morgan-Hughes JA. Adult onset scapuloperoneal myopathy. *JNNP*. 1975; 38: 1008-1015.
- Zellweger H, McCormick WF. Scapuloperoneal dystrophy and scapuloperoneal atrophy. *Helv paediat. Acta*. 1968; 23: 643-649.
- Lovelace RE, Menken M. The scapulo-peroneal syndrome (dystrophic type). *Int Congr Ser*. 1969; 193: 247-248.
- Goto K, Lee JEH, Matsuda C, Hirabayashi K, Kojo T, Nakamura A, et al. DNA rearrangements in Japanese facioscapulohumeral muscular dystrophy patients: clinical correlations. *Neuromusc Disord*. 1995; 5: 201-208.
- Kazakov VM. *Facio-scapulo-humeral myodystrophy (clinic and genetic)*, thesis Pavlov Medical Institute Leningrad. 1971.
- Daniels L, Williams M, Worthingham C. *Muscle testing. Techniques of manual examination*. 2nd edn. Philadelphia: Saunders. 1956.
- Kendall HO, Kendall FM. *Muscles, Testing and Function*. Baltimore: Williams & Wilkins. 1949.
- Kazakov VM, Rudenko DI. Clinical variability of facioscapulohumeral muscular dystrophy in Russia. *Muscle & Nerve*. 1995; 2: S85-S95.
- Kazakov V, Rudenko D, Katsev E, Sugita H et al. Facioscapulohumeral muscular dystrophy (facioscapuloperoneal form of FSHD) in Russian families. Phenotype/genotype correlations. *Acta Myologica*. 2000; XIX: 69-79.
- Hawley RJ, Schellinger D, O'Doherty DS. Computed tomographic patterns of muscles in neuromuscular diseases. *Arch Neurol*. 1984; 41: 383-387.
- Jungbluth H, Davis MR, Muller C, et al. Magnetic resonance imaging of muscle in nemaline myopathy. *Neuromusc Disord*. 2004; 14: 779-784.
- Kazakov V. History of the recognition and description of the Facioscapulohumeral muscular dystrophy (FSHD) and on the priorities of Duchenne, Erb, Landouzy and Dejerine. *Acta Cardiomiol*. 1995; VII: 79-94.
- Amici R, Caraceni T, Negri S. Su di un caso familiare di miopatia scapulo-tibio-peroneale tardiva. *Sist nerv*. 1966; 18: 327-335.
- Ando K, Sobue J. A variant of progressive muscular dystrophy. Scapulo-peroneal type. *Mod Med (Osaka)* 1962; 37: 1411-1415.
- Delwaide PJ, Schoenen J. Atrophie scapulo-peroniere sporadique d'origine myogene. *Rev Neurol (Paris)*. 1976; 132: 424-429.
- Hausmanowa-Petrusewicz I, Zielinska St. Zur nosologischen Stellung des scapulo-peronealen Syndroms. *Dt Z NervHeilk*. 1962; 183: 377-382.
- Seitz D. Zur nosologischen Stellung des sogenannten scapuloperonealen Syndroms. *Dt Z NervHeilk*. 1957; 175: 547-552.
- Oransky V. Über einer hereditären Typus progressiven Muskeldystrophie. *Dt Z NervHeilk*. 1927; 99: 147-155.
- Pou-Serradell A, Royo I, Lopez dr Munain A, Camano P. Familial late-onset of shoulder and ankle dorsiflexors weakness related to 4q35 chromosome deletion: Unusual phenotype of FSHD. *Acta Myologica* 2004; XXIII: 63.
- Ricker K, Mertens HG. The differential diagnosis of the myogenic (facio)-scapulo-peroneal syndrome. *Eur Neurol*. 1969; 1: 275-307.
- Voiculescu V, Cheorghiu M, Gabor S. Miopatie facio-scapulo-peroneala. *Neurol Psihiatr Neurochirurg*. 1970; 15: 315-323.
- Zeevaert B, Sadzot B, Deprez M, Wang FC. Scapulo-peroneal weakness with tardive symptoms of facio-scapulo-humeral muscular dystrophy, connected to 4q35 chromosomal deletion. *Rev Neurol (Paris)*. 2002; 158: 1210-1213.
- Kazakov V. Affection of mimic muscles, simulating damage of the facial nerve in patients with facioscapulohumeral muscular dystrophy. *Eur Arch Otorhinolaryngology*. 1994; S96-S101.
- Orrell RW, Griggs RC. Muscular dystrophies: Overview of clinical and molecular approaches. In: Shapira AHV, Griggs RC editors. *Muscle Diseases*, Boston: Butterworth Heinemann. 1999; 59-82.
- Butz M, Koch MC, Muller-Felber W, Lemmers RJ, van der Maarel SM, Schreiber H. Facioscapulohumeral muscular dystrophy. Phenotype-genotype correlation in patients with borderline D4Z4 repeat numbers. *J Neurol*. 2003; 250: 932-937.
- Felice KJ, Moore SA. Unusual clinical presentations in patients harboring the facioscapulohumeral dystrophy 4q35 deletion. *Muscle Nerve*. 2001; 24: 352-356.
- Van der Kooij A J, Visser M C, Rosenberg N, et al. Extension of the clinical range of facioscapulohumeral dystrophy: report of six cases. *JNNP*. 2000; 69: 114-146.
- Krasnianski M, Eger K, Neudecker S, Jakubiczka S, Zierz S. Atypical phenotypes in patients with facioscapulohumeral muscular dystrophy 4q35 deletion. *Arch Neurol*. 2003; 60: 1421-1425.
- Krasnianski M, Neudecker S, Eger K, Schulte-Mattler W, Zierz S. Facioscapulohumeral muscular dystrophy. The spectrum of clinical manifestations and molecular genetics changes. *Nervenarzt*. 2003; 74: 151-158.
- Tonini MMO, Pavanello RCM, Gurgel-Giannetti J Lemmers RJ, van der Maarel SM, Frants RR, et al. Homozygosity for autosomal dominant facioscapulohumeral muscular dystrophy (FSHD) does not result in a more severe phenotype. *J. Med. Genet*. 2004; 41: e17.

Citation: Kazakov VM, Rudenko DI, Kolynin VO, Stuchevskaya TR and Skoromets AA. The Autosomal Dominant Facio-Scapulo-Limb Type 2 (The Same Disease as the FSHD1 or the Facioscapuloperoneal Muscular Dystrophy with 4q35 Chromosomal Deletion). Some Peculiarities of the Pattern of Muscle Involvement. *SM Musculoskelet Disord*. 2018; 3(1): 1024. <https://dx.doi.org/10.36876/smmd.1024>

41. Canki-Klain M, Zagar M, Lannoy C. et al. Homozygosity for facioscapulohumeral muscular dystrophy (FSHD) gene. *Neuromusc Disord.* 2001; 11: 634-635.
42. Goto K, Nishino I, Hayashi Y K. Very low penetrance in 85 Japanese families with facioscapulohumeral muscular dystrophy 1A. *J Med Genet.* 2004; 41: e12.
43. Griggs R, Tawil R, McDermott M Forrester J, Figlewicz D, Weiffenbach B. Monozygotic twins with facioscapulohumeral dystrophy (FSHD): implications for genotype/phenotype correlation. *Muscle Nerve Suppl.* 1995; 2: S50-S55.
44. Tupler R, Barbierato L, Memmi M, Sewry CA, De Grandis D, Maraschio P, et al. Identical de novo mutation at the D4F104S1 locus in monozygotic male twins affected by facioscapulohumeral muscular dystrophy (FSHD) with different clinical expression. *J Med Genet.* 1998; 35: 778-783.
45. Emery AEH. Muscular dystrophy into new millennium. *Neuromusc Disord.* 2002; 12: 343-349.
46. Zatz M, Vainzof M, Passos-Bueno MR. Limb-girdle muscular dystrophy: one gene with different phenotypes, one phenotype with different genes. *Curr Opin Neurol.* 2000; 13: 511-517.
47. Bushby KM. Making sense of the limb-girdle muscular dystrophies. *Brain.* 1999; 122: 1403-1420.
48. Goldfarb LG, Vicart P, Goebel HH, Dalakas M C. Desmin myopathy. *Brain.* 2004; 127: 723-734.
49. Aboumoussa A, Hoogendijk J, Charlton R. et al. Caveolinopathy-New mutations and additional symptoms. *Neuromusc Disord.* 2008; 18: 572-588.
50. Hackman P, Marchand S, Sarparanta J, Vihola A, Péniisson-Besnier I, Eymard B, et al. Truncating mutations in C-terminal titin may cause more severe tibial muscular dystrophy (TMD). *Neuromuscul Disord.* 2008; 18: 922-928.
51. Jardine PE, Upadhyaya M, Maynard J, Harper P, Lunt PW. A scapular onset muscular dystrophy without facial involvement: possible allelism with facioscapulohumeral muscular dystrophy. *Neuromuscul Disord.* 1994; 4: 477-482.
52. Fisher J, Upadhyaya M. Molecular genetics of facioscapulohumeral muscular dystrophy (FSHD). *Neuromusc. Disord.* 1997; 7: 55-62.
53. Petrov A, Laoudj D, Vassetzky ES. Genetics and epigenetics of progressive facioscapulohumeral (Landouzy-Dejerine) muscular dystrophy. *Genetica.* 2003; 39: 147-151.
54. van Overveld PG, Enthoven L, Ricci E, Rossi M, Felicetti L, Jeanpierre M, et al. Variable hypomethylation of D4Z4 in facioscapulohumeral muscular dystrophy. *Ann Neurol.* 2005; 58: 569-576.
55. Selcen D, Ohno K, Engel AG. Miofibrillar myopathy: clinical, morphological and genetic studies in 63 patients. *Brain.* 2004; 127: 439-451.
56. Serratrice G, Pellissier JF, Bes A, Arne-Bes MC. Un cas de myopathie centro-nucléaire de l'adulte de topographie facio-scapulo-péronière. *Rev. Neurol. (Paris).* 1987; 143: 693-697.
57. Wilhelmssen KC, Blake DM, Lynch T, Mabutis J, De Vera M, Neystat M, et al. Chromosome 12-linked autosomal dominant scapuloperoneal dystrophy. *Ann Neurol.* 1996; 39: 507-520.