SMGroup

SM Journal of Nephrology and Therapeutics

Research Article

Challenges of Laparoscopic Peritoneal Dialysis Catheter Placement in the Hostile Abdomen

Mamatha Gandhi[1], Katherine M. Dokus[2], Saman S. Safadjou[2], Scott E. Liebman[3] and Randeep Kashyap[2]*

[1]*Southern Kidney Care, USA*

[2]*Department of Surgery, Division of Solid Organ Transplantation, University of Rochester Medical Center, USA*

[3]*Department of Internal Medicine, Division of Nephrology, University of Rochester Medical Center, USA*

Article Information

Received date: Aug 05, 2016
Accepted date: Nov 03, 2016
Published date: Nov 13, 2016

***Corresponding author**

Randeep Kashyap, 601 Elmwood Ave, Box Surg-Txp, Rochester, NY 14642, Tel: 585-275-5875; Fax: 585-276-2182; Email: Randeep_Kashyap@urmc.rochester.edu

Keywords Peritoneal dialysis; Laparoscopic surgery; Malfunction; Infection

Abbreviations AV: Arteriovenous Fistula; ESI: Exit Site Infection; ESRD: End-stage Renal Disease; ISPD: International Society for Peritoneal Dialysis; PD: Peritoneal Dialysis; USRDS: United States Renal Data System

Article DOI 10.36876/smjnt.1004

OPEN ACCESS

ISSN: 2573-3613

Abstract

Background: Peritoneal Dialysis (PD) is an effective method of renal replacement therapy whose popularity in the United States is likely to increase with the advent of health care reform. Laparoscopic surgery is one method of PD catheter placement and though not conclusive, some data suggest that laparoscopic placement is safer and confers better outcomes than the alternatives.

Methods: Here, we describe our experience with laparoscopic PD catheter placement through a retrospective case review. A total of 108 patients underwent the procedure at our center between January 2007 and July 2010. Seventy-five of these patients had at least one year of follow-up (median 14.5 months) and were included for analysis of catheters survival and outcomes. Intra-operative and catheter related complications as well as catheter survival are calculated for this cohort, also included is a case series focused on PD catheter placement in "hostile abdomens".

Results: We experienced a 77.3% one year catheter survival rate. Reasons for removal included infection, leak, and malfunction. No significant difference in survival was seen between patients who had undergone previous abdominal surgeries and those with virgin abdomens. Highlighted cases include successful and unsuccessful placement in patients with previous abdominal surgery, cases which required concomitant procedures such as adhesiolysis, omentectomy, and omentopexy, salvage, as well as unique experience with a previous non-renal solid organ transplant case.

Conclusions: Overall, we found laparoscopy to be safe and effective method of PD catheter placement, particularly in the "hostile abdomen", and recommend broader adoption of this technique given the proper circumstance.

Introduction

Peritoneal Dialysis (PD) is an established modality of renal replacement. As per the 2015 United States Renal Data System (USRDS) annual report, there are 45,258 patients currently on PD in the US [1]. PD is less utilized in the United States than in other parts of the world; the reason for this disproportionate utilization is multi-factorial, but includes availability of infrastructure including surgical expertise [2]. Home based dialysis including PD may garner greater prominence in the era of health care reform, where improving access to patient-centered care is paramount and cost effectiveness will direct reimbursement [3,4]. There is, however, a growing need for better and safer PD catheter placement techniques.

There are various surgical methods for PD catheter placement. Laparoscopic assisted PD catheter placement is fast gaining popularity as it may be safer and more cost effective with shorter length of stay and less patient discomfort [5-8]. It also allows for procedures which may improve catheter survival and function, such as omentectomy, omentopexy and adhesiolysis to be performed concomitantly [9-11]. Laparoscopic salvage techniques also help in prolonging catheter lifespan [12]. Here we report our experience in laparoscopic PD catheter placement at our center.

Methods

We retrospectively reviewed patients who underwent laparoscopic PD catheter placement at our center. Demographics and clinical information from both inpatient and outpatient stays were collected via chart review and used for analysis. Demographics were summarized as means for continuous variables and proportions for dichotomous ones. Catheter survival analysis was done using the Kaplan-Meier technique, cases were censored if the catheter was removed electively (i.e. due to change in renal replacement modality or transplantation). Cases with at least one year of follow up were included for demographic and survival analyses. Individual cases for review were selected to highlight the challenges of PD catheter placement in a hostile abdomen. This study was approved by our center's internal review board.

How to cite this article Mamatha G, Katherine DM, Saman SS, Scott EL and Randeep K. Challenges of Laparoscopic Peritoneal Dialysis Catheter Placement in the Hostile Abdomen. SM J Nephrol Therap. 2016; 1(1): 1004.
https://dx.doi.org/10.36876/smjnt.1004

Table 1: Socio-demographic characteristics of patients (n=75).

Characteristic	Frequency
Sex (Male)	35 (46.7%)
Race (African American)	25 (33.3%)
Diagnosis	
DM	26 (34.7%)
Glomerulonephritis	18 (24.0%)
HTN Nephrosclerosis	10 (13.3%)
PCKD	5 (6.7%)
Others	15 (20.0%)
Unknown	1 (1.3%)

DM: Diabetes Mellitus; HTN: Hypertension; PCKD: Polycystic Kidney Disease; PD: Peritoneal Dialysis.

Surgical Technique

Laparoscopic two port technique for placement of PD catheter was used in a majority of the cases. The majority of cases were performed by a single surgeon. Before the incision is made, the catheter is placed on the abdomen, away from the belt line, to mark the exit site intra-operatively and prophylactic antibiotics (Cefazolin) are given. A small 5 mm incision is made in the right upper quadrant of the abdomen through which a Veress needle is passed and pneumoperitoneum established. The camera is then introduced under vision through the visiport, allowing visualization through the port as it as advanced through the layers of the abdominal wall into the peritoneal cavity. The abdomen can then be inspected for any problem that could compromise catheter function such as undiagnosed hernia, redundant omentum or adhesions. Next, a 1cm transverse paramedian incision is made at the predetermined site, the rectus sheath is exposed and a pinpoint hole is made with the help of diathermy. The Veress needle is pushed in a perpendicular fashion, sliding the blunt end of the needle towards the pelvis creating a preperitoneal tunnel. After the needle is removed, a dilator is introduced through the expandable sleeve and the catheter is introduced completing the catheter port insertion. Single or double cuff Tenckhoff catheters were used based on the surgeon's preference. Air bubbles are squeezed from the Dacron cuff to promote better tissue in growth. The catheter stylette complex assembly is then introduced and trocar removed. The internal cuff lies in the preperitoneal tunnel and external cuff in the subcutaneous tissue. A subcutaneous tunnel is then fashioned and catheter is brought out of the exit site. Finally, the titanium adaptors are attached to connect to the transfer set. A liter of saline is flushed through the catheter to check inflow and outflow. Incisions are closed with 4-0 monocryl in subcuticular fashion and sterile dressings applied.

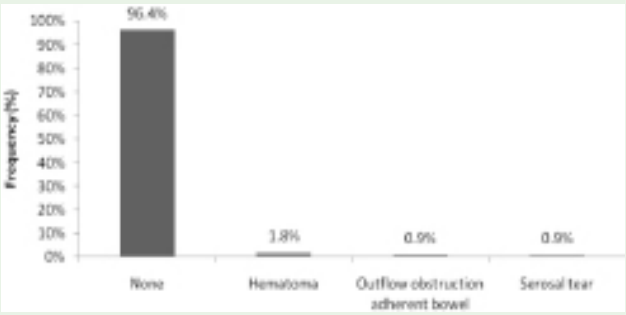

Figure 1: Type and frequency of surgical complication.

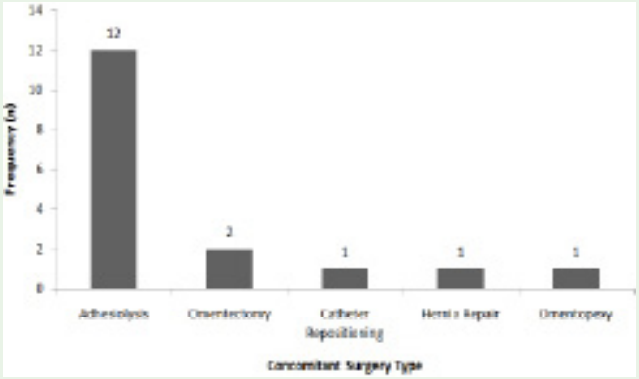

Figure 2: Type and frequency of concomitant surgery.

Results

Over a two and a half year period, 108 patients underwent laparoscopic peritoneal dialysis catheter placement at our institution. Surgical complications are described for all procedures.

Post-operative complications were seen in 3.6% of the patients immediately after surgery. Complications noted (Figure 1) were two operative site hematomas that required surgical drainage; one serosal tear managed conservatively and one patient experienced outflow obstruction from a small bowel adhesion requiring revision. Infective complications within 2 weeks of catheter placement included two episodes of peritonitis (1.9%) and an Exit Site Infection (ESI) (0.9%). The median time to start of peritoneal dialysis after catheter placement was 3.3 weeks.

Seventy-five patients had at least one year of follow-up (Table 1); 30 patients were lost to follow-up, 3 were transplanted. Twenty-five (33.3%) had undergone previous abdominal surgery (28% urological, 40 % GI and 32% gynecological); three (12%) of these patients required adhesiolysis at the time of PD catheter placement. Other concomitant procedures (Figure 2) included an omentopexy and two omentectomies. One patient underwent hernia repair at the time of catheter placement.

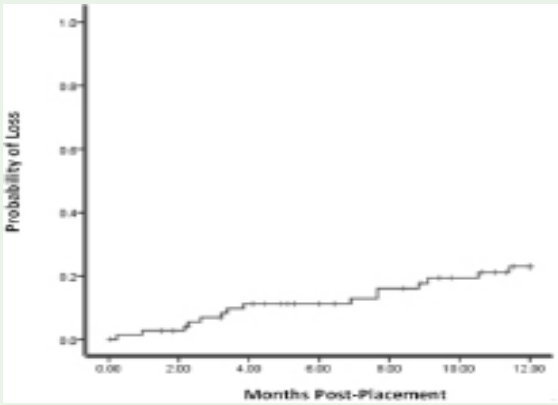

Figure 3: Probability of catheter loss (K-M).

Citation: Mamatha G, Katherine DM, Saman SS, Scott EL and Randeep K. Challenges of Laparoscopic Peritoneal Dialysis Catheter Placement in the Hostile Abdomen. SM J Nephrol Therap. 2016; 1(1): 1004.
https://dx.doi.org/10.36876/smjnt.1004

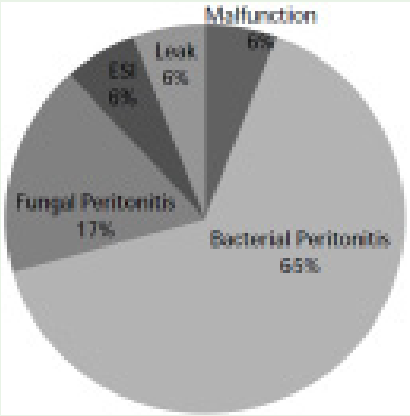

Figure 4: Causes for catheter removal.

Median follow-up for this group was 14.5 months; catheter survival at one year was 77.3% (Figure 3).Of the seventeen catheters removed in the follow up period, 14 were due to peritonitis (21% fungal and 79% from recurrent bacterial infection). Bacterial organisms consisted of methicillin-sensitive Staphylococcus aureus (n=5), coagulase-negative Staphylococcus aureus (n=3), vancomycin-resistant Enterococcus (n=1), Klebsiella pneumonia (n=1), and Klebsiella Oxytoca (n=1). Fungal species causing peritonitis were Candida albicans (n=2) and Candida parapsilosis (n=1). One catheter each was removed for ESI, leak, and malfunction (Figure 4). We looked at catheter survival over duration of 12 months in patients with previous abdominal surgeries versus those with a virgin abdomen (73.7% *vs*. 84%) and did not note a statistical difference (p=0.368).

Selected Cases Highlighting the Challenges of Placing PD Dialysis Catheters in a Hostile Abdomen are described below

Case Discussion

Case 1: A 77-year-old female with history of previous exploratory laparotomy for colorectal cancer with ESRD: The patient's abdominal cavity was visualized laparoscopically and dense adhesions were noted not only in the abdominal cavity but also in the pelvis and right lower quadrant, precluding the placement of the PD catheter. This case highlights the utility of utilizing laparoscopy in visualizing the abdomen with expected scarring. Done blindly it may have resulted in catheter failure and patient morbidity.

Case 2: A 22-year-old with a previous open PD catheter placement, a failed renal transplant and subsequent allograft nephrectomy on hemodialysis opted to switch back to peritoneal dialysis: Given the history of previous abdominal and pelvic surgery successful placement of a PD catheter was questionable. On laparoscopic visualization dense intra-abdominal adhesions were noted and adhesiolysis was done. We elected to proceed with PD catheter placement, however the catheter malfunctioned. Subsequent revision revealed adhesions of the small bowel omentum and abdominal wall likely leading to an inadequate surface area for exchange. The catheter was removed a month after its placement. This case highlights that an attempt at adhesiolysis can be with laparoscopic PD catheter placement, although this may not always succeed in the hostile abdomen.

Case 3: A 73-year-old man with previous history of renal transplant with a failed allograft and previous abdominal surgeries including cholecystectomy and colectomy desired to be on peritoneal dialysis: Laparoscopic visualization of the abdomen showed scarring in the upper abdomen and midline however the pelvis was free of adhesions. The PD catheter was placed with the tip in the pelvis. There were no complications and the catheter functioned well. The adhesiolysis of the upper abdominal scarring allowed for successful PD catheter placement highlighting the utility of laparoscopy in this case.

Case 4: A 30-year-old patient with a previous renal transplant and a failed allograft had catheter malfunction that was noted three months after placement. Imaging studies revealed catheter obstruction. Laparoscopic evaluation showed omental wrapping and a fibrin clot at the tip of the catheter. The catheter was freed from the omentum and the guide wire was passed to remove the fibrin clot and subsequently the catheter was repositioned back in the pelvis. This case highlights the utility of laparoscopic techniques in catheter salvage without having to stop peritoneal dialysis. Omentectomy or omentopexy was not necessary in this case however would have been utilized if indicated.

Case 5: A previously published case report from our center [13], of a 42-year-old patient on CCPD for 10 years presented to the emergency department with an acute abdomen, fever and chills and difficulty with catheter outflow for the last 2 months. Examination revealed signs of peritonitis with no break in the catheter. Contrast enhanced CT showed a doubtful discontinuity in the catheter with a pericatheter leak on contrast study. The patient was taken to the OR and carbon dioxide insufflation of the PD catheter resulted in the leak of gas in the subcutaneous tissue. A pericatheter incision was made and dissection into the subcutaneous tissues revealed that the catheter was transected in 2 parts with the proximal and distal ends of the broken catheter communicating via a fibrous tissue tract. The proximal part of the catheter was removed through this incision however the distal portion had to be removed laparoscopically as it could not be visualized. A new PD catheter was placed through a separate incision. Laparoscopic technique allowed concomitant catheter removal and placement.

Case 6: A 43-year-old male on peritoneal dialysis for the last 2 years presented with peritonitis and was found to have yeast on culture: He was taken to the OR and the abdomen was visualized prior to catheter removal. We noted small bowel obstruction with significant adhesions and pockets off intra-abdominal fluid. The peritoneum was inflamed and congested. The PD catheter was removed and an AV fistula was subsequently placed. The extensive scarring and congested peritoneum noted in this patient's abdomen under laparoscopic visualization made it clear that this patient would not be a candidate for PD catheter placement in the future.

Case 7: A 56-year-old morbidly obese patient with end-stage renal disease secondary to diabetes: Due to very poor peripheral veins, she was not a good candidate for long-term hemodialysis access. The patient opted for peritoneal dialysis, and underwent laparoscopic placement of a PD catheter. Intra-operatively, we noted generous amount of omentum necessitating omentectomy and omentopexy to allow for good catheter function.

Citation: Mamatha G, Katherine DM, Saman SS, Scott EL and Randeep K. Challenges of Laparoscopic Peritoneal Dialysis Catheter Placement in the Hostile Abdomen. SM J Nephrol Therap. 2016; 1(1): 1004.
https://dx.doi.org/10.36876/smjnt.1004

Case 8: A 56-year-old male with history of liver transplant for hepatitis C with ESRD from Type-2 diabetes: Previous extensive abdominal surgery made the patient a questionable candidate for peritoneal dialysis. Through laparoscopic visualization of the abdomen, minimal upper abdominal scarring with an adhesion-free pelvic cavity was noted. The peritoneal dialysis catheter was successfully placed in this patient, highlighting the usefulness of laparoscopic evaluation of the abdomen to allow for effective catheter placement in patients with previous abdominal solid organ transplants.

Discussion

There are several techniques for PD catheter placement including blind insertion, open surgical placement (mini laparotomy) and laparoscopic placement. There are no data demonstrating the superiority of any one method [14]. Blind insertion is associated with an increased risk of visceral perforations and catheter tip migration [15,16]. Open placement, when performed well, is safe and effective, but a history of previous abdominal surgeries is often considered a relative contraindication due to adhesions. Adhesions complicate 60-70% of intra-abdominal surgeries and can cause compartmentalization of the abdominal cavity and limit the surface area available for peritoneal dialysis [17]. The lack of visualization can produce kinking, mal-positioning and blockage resulting in catheter malfunction [18]. The inability to visualize the peritoneal cavity makes catheter salvage procedures difficult resulting in reduced catheter survival.

Our experience has shown that laparoscopic PD catheter placement is safe, effective and associated with a low complication rate. The rates for ESI, peritonitis and catheter malfunction in our center met or exceeded the recommendations of the ISPD guidelines [19]. In addition, laparoscopic procedure has allowed catheter placement in patients who were previously not considered to be PD candidates.

With laparoscopy, one can overcome some of the limitations of a hostile abdomen. Laparoscopic techniques provide adequate visualization of the peritoneal cavity, potentially making this a safer option, particularly in patients with previous abdominal surgery (Cases 1-3,6,8). Concomitant procedures such as adhesiolysis allows placement of catheters in patients who were previously considered poor PD candidates (Case 3) [20,21]. Catheter obstruction, omental wrapping and tip migration often need catheter removal and replacement. Laparoscopy allows catheter salvage procedures such as omentopexy, omentectomy, fixation and adhesiolysis. These procedures prolong catheter survival and prevent malfunction [10,11,22,23]. Another advantage is that patients can undergo these salvage procedures while continuing peritoneal dialysis (case 4). Laparoscopic procedures can overcome some of the challenges of placement presented with obesity; omentopexy and omentectomy done at the time of PD catheter placement has demonstrated better catheter survival and improved patient outcomes in some centers [10,23-25] (Case 7).

Patients with previous solid organ transplants, such as case eight offer both a challenge and an opportunity. The incidence of ESRD in this population is on the rise, up to 29% in one series; and is primarily the result of calcineurin inhibitor toxicity [26]. Peritoneal dialysis is an underutilized modality in this population due to concerns for increased infection risk and poor technique survival. A recent retrospective observational study has shown that home based dialysis including PD is safe in this population [27,28]. The technical concern is that previous extensive abdominal surgery would result in a "hostile abdomen" making PD catheter placement a challenge. Laparoscopic visualization, however, can allow direct assessment of the abdominal cavity and catheter placement in the pelvis.

Health care reform in the United States will likely favor home based dialysis therapy and one can anticipate that PD will become more popular. One challenge to increasing this mode of renal replacement therapy is providing adequate training for surgical residents and fellows in the art of PD catheter placements and catheter salvage techniques. A recent survey by Wong etal. assessed surgical resident training for peritoneal dialysis catheter placement. The authors found that only 30% of centers surveyed utilized laparoscopy as the predominant PD catheter placement technique. They conclude that although training was provided, it appears to be inadequate and predominantly limited by lack of cases. The authors address the need to develop better initiatives between nephrologists and surgeons to increase referral. [29]. Better education initiatives to make patients aware of this dialysis modality, alongside training and referral efforts will play a crucial role in expanding the use of PD.

Limitations of the study include a small patient population at a single center, with no control group and limited length of follow-up. However, most included patients are dialyzed at our center, promoting complete records with limited loss to follow up.

Conclusion

The cases at our center demonstrate laparoscopic PD catheter placement to be safe and effective. This technique is particularly effective at placing catheters in the "hostile abdomen". It may be the preferred option in challenging situations such as patients with a history of previous abdominal surgery, liver transplantation and obesity. It is the technique of choice for catheter salvage procedures like omentectomy and omentopexy, allowing for better catheter survival and reducing the chance of malfunction. Our center has begun offering PD to liver transplant recipients and placing these catheters under laparoscopic guidance given the adhesions and scarring associated with previous extensive abdominal surgery. Continued initiatives to increase referrals will enable surgical training of residents, fellows and interventionalists in honing this skill. Our experience suggests that more centers should adopt laparoscopic placement of PD catheters, though ultimately the choice of catheter placement technique will depend on surgical expertise and must be individualized to the patient to give the best chance of success with the least risk.

References

1. System, U.R.D., USRDS 2015 Annual Data Report: Atlas of Chronic Kidney and End-Stage Renal Disease in the United States. 2015, National Institutes of Health, National Institute of Diabetes and Digestive Kidney Diseases: Bathesda, MD.
2. McLaughlin K, Jones H, Carmen VS, Cynthia M, Marilyn V, Ken T, et al. Why do patients choose self-care dialysis? Nephrology Dialysis Transplantation. 2008; 23: 3972-3976.
3. Knauf F, Aronson PS. ESRD as a window into America's cost crisis in health care. J Am Soc Nephrol. 2009; 20: 2093-2097.

Citation: Mamatha G, Katherine DM, Saman SS, Scott EL and Randeep K. Challenges of Laparoscopic Peritoneal Dialysis Catheter Placement in the Hostile Abdomen. SM J Nephrol Therap. 2016; 1(1): 1004.
https://dx.doi.org/10.36876/smjnt.1004

4. Kocher R, Emanuel EJ, DeParle NA. The Affordable Care Act and the future of clinical medicine: the opportunities and challenges. Ann Intern Med. 2010; 153: 536-539.

5. Schmidt SC, Pohle C, Langrehr JM, Schumacher G, Jacob D, Neuhaus P. Laparoscopic-assisted placement of peritoneal dialysis catheters: implantation technique and results. J Laparoendosc Adv Surg Tech A. 2007; 17: 596-599.

6. Lu CT, Watson DI, Elias TJ, Faull RJ , Clarkson AR, Bannister KM. Laparoscopic placement of peritoneal dialysis catheters: 7 years experience. ANZ J Surg. 2003; 73: 109-111.

7. Jwo SC, Chen KS, Lee CC, Chen HY. Prospective randomized study for comparison of open surgery with laparoscopic-assisted placement of Tenckhoff peritoneal dialysis catheter--a single center experience and literature review. J Surg Res. 2010; 159: 489-496.

8. Yang PJ, Lee CY, Yeh CC, Nien HC, Tsai TJ, Tsai MK. Mini-laparotomy implantation of peritoneal dialysis catheters: outcome and rescue. Perit Dial Int. 2010; 30: 513-518.

9. Ogunc G. Minilaparoscopic extraperitoneal tunneling with omentopexy: a new technique for CAPD catheter placement. Perit Dial Int. 2005; 25: 551-555.

10. Crabtree JH, Fishman A. Selective performance of prophylactic omentopexy during laparoscopic implantation of peritoneal dialysis catheters. Surg Laparosc Endosc Percutan Tech. 2003; 13: 180-184.

11. Goh YH. Omental folding: a novel laparoscopic technique for salvaging peritoneal dialysis catheters. Perit Dial Int, 2008; 28: 626-631.

12. Ogunc G. Malfunctioning peritoneal dialysis catheter and accompanying surgical pathology repaired by laparoscopic surgery. Perit Dial Int. 2002; 22: 454-462.

13. Shaleen A, Mamatha G, Randeep K, Scott L. Spontaneous rupture of a silicone peritoneal dialysis catheter presenting outflow failure and peritonitis. Peritoneal Dialysis International, 2011; 31: 204-206.

14. Strippoli GF, Tong A, Johnson D, Schena FP, Craig JC. Catheter type, placement and insertion techniques for preventing peritonitis in peritoneal dialysis patients. Cochrane Database Syst Rev. 2004.

15. Rall KL, Beagle CL. Inadvertent Puncture of the Urinary Bladder by a Peritoneal Dialysis Catheter. South Med J. 1993; 86: 1398-1399.

16. Simkin EP, Wright FK. Perforating injuries of the bowel complicating peritoneal catheter insertion. Lancet, 1968; 7533: 64-66.

17. Liakakos T, Thomakos N, Fine PM, Dervenis C, Young RL. Peritoneal adhesions: Etiology, pathophysiology, and clinical significance. Recent advances in prevention and management. Dig Surg. 2001; 18: 260-273.

18. Crabtree JH. Previous abdominal surgery is not necessarily a contraindication for peritoneal dialysis. Nat Clin Pract Nephrol. 2008; 4: 16-17.

19. Figueiredo A, Goh BL, Jenkins S, Johnson DW, Mactier R, Ramalakshmi S, et al. Clinical practice guidelines for peritoneal access. Perit Dial Int. 2010; 30: 424-429.

20. Crabtree JH, Burchette RJ. Effect of prior abdominal surgery, peritonitis, and adhesions on catheter function and long-term outcome on peritoneal dialysis. Am Surg. 2009; 75: 140-147.

21. Keshvari A, Fazeli MS, Meysamie A, Seifi S, Taromloo MK. The effects of previous abdominal operations and intraperitoneal adhesions on the outcome of peritoneal dialysis catheters. Perit Dial Int. 2010; 30: 41-45.

22. Lee M, Donovan JF. Laparoscopic omentectomy for salvage of peritoneal dialysis catheters. J Endourol. 2002; 16: 241-244.

23. Ogunc G, Tuncer M, Ogunc D, Yardimsever M, Ersoy F, et al. Laparoscopic omental fixation technique versus open surgical placement of peritoneal dialysis catheters. Surg Endosc. 2003; 17: 1749-1755.

24. Chen WM, Cheng CL. A simple method to prevent peritoneal dialysis catheter tip migration. Perit Dial Int. 2007; 27: 554-556.

25. Liu WJ, Hooi LS. Complications after tenckhoff catheter insertion: A single-centre experience using multiple operators over four years. Perit Dial Int. 2010; 30: 509-512.

26. Ojo AO, Held PJ, Port FK, Wolfe RA, Leichtman AB, Young EW, et al. Chronic renal failure after transplantation of a nonrenal organ. N Engl J Med, 2003. 349: 931-940.

27. Cornelis T, Jean PR, Joanne MB, Chan CT. Home dialysis is a successful strategy in nonrenal solid organ transplant recipients with end-stage renal disease. Nephrol Dial Transplant. 2010; 25: 3425-3429.

28. Perl J, Bargman JM, Jassal SV. Peritoneal dialysis after nonrenal solid organ transplantation: clinical outcomes and practical considerations. Perit Dial Int. 2010; 30: 7-12.

29. Wong LP, Scott EL, Katherine AW, Susan M. Training of surgeons in peritoneal dialysis catheter placement in the United States: a national survey. Clin J Am Soc Nephrol, 2010; 5: 1439-1446.

Citation: Mamatha G, Katherine DM, Saman SS, Scott EL and Randeep K. Challenges of Laparoscopic Peritoneal Dialysis Catheter Placement in the Hostile Abdomen. SM J Nephrol Therap. 2016; 1(1): 1004.
https://dx.doi.org/10.36876/smjnt.1004