SMGroup

SM Ophthalmology Journal

Research Article

Macular Hole Surgery after Treatment with Ocriplasmin for Full Thickness Idiopathic Macular Holes with Vitreomacular Traction

Khaled Helaiwa[1,2]*, Ammar Heider[2], KU Bartz-Schmidt[1] and Kai Januschowski[1,2]

[1]*University Eye Hospital, Eberhard-Karls-University Tuebingen, Germany*
[2]*Knappschaft Eye Clinic Sulzbach, Knappschaft Hospital Saar, Sulzbach/Saar, Germany*

Article Information

Received date: Dec 11, 2016
Accepted date: Feb 10, 2017
Published date: Feb 15, 2017

***Corresponding author**

Khaled Helaiwa, Knappschaft Eye Clinic Sulzbach, Knappschaft Hospital Saar An der Klinik 10, 66280 Sulzbach Saar, Germany, Tel: +4968975743302; Fax: +4968975742139; Email: khahel@hotmail.com

Keywords Vitreomacular adhesion; Macular holes; Ocriplasmin; Vitrectomy

Abstract

Purpose: To report the efficacy of Ocriplasmin in the treatment of small-medium sized idiopathic full thickness Macular Holes with focal Vitreomacular traction in comparison with vitreous surgery.

Methods: Retrospective observational single-centre small case series (n=6) studythat included patients who underwent vitrectomy after unsuccessful treatment ofsmall-medium size full thickness Idiopathic macular holes with ocriplasmin.

Results: 6 eyes with full-thickness macular holes and VMT were included, whereby in 4 eyes an epiretinal membrane was present (66.7%). Resolution of VMT after intravitreal injection of ocriplasmin was shown in three out of six eyes (50%) and in all six eyes after vitrectomy (100%). Of all six eyes presenting macular holes with a mean size of 265 µm ± 109 µm at baseline visit, five eyes showed persistent macular holes at the second follow-up visit with a mean size of 335 µm ± 166 µm. After vitrectomy no macular hole could be detected at the final follow-up visit.

Conclusion: We present our clinical experience with intravitreous injection of Ocriplasmin to confirm the presumed therapeutic effect in patients suffering from Vitreomacular Traction (VMT) with small-medium sizedfull-thickness Macular holes (MH). Small macular holes could frequently be closed with only Ocriplasmin and without surgery with a 17% closure rate. Enlargement in all holes that failed to close with Ocriplasmin was observed in all treated eyes which makes us believe that the VMT could have a Protective role. Ellipsoid zone disruptions were evident in 50% of treated eyes and more common in eyes with successful VMT release. Although data on Ocriplasmin from several studies remain controversial but so far the results are consistent with the results and recommendations of other clinical studies and the European Medicine Agency. We agree that replacing vitrectomy for MHs with one injection of Ocriplasmin would be a very attractive option but so far Pars plana vitrectomy remain the treatment of choice for most eyes with MHs. Further Work is recommended to reveal the Cause of the ellipsoid zone Changes, the mechanisms of tractional forces and to investigate the Long term side effects of Ocriplasmin.

Introduction

Incomplete posterior vitreous detachment (PVD) is considered in most patients an Age-Related Degenerative Process that leads to a disturbed Vetreoretinal Interface (VRI) in the form of Vitreomacular Traction (VMT), which is a major contribution to macular dysfunction that leads in turn to the development or progression of macular holes or cystoid macular edema [1-3]. With recent non-invasive imaging advances such as Optical Coherence Tomography (OCT) we were able to analyze and precisely diagnose and manage Vetreoretinal interface diseases. The initial modality of treatment which was implemented and practiced widely with relatively good outcomes, according to several studies, is the pars plana vitrectomy, striping (peeling) of the epiretinal membranes, and a total gas-fluid exchange. Ocriplasmin (Jetrea; ThromboGenics, Inc, Iselin, NJ) has recently become available as a new modality of treatment to induce pharmacologic vitreous separation [4]. It is delivered via a single intravitreal injection (0.125 mg/0.1 mL) and can effectively release the symptomatic vitreomacular adhesion in 26.5% of patients and additionally it led to the closure of full thickness macular holes (without vitrectomy) in 40.6% of the Patients which was significantly more in comparison with an injection of placebo [5], although it is approved in the United States for the treatment of patients with symptomatic vitreomacular adhesion in general, nevertheless clinical studies and the European Medicine Agency recommends that it is best used for symptomatic vitreomacular traction associated with small to medium sized (≤400 µm) macular holes. Furthermore the German Retina Society and the German Ophthalmology Society (DOG) recommends in their guidelines that it is best used for symptomatic vitreomacular traction which did not resolve spontaneously after 3 Months and/or is associated with small sized (≤250µm) macular holes, and that Vitrectomy should be planed if the Vitreomacular Traction (VMT) does not resolve after 4 weeks after Ocriplasmin (Jetrea®) intravetrial injection [6]. In another recently

conducted study on 135 eyes with full thickness macular holes with only 9 eyes had ≤400 µm macular holes out of which only 2.7% have benefited from ocriplasmin injection, and they have concluded that ocriplasmin injection is an adequate choice for few patients with macular holes and that Pars plana vitrectomy will probably remain the treatment of choice for most eyes with macular holes, and this situation could change if macular holes are detected earlier and treated while they are still small and have vitreomacular traction [7].

Patients and methods

This is a retrospective observational single-centre case series study that included 6 patients who underwent vitrectomy after unsuccessful treatment of full thickness Idiopathic macular holes with ocriplasmin from October 2014 until August 2015 at the University Eye Clinic Tübingen. The patients had a documented partial PVD on Spectral-domain optical coherence tomography (SD-OCT, Spectralis Heidelberg Engineering, Heidelberg Germany) with evidence of at least a partial attachment in the foveal region (focal VMA) and a Vitreomacular Traction (VMT) resulting in a small-sized (< 250 µm) to medium-sized (250-400 µm) Full-Thickness Macular Holes (FTMHs). All patients were symptomatic and presented with a visual acuity distortion demonstrable with an Amsler grid. A complete eye examination, including visual acuity (measured using a standard Snellen visual acuity chart), slit-lamp examination of the anterior segment with dilated fundus examination was performed preoperatively and postoperatively and at each follow-up visit. Preoperative concomitant changes such as epiretinale membrane (ERM), age-related macular degeneration (AMD) or diabetic retinopathy were registered.

After an informed consent all patients received initially a 0.125 mg Ocriplasmin intravitreal single injection (Jetrea®) under topical anesthesia and under sterile technique as previously published [8].

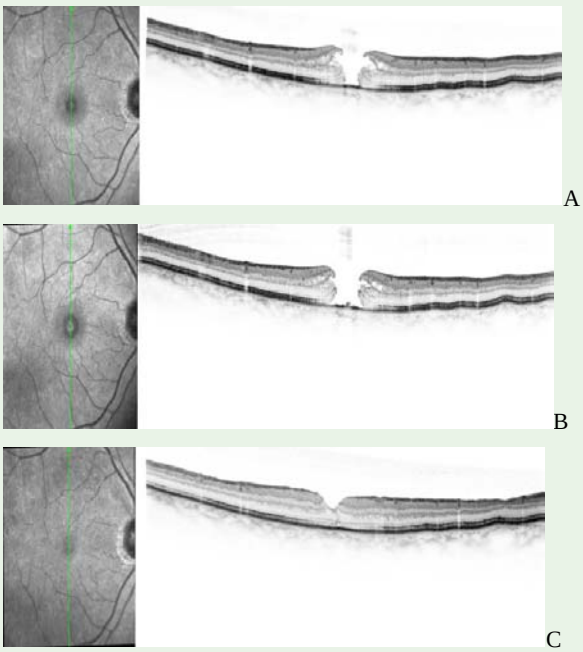

Figure 1: OCT of one of the Patients a) Before Ocriplasmin b) After Ocriplasmin c) After Parsplana Vitrectomy and peeling.

The injection was performed 3.5-4.0 mm pars plana, and the patient was confirmed to have counting fingers vision or better immediately after the injection. The procedure was performed according to the manufacturer's instructions and according to the German retina society guidelines [6]. Patients were controlled for successful outcome at 4-8 weeks after injection. After unsuccessful closure of the macular holes one month later, we advised the patients to undergo surgery. All patients decided to wait for a longer time after consenting for surgery.

The surgical procedure consisted of a pars plana vitrectomy, striping (peeling) of the epiretinal membranes, and a total gas-fluid exchange except in two patients who received only air. All surgical procedures were performed under parabulbar anesthesia, except one patient who requested a general anesthetic. Postoperative examinations and follow up were performed at the first 3 days as in-patients before discharge and at 4-8 Weeks after discharge from the hospital [9,10].

Primary endpoint of this study was defined as resolution of VMT. The secondary endpoint was identified to be the mean visual acuity. Postoperatively, concomitant changes such as cataract or retinal detachment were recorded. Intraoperative and postoperative complications were documented.

Results

A total of six eyes out of six patients met all inclusion and exclusion criteria and were included in this observational analysis. The mean age of our patients was 75.4 (± 5.1) years, with a range from 71 to 85 years. Five patients were women and one was a men. Three of the eyes involved the right eye and three involved the left eye. There were no bilateral involvements. Mean second follow-up visit was performed 6 ± 2 weeks after injection of ocriplasmin and the mean final follow-up visit performed 6 ± 2weeks after vitrectomy.

Before injection of ocriplasmin all six eyes presented focal VMT with mean adhesion size of 345 µm ± 170 µm combined with a macular hole with a mean size of 265 µm ± 109 µm. Four of six eyes (66%) additionally presented Epiretinal membrane (ERM). All eyes were treated with suture less 23-gauge pars plana vitrectomy and epiretinal peeling. Out of six eyes, four eyes (66%) were treated with gas tamponade (20% sulfur hexafluoride gas, SF_6, or 15% hexafluoroethane gas, C_2F_6) and two eyes (33%) received air tamponade [11].

The primary endpoint, a resolution of VMT was achieved in three out of six eyes (50%) after injection of ocriplasmin at the second follow-up and in all six eyes (100%) after vitrectomy at the final follow-up visit. Mean adhesion size of VMT decreased from 345 µm ± 170 µm at baseline to 195 µm ± 272 µm at second follow-up to no adhesion at final follow-up. Of all six eyes presenting macular holes with a mean size of 265 µm ± 109 µm at baseline visit, five eyes showed persistent macular holes at the second follow-up visit with a mean size of 335 µm ± 166 µm. After vitrectomy no macular hole could be detected at the final follow-up visit (Figure 1).

After vitrectomy restoration of the ellipsoid zone was observed in 3 out of 6 cases. The other three cases showed disrupted ellipsoid zones, whereby the position of the disrupted ellipsoid zone was in twice central and once temporal in relation to the fovea. The mean size of the disrupted ellipsoid zone was 167 µm ± 102 µm (Figure 2).

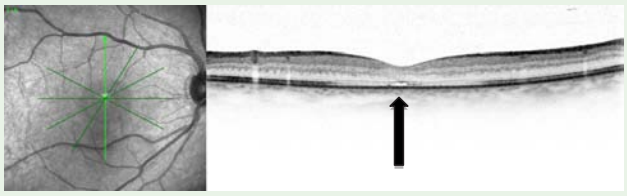

Figure 2: OCT demonstrating a central ellipsoid zone.

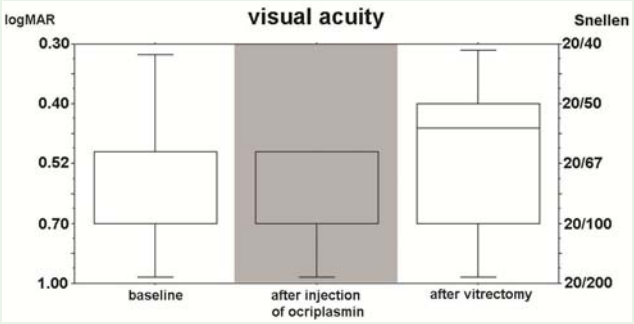

Figure 3: Box plot analysis illustrates visual acuity in eyes after treatment with an injection of ocriplasmin (grey box) and after vitrectomy. The ordinate shows visual acuity in logMAR (left ordinate) and in Snellen (right ordinate) for baseline (left side), at secondary follow-up after ocriplasmin injection (middle, grey box) and after vitrectomy (right side).

The secondary study endpoints, mean visual acuity slightly decreased from logMAR 0.65 ± 0.23 at baseline to logMAR 0.68 ± 0.18 (20/79 to 20/90 Snellen equivalent) (p=0.42) after injection of ocriplasmin and improved slightly to logMAR 0.55 ± 0.15 (20/63 Snellen equivalent) after vitrectomy (p=0.07), representing an average gain in visual acuity of 1.3 lines (Figure 3).

In 1 eye a postoperative complication in terms of sub retinal fluid was observed at the final follow-up visit. After vitrectomy one out of 6 patients underwent a Phacoemulsification surgery due to Cataract. None of the patients had Retinal Detachment.

Enlargement in all holes that failed to close with Ocriplasmin was observed in all treated eyes which makes us believe that the VMT could have a Protective role.

Discussion

Ocriplasmin is currently used in clinical practice in Europe for full-thickness macular holes less or equal than 400 µm. Different complications are associated with the intravitreal injection of ocriplasmin such as visual acuity decrease, vitreous floaters, ellipsoid zone changes, photopsias, sub retinal fluid development, enlargement of macular hole, anterior segment changes and electroretinogram alterations. In the Phase III clinical trials nonsurgical closure was shown after ocriplasmin in 43 out of 106 eyes (40.6%) [5]. For VMT the positive predictors such as age <65 years, vitreomacular traction<1500 µm, phakic lens status and the absence of epiretinal membrane are already known. Whereas a recent published meta-analysis revealed that a macular hole size < 250 µm is associated significantly with a nonsurgical closure [11].

However, our results showed that the efficacy after single injection of intravitreal injection of ocriplasmin seems to be reduced in patients with full-thickness macular holes less than 400 µm nonsurgical closure rate in our small case series study was only 16.7%. In fact, that one eye with the nonsurgical closure met the positive criteria by presenting a small macular hole < 250 µm.

Worth to mention is also the fact that 4 out 6 eyes had an epiretinal membrane, which affects the efficacy of ocriplasmin adversely. The whole patient group was older than 65 years. That is why the careful selection of patients for ocriplasmin injection in consideration of the positive predictive factors plays a significant role.

Furthermore, we could also demonstrate that visual acuity increased after vitrectomy following intravitreal injection of ocriplasmin. Our findings are consequential, because improvements in visual acuity in patients with macular holes are time dependent.

Recently, Lee et al. also reported about persisting macular hole after ocriplasmin despite resolution of VMT in all 4 eyes and only by subsequent vitrectomy anatomic closure was achieved [9]. Maier et al. [10] showed indeed in their study that they achieved similar results as the above mentioned Phase III trial with a closure rate of 40% (n=5) in macular holes.

The study is limited due to small numbers of patients. Therefore, we strongly recommend further investigations with larger patient groups. Besides, limitations of our study include the retrospective character of the study. We would like to underline that the presented data include a follow up to 8 weeks post operatively only. Further improvement, especially with regard to BCVA, might be expected within a longer follow-up, because further rehabilitation of anatomical structures in the macular region, especially the ellipsoid zone which was reported in several studies to be reversible and lead to improved visual acuity results.

References

1. Green WR. The Macular hole: Histopathologic Studies. Arch Ophthalmol. 2006; 124: 317-321.
2. Sebag J. Anomalous posterior vitreous detachment: a unifying concept in vitreo-retinal disease. Graefes Arch Clin Exp Ophthalmol. 2004; 242: 690-698.
3. Johnson MW. Tractional cystoid macular edema: a subtle variant of the vitreomacular traction syndrome. Am J Ophthalmol. 2005; 140: 184-192.
4. ThromboGenics. JETREA (package insert). Iselin, NJ, USA, 2012.
5. Stalmans P, Benz MS, Gandorfer A, Kampik A, Girach A, et al. Enzymatic vitreolysis with ocriplasmin for vitreomacular traction and macular holes. New Engl J Med. 2012; 367: 606-615.
6. Bartz-Schmidt KU, Bertram B, Bornfeld N, Bresgen M, Eter N, et al. Current Statement of the German Ophthalmological Society, the Retina Society and the Professional Association of German Ophthalmologists for therapeutic intravitreal application of Ocriplasmin (JETREA®) in ophthalmology (May 2013). Klin Monbl Augenheilkd. 2013; 230: 629-634.
7. Moisseiev J, Moroz I, Katz G. Effect of ocriplasmin on the management of macular holes: assessment of the clinical relevance of ocriplasmin. JAMA Ophthalmol. 2014; 132: 709-713.
8. Kozak I, Cheng L, Freeman WR. Lidocaine gel anesthesia for intravitreal drug administration. Retina. 2005; 25: 994-998.

9. Lee GD, Taney LS, Rogers AH, Shah CP, Duker JS, et al. Surgical Outcomes for Persistent Macular Hole after Ocriplasmin. Ophthalmic Surg Lasers Imaging Retina. 2015; 46: 732-736.

10. Maier M, Abraham S, Frank C, Feucht N, Lohmann CP. Ocriplasmin as a treatment option for symptomatic vitreomacular traction with and without macular hole. First clinical experiences. Ophthalmologe. 2015; 112: 990-994.

11. Chatziralli I, Theodossiadis G, Xanthopoulou P, Miligkos M, Sivaprasad S, et al. Ocriplasmin use for vitreomacular traction and macular hole: A meta-analysis and comprehensive review on predictive factors for vitreous release and potential complications. Graefes Arch Clin Exp Ophthalmol. 2016; 254: 1247-1256.

Citation: Helaiwa K, Heider A, Bartz-Schmidt KU and Januschowski K. Macular Hole Surgery after Treatment with Ocriplasmin for Full Thickness Idiopathic Macular Holes with Vitreomacular Traction. SM Opthalmol J. 2017; 3(1): 1009.