

Dorsal Spine Puncture Injury: A Surgical Challenge

Jesús Morales Maza^{1*}, Mauricio Zúñiga Zamora², Daniel Alberto Vargas Velásquez³ and Luis Cruz Benítez²

¹Department of Surgery, National Institute of Medical Sciences and Nutrition 'Salvador Zubiran', Mexico

²Department of Surgery, Hospital Regional de Alta Especialidad de Ixtapaluca, Mexico

³Department of Surgery, Hospital General de México Dr. Eduardo Liceaga, Mexico

Article Information

Received date: Aug 24, 2017

Accepted date: Aug 28, 2017

Published date: Aug 30, 2017

*Corresponding author

Jesús Morales Maza, Department of Surgery, National Institute of Medical Sciences and Nutrition 'Salvador Zubiran', Mexico City, Mexico, Vasco de Quiroga 15, Col. Sección XVI, 14000 Tlalpan, Mexico City, Mexico, Tel: +01 (55) 6165-0326; E-mail: medcardiouv@hotmail.com

Distributed under Creative Commons CC-BY 4.0

Clinical Summary

We present the case of a 26-year-old patient who came to the emergency department for aggression with a puncture injury (ice picking) at the T12 thoracic vertebra.

At his admission to the emergency department patient was hemodynamically stable without active bleeding signs.

Patient had a puncture object with an entrance orifice at T12 level (Figure 1), mobility and sensitivity of lower extremities were preserved. Abdominal tomography with evidence of a sharp object with an entrance adjacent to the vertebra with the distal end in contact with the medial wall of the inferior vena cava (Figure 2).

Removal of pricking object in supine position on orthopedic table was performed making a midline laparotomy with evidence of stinging object in left lateral region of inferior vena cava without hematoma or active bleeding; extraction was performed with traction towards the dorsal region. He presented good postoperative evolution deciding his discharge on the third postoperative day.

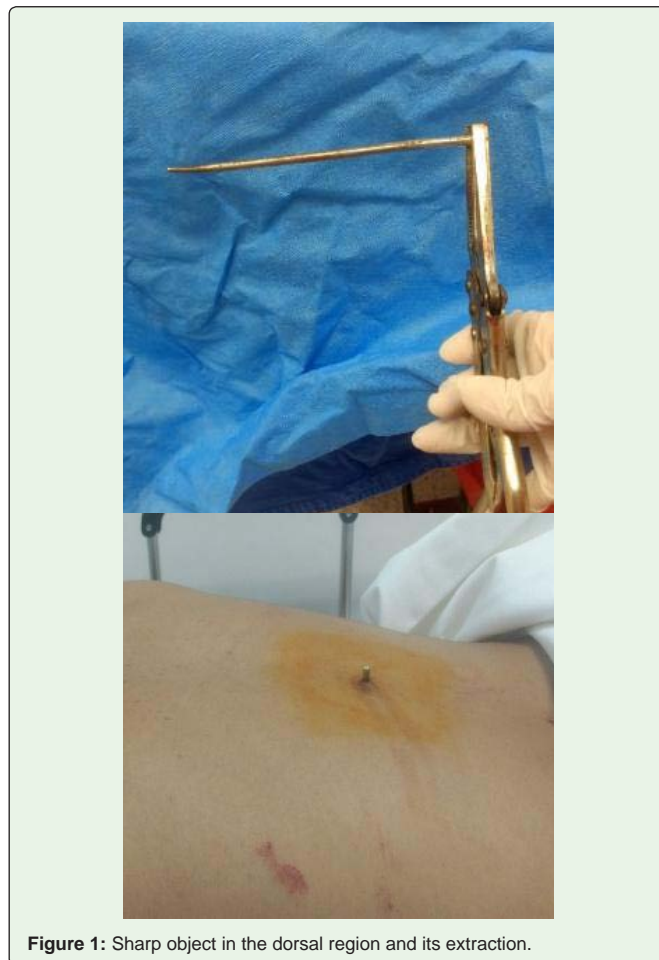


Figure 1: Sharp object in the dorsal region and its extraction.

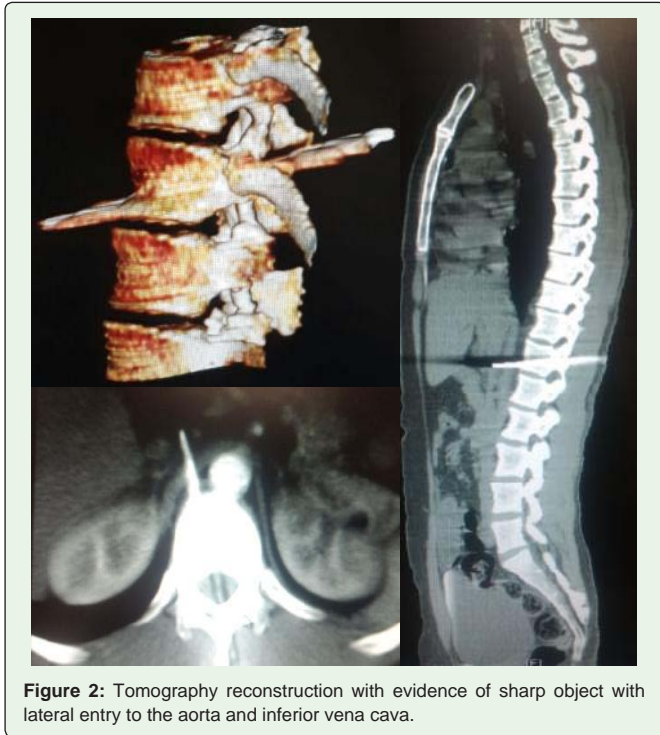

Figure 2: Tomography reconstruction with evidence of sharp object with lateral entry to the aorta and inferior vena cava.

We present an infrequent case of puncture injury in the dorsal region. Although the object was found in this region, it was decided to perform exploratory laparotomy as there was a risk of injury to large vessels and at the time of removal of the object there was a risk of massive hemorrhage. The indicated management in such situation is to perform damage control surgery since correcting the hemorrhage in a controlled way can improve the chances of survival [1].

When an injury occurs in the inferior vena cava successful outcome depends on prompt volume restoration, a stratified selective management approach, and avoidance of hypothermia [2].

In the case of our patient, no repair maneuver was performed in the vena cava because there was no lesion or active bleeding.

No evidence supports the need to expose and repair vena caval wounds that have spontaneously stopped bleeding. Such wounds, especially in the retrohepatic area, may be managed expectantly [3].

References

1. Kaafarani HM, Velmahos GC. Damage Control Resuscitation in Trauma. *Scand J Surg.* 2014; 103: 81-88.
2. Klein SR, Baumgartner FJ, Bongard FS. Contemporary management strategy for major inferior vena caval injuries. *J Trauma.* 1994; 37: 35-41.
3. Buckman RF, Pathak AS, Badellino MM, Bradley KM. Injuries of the inferior vena cava. *Surg Clin North Am.* 2001; 81: 1431-1447.