SMGroup

SM Journal of Orthopedics

Research Article

Analysis of Forearm Muscle Activity Aiming at Prevention of Refractory Tennis Elbow: Comparison of One-Handed Backhand Stroke Form

Rina Sakai[1,3]*, Yasuaki Ohtaki[2], Nami Sakaguchi[3], Naonobu Takahira[1,3,4], Tomonori Kenmoku[4], Kazuhiro Yoshida[1,3] and Masanobu Ujihira[1,3]

[1]*Department of Medical Engineering and Technology, Kitasato University, Japan*
[2]*Faculty of Engineering, Kanagawa Institute of Technology, Japan*
[3]*Graduate School of Medical Science, Kitasato University, Japan*
[4]*Department of Orthopedic Surgery, Kitasato University, Japan*

Article Information

Received date: Aug 03, 2018
Accepted date: Aug 21, 2018
Published date: Aug 22, 2018

***Corresponding author**

Rina Sakai, Department of Medical Engineering, Kitasato University, 1-15-1 Kitasato, Minami Ku, Sagamihara City, Kanagawa, 252-0329, Japan, Tel: 042-778-9636; Email: rinax@kitasato-u.ac.jp

Keywords Tennis elbow; Lateral elbow tendinopathy; Muscle activity

Abstract

The cause of tennis elbow depends on the playing style, and the incidence is high in players who perform one-handed backhand strokes. Complication of tennis elbow with impairment of the synovial folds results in refractory tennis elbow and when it aggravates to a severe state, surgical treatment is required. In this study, aiming at the prevention of refractory tennis elbow, activities of the forearm muscles were compared between one-handed backhand stroke forms with the forearm set in the median and supinated positions to investigate the possibilities of the two forms damaging the elbow joint. Inverse dynamics of nineteen forearm muscles in one-handed backhand stroke motions were analyzed in a subject who overcame lateral elbow tendinopathy. The maximum voluntary contraction and changes in the elbow joint flexion angle were compared between the neutral form with little forearm supination and a form with forearm supination to the range of motion. The maximum voluntary contraction at the peak of the supinator was 28% in the neutral form and 48% in the form with forearm supination. The muscle activity level at the peak of the musculus extensor carpi ulnaris was 50% in the neutral form and 70% in the supinated form. It was clarified that the elbow joint flexion angle markedly changed within a short time in the supinated form compared with that in the neutral form. In one-handed backhand stroke motions, the form with reduced maximum voluntary contraction was the neutral form with little forearm supination. It was clarified that the elbow joint flexion angle markedly changes upon impact in the supinated form. To fully swing a one-handed backhand stroke, a form setting the forearm in the median position may reduce the risk of refractory tennis elbow compared with that in the supinated position.

Introduction

Tennis elbow, i.e., lateral elbow tendinopathy, is a degenerative tendinopathy in which pain develops in the elbow due to repeated tennis strokes and it is reported to be readily caused by one-handed backhand strokes [1,2]. However, the developmental mechanism of lateral elbow tendinopathy has not been elucidated, and pathologically, it is reported to be multifactorial [3]. Studies on clinical findings clarified the area in which lateral elbow tendinopathy-induced pain develops [4-6]. The area is the origin of the extensor and 6 muscles attached to the origin, the lateral epicondyle: the extensor digitorum communis, extensor digitiminimi, supinator, extensor carpi ulnaris, extensor carpi radialis brevis and extensor carpi radialis longus [7].

The incidence of this tendinopathy in tennis players is high (30-50%), and more than 60% of professional tennis players have experienced this tendinopathy [8,9]. Its cause depends on their playing style and it more frequently occurs in players who perform backhand strokes with one hand than in those with both hands [10-12]. Regarding age, a high incidence in the elderly was reported [13].

In one-handed backhand stroke motions, all forearm muscles, from superficial to deep layer, are used. The muscles present in the superficial layer of the forearm can be measured by electromyography, but those in the deep layer are difficult to measure. Many biomechanical studies on tennis elbow have been performed, but only a few studies investigated the deep layer muscle activity level in players who experienced tennis elbow [2,9-11,14,15]. There are means to simulate the deep layer muscle activity level by which the maximum muscle activity level is calculated by dividing the muscle tension by the maximum muscle strength estimated from the height and body weight of the player, for which the motion capture technique is necessary to closely analyze motions and a musculoskeletal model is prepared using this technique. By analyzing inverse dynamics of this musculoskeletal model, an important index of strength of each muscle, the Maximum Voluntary Contraction (MVC), can be closely analyzed [16].

How to cite this article Sakai R, Ohtaki Y, Sakaguchi N, Takahira N, Kenmoku T, Yoshida K, et al. Analysis of Forearm Muscle Activity Aiming at Prevention of Refractory Tennis Elbow: Comparison of One-Handed Backhand Stroke Form. SM J Orthop. 2018; 4(1): 1064s2.

In this study, inverse dynamics of nineteen forearm muscles were analyzed in one-handed backhand stroke motions in a subject who overcame lateral elbow tendinopathy and MVC and changes in the elbow joint flexion angle were calculated in two forms of full swing backhand stroke: a neutral form with little forearm supination (f1) and a form with forearm supination to the range of motion (f2), to investigate which of the two forms may serve as a factor preventing tennis elbow.

Methods

This study was performed after approval by the Research Ethics Committee of Kitasato University School of Allied Health Sciences (2015-015). The subject was a man playing tennis for 30 years (age: 65 years old, height: 160 cm, weight: 55 kg). He mainly performed deskwork in his occupation, his tennis performance was advanced, and he held a racket with his dominant hand. He previously had elbow pain at 60 years old and was diagnosed with lateral elbow tendinopathy. It completely resolved after one-year observation (61 years old). No drug, orthotic, or surgical treatment was performed throughout the one-year period with persistent pain, and he continued playing tennis with a form causing no pain (supination of the forearm was avoided as much as possible). In the form before the development pain, the forearm was supinated to the range of motion (f2).

To acquire images using optical motion capture with Vicon Motion Systems VICON 512 (Vicon Motion Systems Ltd., UK), markers were attached to the subject following the Vicon Plug-in-Gait marker set (Vicon Plug in Gait Manual, 2003). Forty-three markers were set on the subject and five were set on the racket held in his dominant hand. The subject set and took back the racket, followed by full backhand swing in a form with little forearm supination from immediately before to immediately after impact in the neutral form (f1) and with forearm supination to the range of motion (f2). Each form was performed five times (Figure 1). In f1, the elbow was slightly bent and kept in the neutral position absorbing impact, and the bent forearm was not pronated or supinated. In f2, the elbow was bent accompanied by ball-scrubbing movement and the pronated forearm was supinated to the range of motion. The fastest stroke was analyzed in each form. The range of data analysis was a series of movementsfrom holding the racket with both hands in the bilateral stance phase to pulling it backward using one hand and subsequent backhand stroke as if hitting a ball forward.

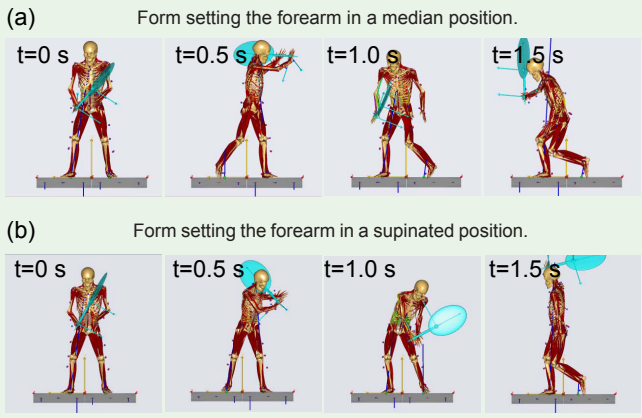

Figure 1: Full-swing motion of backhand stroke.

The positions in f1 and f2 were measured as follows: Infrared lights emitted by nine Progressive Scan CCD Cameras (TM-6710, JAI PULiX Inc., CA, USA) were reflected by the markers and these reflected lights were measured and recorded at a frequency of 120 Hz. At the same time, the forms were recorded using an analog video camera, HSV-500C3 (nac Image Technology Inc., Japan) at 30 frames/sec. The floor reaction force was measured using two force plates (Z15907A, KISTLER, Japan) and two 8-channel charge amplifiers (9865, KISTLER, Japan). For calculation of the range of motion of each joint and conversion to a skeletal model, Vicon Workstation 4.5 Build 124 (Vicon Motion Systems Ltd., UK) was used and the results were output as c3d files. The coordinate system and definition of the joint angles were established following the Plug-In Gait (Vicon Plug in Gait Manual, 2003) and the anatomical standing position was regarded as a reference posture.

For inverse dynamic calculation of tensions of the muscles required for multi-joint movement, musculoskeletal modeling software, Anybody Modeling System ver. 6.0.4 (Anybody Technology A/S, Denmark), was used [17]. The racket weight and moment of inertia were not considered in the inverse dynamic analysis. The tensions of the forearm muscles, f(M), during f1 and f2 movements were calculated and the muscle activity, G {f(M)}, of each muscle was calculated by dividing the calculated muscle tension by the maximum muscle strength, Ni, estimated from the height and body weight [18].

$$G\{f(M)\}=\max(f(M)/Ni)$$

This algorithm introduced the min/max criterion for simulation of muscle recruitment in multiple muscle systems. The criterion was justified by comparison to two known criterion types: the polynomial criterion and the soft saturation criterion. The comparison was performed on a planar three-muscle elbow model.The musculoskeletal model comprised approximately thousand muscle fiber bundles, and thirty-four of them were adopted for analysis of the forearm muscles. The targets were nineteen muscles, including the ECRB, Flexor Carpi Ulnaris (FCU), brachioradialis and supinator (Table 1).

Results

The maximum muscle activity level was higher in f2 than in f1 in ten of the nineteen muscles. Among the forearm muscles, the highest maximum muscle activity level was detected in the Extensor Carpi Radialis Longus (ECRL) followed by the ECRB (Figure 2). Then, the abductor pollicis longus, FCU and pronator quadratus exhibited a similar maximum muscle activity level among the forearm muscles. The peak ECRB activity level was markedly high in both f1 and f2, exceeding the maximum level (Figure 3).

Muscles with a markedly high activity level in f2 compared with f1 included the supinator and FCU. The peak level of the supinator was 28% in f1, but 48% in f2 (Figure 4). The peak level of the FCU was 50% in f1 and 70% in f2 (Figure 5).

Regarding changes in the elbow joint flexion angle on the dominant side in f1, the angle gradually decreased from 0.5 s, extending the elbow joint, and reached the impact at 1.0 s with 35° flexion (Figure 6a). In f2, the elbow joint was bent from 40° to 10° and reached the impact after slightly retuning at 0.8 s to 35° flexion (Figure 6b). It was clarified that the elbow joint flexion angle markedly changes within a short time in f2 compared with that in f1.

Citation: Sakai R, Ohtaki Y, Sakaguchi N, Takahira N, Kenmoku T, Yoshida K, et al. Analysis of Forearm Muscle Activity Aiming at Prevention of Refractory Tennis Elbow: Comparison of One-Handed Backhand Stroke Form. SM J Orthop. 2018; 4(1): 1064s2.

Table 1: Nineteen forearm muscles analyzed and their anatomical positions.

Muscles of the forearm		Anatomical position
pronator teres	**Proximal muscles**	first layer
flexor carpi radialis		first layer
palmaris longus		first layer
flexor carpiulnaris		first layer
brachioradialis		first layer
flexor digitorum superficialis		second layer
flexor digitorum profundus		third layer
ftexor pollicislongus		third layer
pronator quadratus		forth layer
extensor carpiradialislongus		superficial layer
extensor carpi radialis brevis	**Distal muscles**	superficial layer
extensor carpiulnaris		superficial layer
extensor digitorum		superficial layer
extensor carpi radialis brevis		superficial layer
extensor digiti minimi		deep layer
supinator		deep layer
extensor indicis		deep layer
extensor pollicislongus		deep layer
extensor pouicis brevis		deep layer
abductor pollicis longus		deep layer

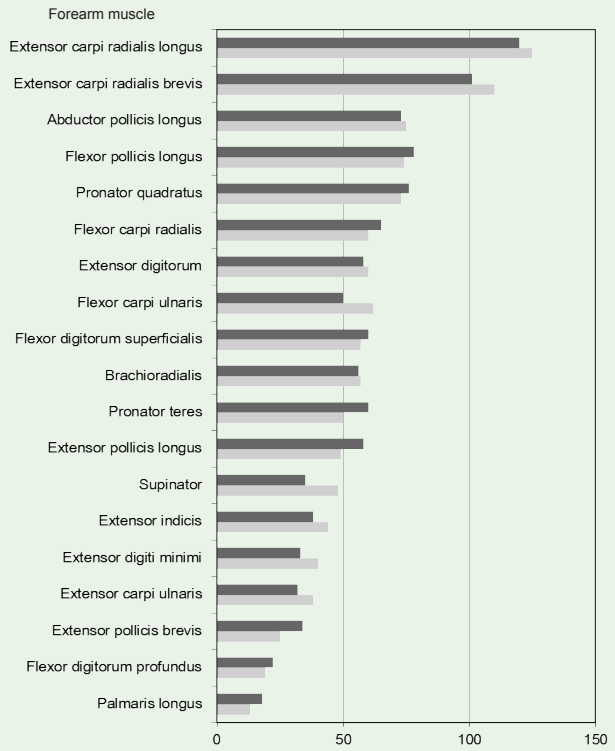

Figure 2: Maximum activity levels of nineteen forearm muscles.

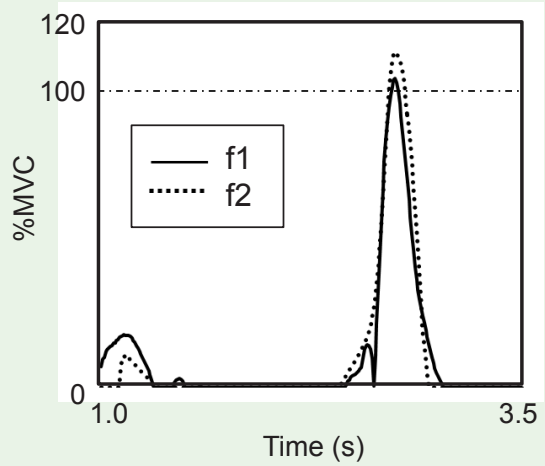

Figure 3: Muscle activity of the ECRB. The solid and dotted lines represent f1 and f2, respectively.

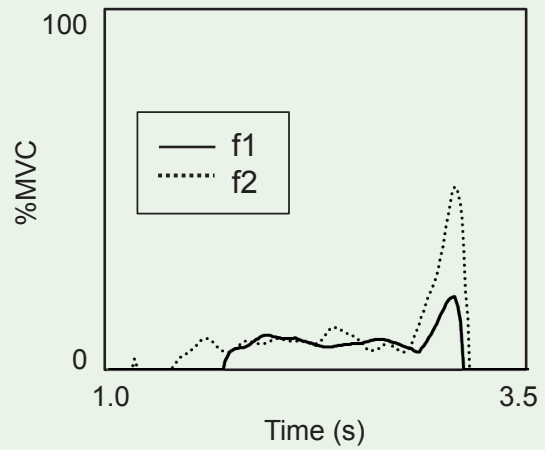

Figure 4: Muscle activity of the supinator. The solid and dotted lines represent f1 and f2, respectively.

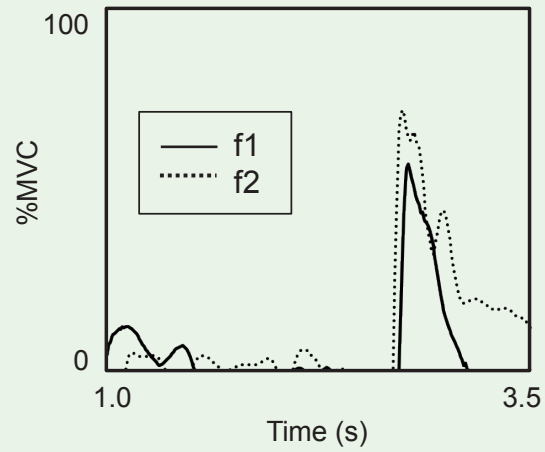

Figure 5: Muscle activity of the FCU. The solid and dotted lines represent f1 and f2, respectively.

Citation: Sakai R, Ohtaki Y, Sakaguchi N, Takahira N, Kenmoku T, Yoshida K, et al. Analysis of Forearm Muscle Activity Aiming at Prevention of Refractory Tennis Elbow: Comparison of One-Handed Backhand Stroke Form. SM J Orthop. 2018; 4(1): 1064s2.

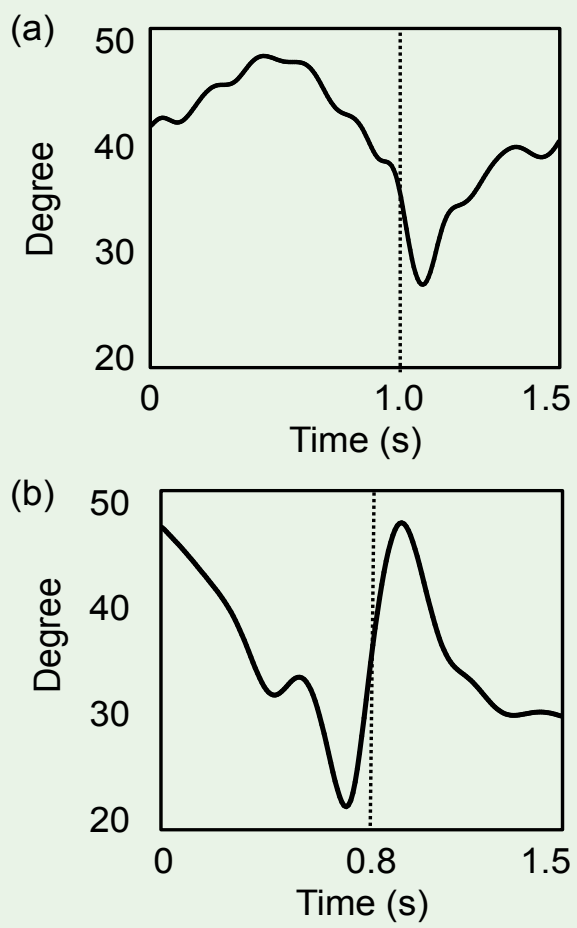

Figure 6: Changes in the elbow joint flexion angle of the dominant hand. The dotted line represents the time-point of impact.

Discussion

The ECRL originates from the lateral intermuscular septum located at the lateral supracondylar ridge over the lateral epicondyle of the humerus and it is present in the shallow layer of the posterior forearm [19,20]. The ECRL is the prime mover of extension and radial deviation of the wrist joint, and this may have been the reason why the highest muscle activity level was detected on extension of the wrist joint to adjust the plane of the racket among the forearm muscles.

Nirschl et al. defined the pathology of lateral elbow tendinopathy as chronic vascular fibrous tendinosis of the ECRB attached to the lateral epicondyle of the humerus [21]. Yu et al. reported that the possibility of developing tendinopathy increased with an increase in MVC [22]. MVC exceeded the maximum muscle activity level in the ECRB, suggesting that the possibility of developing tendinopathy of the ECRB is high in both f1 and f2 forms.

The result demonstrating a 2- or more-times higher muscle activity level of the supinator in f2 than in f1 reflected the difference in the form between f1 with little supination and intended f2 with supination. When a form is accompanied by forearm supination, the muscle activity of not only the ECRB but also the other muscles may rise, increasing the load per shot, i.e., repeating a form accompanied by forearm supination may induce not only refractory tennis elbow but also other elbow tendinopathy joint diseases. In a full swing backhand stroke, MVC was lower in the form with a neutral forearm position (f1) than in f2, suggesting that the risk of tennis elbow can be reduced by f1 compared with by f2 based on the report by Yu et al. [22].

The FCU runs above the medial collateral ligament, and its activity complements the action of this ligament and breaks valgus motion of the elbow, suggesting that injury of the FCU increases the load on the medial collateral ligament. This finding suggested that the muscle activity level of the FCU increases with an increase in the load on the medial collateral ligament. It has been reported that injury of the medial collateral ligament in baseball forms causes medial baseball elbow [23]. The FCU activity level was higher in f2, suggesting that repeating the f2 form increases the load on the FCU, and loss of auxiliary function for the medial collateral ligament may secondarily cause tennis elbow. As the muscle activity level of the FCU increases, the auxiliary function for the medial collateral ligament is lost, which may be a secondary factor inducing tennis elbow.

At the time of impact, the elbow was bent slightly in f1 and largely in f2. The supinator is one of the main muscles used in flexion. MVC of the supinator was higher in f2 than in f1. As the time interval was the same in f1 and f2, the elbow was rapidly bent in f2. It was assumed that the ball impact has a negative influence on the muscle when the elbow flexion angle is large, i.e., the muscle activity level is high compared with that when the elbow flexion angle is small, i.e., the muscle activity level is low.

The result was based on analytical data, for which verification by comparison with measured values is desirable to evaluate the reliability. It may be investigated by preparing a model with muscle fibers accurately simulating the origin and insertion in the forearm bone and performing an experiment of forearm supination. As a limitation, this study was performed involving only one subject. The f1 was a rare form devised to reduce pain by the subject who experienced tennis elbow. The subject was limited to this person because it was difficult for other tennis players to perform the same form; however, to secure the validity of the findings, it is necessary to collect many subjects with experience of tennis elbow and analyze a one-handed backhand stroke form preventing pain in each subject.

Conclusion

Inverse dynamics of the nineteen forearm muscles in one-handed backhand stroke motions were analyzed in a subject who overcame lateral elbow tendinopathy. MVC and changes in the elbow joint flexion angle were calculated in two forms: a neutral form with little forearm supination in a full swing of a one-handed backhand stroke and a form with more forearm supination compared with that in the neutral form, to investigate which of the two forms may serve as a factor inducing no tennis elbow. In the one-handed backhand stroke motions, MVC was lower in the neutral form with little forearm supination, suggesting that the neutral form reduces the risk of tennis elbow compared with the form with forearm supination. It was clarified that the elbow joint flexion angle markedly changes upon impact in the form with supination.

Acknowledgments

This study was supported by the Kitasato University Research Grant for Young Researchers No. 2014-4008. We are grateful to Kensuke Handa, Minoru Hasegawa and Kiyoshi Mabuchi for their support.

References

1. Nirschl RP, Ashman ES. Elbow tendinopathy: tennis elbow. Clin Sports Medicine. 2003; 22: 813-836.
2. King AM, Kentel BB, Mitchell RS. The effects of ball impact location and grip tightness on the arm, racquet and ball for one-handed tennis backhand groundstrokes. J Biomech. 2012; 45: 1048-1052.
3. Almekinders LC, Temple JD. Etiology, diagnosis, and treatment of tendonitis: an analysis of the literature. Med Sci Sports Exerc.1998; 30: 1183-1190.
4. Assendelft WJJ, Green SF, Buchbinder R, Struijs PAA, Smidt N. Extracts from concise clinical evidence - Tennis elbow. Br Med J. 2003; 327: 329-330.
5. Bjordal MJ, Lopes-Martins ABR, Joensen J, Couppe C, Ljunggren EA, Stergioulas A, Johnson IM.A systematic review with procedural assessments and meta-analysis of Low Level Laser Therapy in lateral elbow tendinopathy (tennis elbow). BMC Muscule Disorders. 2008; 75: 1-15.
6. Green S, Buchbinder R, Barnsley L, Hall S, White M, Smidt N. Non-steroidal anti-inflammatory drugs (NSAIDs) for treating lateral elbow pain in adults. The Couch Database System Rev. 2013.
7. DuToit C, Stieler M, Saunders R, Bisset L, Vicenzino B. Diagnostic accuracy of power Doppler ultrasound in patients with chronic tennis elbow. Br J Sports Med. 2008; 42: 572-576.
8. Kaminsky SB, Baker CL. Lateral epicondylitis of the elbow. Tech Hand Upper Limb Surg. 2003; 7: 179-189.
9. Poetert EP, Brody H, Dillman CJ, Groppel JL, Schultheis JM.The biomechanics of tennis elbow.Clin Sports Med.1995; 14: 47-57.
10. Giangarra CE, Conroy B, Jobe FW, Pink M, Perry J. Electromyographic and cinema-tographic analysis of elbow function in tennis players using single- and double-handed backhand strokes. Am J Sports Med. 1993; 21: 394-399.
11. Kelley JD, Lombardo SJ, Pink M, Perry J, Giangarra CE. Electromyographic and cinema-tographic analysis of elbow function in tennis players with lateral epicondylitis. Am J Sports Med.1994; 22: 359-363.
12. Mc Cue FC, Kulund DN. The Elbow wrist and hand. Toronto: The Injured Athlete, Lippincott, Philadelphia.1982.
13. Werner AR, Franzblau A, Gell N, Hartigan A, Ebersole M, Armstrong JT. Predictors of persistent elbow tendonitis among auto assembly workers. J Occup Rehabil. 2005; 15: 393-400.
14. Alizadehkhaiyat O, Fisher CA, Kemp JG, Vishwanathan K, Frostick PS. Assessment of functional recovery in tennis elbow. Journal of Electromyography and Kinesiology. 2009; 19: 631-638.
15. Elliott B. Biomechanics and tennis. British Journal of Sports Medicine, 2006; 40: 392-396.
16. Damsgaarda M, Rasmussena J, Christensena TS, Surmaa E, Mark de Zeea. Analysis of musculoskeletal systems in the Anybody Modeling System. Simulation Modelling Practice and Theory. 2006; 14: 1100-1111.
17. Nimbarte AD, Sun Y, Jaridi M, Hsiao H. Biomechanical loading of the shoulder complex and lumbosacral joints during dynamic cart pushing task. Applied Ergonomics. 2013; 44. 841-849.
18. RasmussenJ, Damsgaard M, Voigt M. Muscle recruitment by the min/max criterion-- a comparativenumerical study.J Biomech. 2001; 34: 409-415.
19. Nimura A, Fujishiro H, Wakabayashi Y, Imatani J, Sugaya H, Akita K. Joint capsule attachment to the extensor carpi radialis brevis origin: an anatomical study with possible implications regarding the etiology of lateral epicondylitis. The Journal of Hand Surgery American. 2014; 39: 219-225.
20. Tubiana R, Masquelet AC, McCullough CJ (ed). Elbow: Lateral approaches. In: Atlas of surgical exposures of the upper and lower extremities, Martin Dunitz, London. 2000.
21. Nirschl RP, Pettrone FA. Tennis elbow. The surgical treatment of lateral epicondylitis. Journal of Bone & Joint Surgery American. 1979; 61: 832-839.
22. Yu JJ. Comparison of lower limb muscle activity during eccentric and concentric exercises in runners with achilles tendinopathy. Journal of Physical Therapy Science. 2014; 26: 1351-1353.
23. Pappas AM. Elbow Problems Associated with Baseball During Childhood and Adolescence. Clinical Orthopaedics& Related Research. 1982; 164: 223-235.