

H-Type Tracheoesophageal Fistula
in New Born. How to Avoid Delay in
Diagnosis?Rachid Khemakhem^{*1}, Muhammad Riazulhaq¹ and Magdi Cherbini²¹Department of Pediatric Surgery, King Faycal medical complex, Saudi Arabia²Department of radiology, King Faycal medical complex, Saudi Arabia

Article Information

Received date: May 16, 2016

Accepted date: Jun 01, 2016

Published date: Jun 03, 2016

*Corresponding author

Rachid Khemakhem, Department of
Pediatric Surgery, King Faycal medical
complex, Saudi Arabia, Email: kakoum_
rochdi@yahoo.frDistributed under Creative Commons
CC-BY 4.0Keywords Tracheo-Esophageal Fistula;
H-Type; Esophagus

Abstract

H type oesotracheal fistula is a rare congenital malformation of the esophagus that poses difficult problems of diagnosis that can sometimes be delayed till the adulthood. Multiple radiologic investigations are necessary to make diagnosis. Surgical repair is indicated once diagnostic done.

A 2 days old male baby was admitted in NICU for respiratory distress. History start since birth with caught, cyanosis and tachypnea after each oral feeding. A gastric tube was inserted and chest X ray shows it in the stomach. Congenital trachea-esophageal fistula was suspected and oesophagram was done confirming this diagnosis. Surgical repair was performed through cervical incision and post-operative evolution was simple.

Clinical futures, pathogenesis and management of this pathology are discussed.

Introduction

H-TYPE tracheo-esophageal fistula is one of the less frequent variants of congenital esophageal malformations. The clinical manifestations are variables; recurrent respiratory symptoms such as choking, aspiration during feeding with cyanosis and abdominal distension. The diagnosis of this disorder is sometimes difficult and some cases may remain undiagnosed for many years. In this paper, we are reporting a case of H-type TEF diagnosed within few hours after birth.

Case Report

A full term male baby weighing 3.7 kg was born through normal vaginal delivery. He became distressed after every feeding with choking, tachypnea, cyanosis and episodes of abdominal distention. He was admitted at the age of 2 days in NICU with the diagnosis of bronchopneumonia. No associated anomalies have been seen. OGT pass easy and thoraco-abdominal ray show the OGT in place with air distension of the stomach and right mid lobe pneumonia. Patient was kept NPO in semi-setting position and IV antibiotic started. Tracheo-esophageal fistula was suspected and subsequent esophagram with 8Fr or gastric tube was done showing a H-TEF in the upper esophagus (T2-T3 level) with an intact esophagus from the pharynx to the stomach (Figure 1).

This patient was operated through a right cervical incision. By carefully palpation of the catheter, esophagus was identified than TEF dissected and closed on both the tracheal and esophageal ends with interrupted polydioxanone sutures and an omohyoid muscle flap was interposed in between to prevent recurrence of the fistula. Feeding was started on day 3 PO through the OGT than oral at day 10 PO. During a follow-up period of 6 months, patient was asymptomatic and no recurrence of TEF was detected

Discussion

The original description of congenital H-type Trachea-Esophageal Fistula (H-TEF) was done by Lamb more than a century ago and the first surgical repair of such a defect was reported by Imperatori in 1939 [1]. Despite that, this relatively uncommon congenital anomaly continue to be difficult to identify and sometimes, challenging to repair [2].

H-TYPE tracheo-esophageal fistula is one of the less frequently encountered variants of congenital tracheo-esophageal fistula. It is the Gross E type of Esophageal Atresia (EA) and constitutes 4% of all EA cases [3,4].

The etiology is not known with certainty, but it is thought to result from incomplete separation of the trachea and esophagus in the early embryologic development.

Due to the oblique path of the fistula from the trachea (carina or main bronchi) to the esophagus, anatomically at the level of the neck root (C7-T1), N-type TEF is more frequently encountered than H-type [3,4].

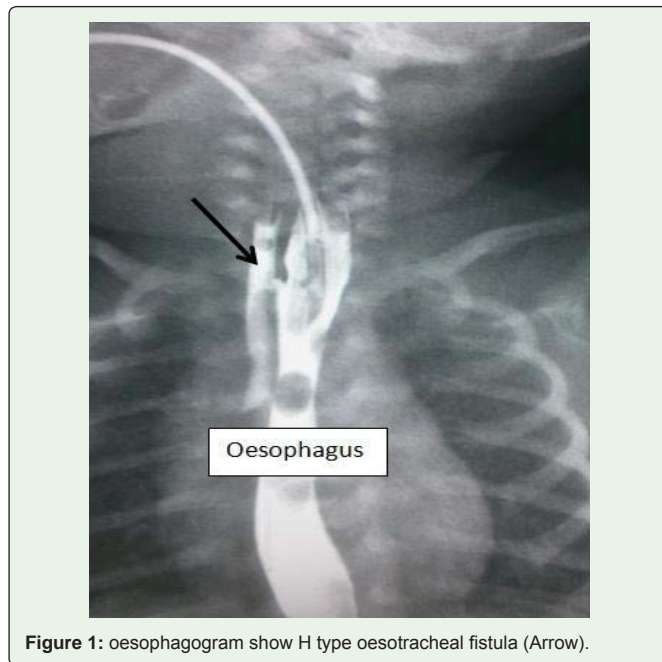


Figure 1: oesophagogram show H type oesotracheal fistula (Arrow).

Classical triad in the patients with H-type TEF are the choking episodes during ingestion recurrent lower airway infection and abdominal distension.

H-type TEF is associated with other malformations in about 30% of cases, including VACTERL/VATER, CHARGE syndrome, Goldenhar's syndrome, esophageal stenosis, and syndactyly. The index cases have none of these associations [3]

Many diagnostic methods have been advocated for diagnosis of H type fistulae [3].

Classical esophagram is usually a reliable method to identify this anomaly, though often difficult, enquiring multiple attempts for confirmation of the diagnosis [3].

MRI and radionuclide imaging using Tc-99m sulfur colloid have been also suggested for diagnosis and localization of a H-TEF especially in critically ill premature infants.

Careful assessment of trachea and esophagus by endoscopic examination has been recommended as an important adjunct to surgical repair of H-TEF. Various techniques have been described to reveal fistula during endoscopy, such as air leak test, methylene blue injection, etc. This method has the advantage of being diagnostic, in that it establishes the level of the fistula allows placement of a catheter across the fistula and identifies an additional fistula [5].

Some time, it is necessary to repeat these investigations many times to make the diagnosis in case of high suspicion of H-TEF. Failure to identify this malformation, an unsatisfactory radiological method and similar symptoms related to associated anomalies may cause delay in diagnosis and lead to fatality [3,4].

Both surgical and endoscopic management of the condition have been described.

Endoscopic management using fibrin occlusion, sclerosation, electrocautery, laser coagulation has a lower morbidity and mortality

rate compared to the surgical approach, but is associated with high recurrence rate so, the surgery remains the mainstay treatment of the H type trachea-esophageal fistula [3,6].

Since the fistula is located above the level of T2 in almost 70% of cases, repair of H-TEF is typically performed through cervical route along the anterior border of sternocleidomastoid muscle. The recurrence laryngeal never must be identified and carefully preserved [7].

However, if fistula is below the level of T2 and T3 or if a damaged lung should be managed with simultaneous pulmonary resection, a thoracotomy operation is suggested. A Thoracoscopic approach has also been advocated [4,6,8].

Many surgeons nowadays recommend preoperative or intraoperative bronchoscopic guide wire trans-fistula placement. This strategy has the advantage to facilitate per-operative localization of the fistula by palpation of the guide wire and preserve surrounding structures from extensive dissection. Instead of the vascular, Fogarty or ureteral catheters can be used [5].

Conclusion

The early diagnosis and treatment are essential to prevent the long-term debilitating respiratory symptoms associated with the fistula. In front of a baby with caught cyanosis after feeding and abdominal distension, H type congenital TEF must be excluded. Both radiological and endoscopic procedures are complementary in this mission with high index of suspicion.

Surgical repair is indicated once diagnostic done and can be performed by cervicotomie or thoracotomie.

References

1. Imperatori CJ. Congenital Tracheo-esophageal Fistula without Atresia of the Esophagus. Arch. Otolaryngol. 1939; 30: 352.
2. Riazulhaq M, Elhassan E. Early recognition of H-type tracheoesophageal fistula. APSP J Case Rep. 2012; 3: 1-3.
3. Aditya Pratap Singh, D. P. Morya, Javed Salam Ansari, Arvindshukla, RajlaxmiPardeshi, VeenitaChaturvedi and all. Case Report – Late Presentation of Congenital H – Type Tracheoesophageal Fistula. J Dent Med Sc. 2014; 13: 5-7.
4. Hajjar WM, Iftikhar A, Rahal SM, Sami A. Al Nassar. Congenital Tracheoesophageal fistula: A rare and late presentation in adult patient. Ann Thorac Med. 2012; 7: 48-50.
5. Antabak A, Luetic T, Caleta D, Romic I. H-type Tracheoesophageal Fistula in a Newborn: Determining the Exact Position of Fistula by Intra-operative Guide wire Placement. J Neonat Surg. 2014; 10: 36-38.
6. Chang-hua He, Qing Zhang, Mei Liu, Wei-zheng Wang, An-hua Xiao, Xu-yan Zuo, et al. Endoscopic treatment of congenital Tracheoesophageal fistula using submucosal resection and closure by clip. Can J Gastroenterol. 2012; 26: 247-248.
7. Killen DA, Greenlee HB. Transcervical Repair of H-Type Congenital Tracheoesophageal Fistula: Review of the Literature. Ann Surg. 1965; 162: 145-150.
8. Salgaonkar PH, Sharma PC, Chhakravarty N, Ravindra Ramadwar, Rajiv Mehta, Deepraj S Bhandarkar. Thoracoscopic repair of congenital trachea-esophageal fistula manifesting in an adult. J Minim Access Surg. 2014; 10: 204-206.