

Acute Appendicitis: A Very Short Tale

Maija Cheung, Muriel Cleary and Doruk Ozgediz

Department of Surgery, Yale University School of Medicine, New Haven, CT, USA

Article Information

Received date: Jun 06, 2017

Accepted date: Jul 10, 2017

Published date: Jul 11, 2017

*Corresponding author

Maija Cheung, Department of Surgery,
Yale University School of Medicine,
Tel:+1-802-989-8132;
Email: maija.cheung@yale.edu

Distributed under Creative Commons
CC-BY 4.0

Keywords Appendicitis; appendiceal
length; appendiceal agenesis; stump
appendicitis

Abstract

There is a wide range of anatomical variation in appendiceal length reported in the literature despite the appendix achieving its adult proportions at approximately 3 years of age. Our seven year-old patient had acute appendicitis with a 1cm appendix well outside of the normal range. This variation should be kept in mind as it may impact imaging and treatment of acute appendicitis in special circumstances.

Case Report

A 7 year old 21 kg healthy boy presented with abdominal pain concerning for acute appendicitis. The patient and family reported pain for 24 hours with anorexia, nausea, pain with movement, and fever to 101F. He was given Motrin and his pediatrician then sent him to the Emergency Department for further evaluation.

He was born at thirty-five weeks gestation via spontaneous vaginal delivery, met all his developmental milestones, was up to date on his immunizations and was a generally healthy child. On arrival to our emergency room, he had a temperature of 100.4, heart rate of 126, respiratory rate of 24, and blood pressure of 94/47. He appeared fatigued and had a non-distended but diffusely tender abdomen with voluntary guarding in the bilateral lower quadrants. There were no scars. Labs revealed a leukocytosis of 15.6 and an abdominal ultrasound was unable to see the appendix. Multiple loops of thickened small bowel were seen in the right lower quadrant as well as free fluid with debris. Given his history, abdominal exam, and imaging, perforated appendicitis was suspected, and laparoscopy and possible appendectomy was planned. He was resuscitated with IV fluids and administered IV ceftriaxone and metronidazole prior to surgery.

Laparoscopy revealed gross peritonitis with purulence throughout the abdomen, especially in the right lower quadrant and the pelvis, though no frank stool was seen. The bowel loops were dilated and injected and the cecum was clearly visible in the right lower abdomen.

The terminal ileum was inflamed and the veil of Treves was thickened and draped over what appeared to be the appendiceal base at the confluence of the taenia coli. This was carefully dissected out and a tubular structure was clearly visualized entering the cecum. The structure resembling the appendix was very short (1-1.5 cm). Its tip was very inflamed but no frank hole was seen. Nonetheless, given its very short length, we were concerned that it may have perforated into several pieces. Further dissection along the mesentery of the terminal ileum and along the pelvic sidewall, however, did not reveal any additional appendiceal fragments. Its appearance was akin to "stump appendicitis" but in a patient who had never previously had abdominal surgery. The terminal ileum was run proximally for >2 feet and nothing unusual was seen aside from the injected and secondarily inflamed bowel. The cecum and right colon were mobilized to nearly the level of the hepatic flexure, and showed no fragments of appendix or abnormal tissue.

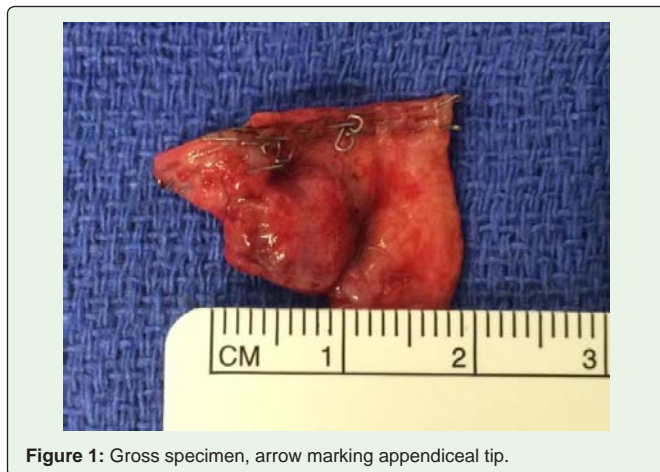

Figure 1: Gross specimen, arrow marking appendiceal tip.

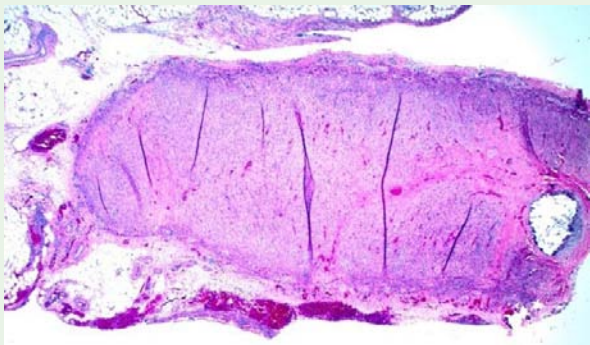


Figure 2: Pathology slide showing entire intact appendix thickened wall and inflammatory changes consistent with acute appendicitis.

The base of the short appendix appeared viable and amenable to stapling. A window was therefore created at the base of the appendix and was stapled across cleanly using an Endo-GIA stapler. The mesoappendix was then divided using another stapler load and the specimen was removed from the abdomen. It was diminutive but grossly had a lumen and appeared consistent with appendiceal tissue. The abdomen was then irrigated and suctioned and the incisions closed. He recovered uneventfully and was discharged home three days post-operatively. Although there was not a gross hole visualized in the appendix, due to the degree of peritonitis and purulence in the abdomen he was instructed to complete a 7-day course of oral antibiotics.

Pathology was consistent with acute appendicitis and peri-appendicitis and an intact entire appendix measuring 1cm in length and 0.5 cms in diameter was present in the specimen. (Figures 1 and 2).

Discussion

The appendix is a thin, compressible diverticulum arising from the inferior tip of the cecum lined with colonic epithelium and interspersed submucosal lymphoid follicles. In neonates and infants the cecum is tapered and the appendix is funnel-shaped making it less prone to obstruction. The appendix assumes its adult conical shape by approximately 1 to 2 years of age. It is hypothesized that the anatomic shape and the less prominent lymphoid tissue along with the soft infant diet contribute to the lower incidence of appendicitis in this age group especially compared to the late teenage years and the maximal lymphoid follicle size at that point in development and the epidemiological finding of the highest incidence of appendicitis [1].

There is a wide range of anatomical variation in both location and length reported in the literature; in neonates the average 4.5cms [2] and in adults 8-10 cms with a range of 2-20cms [3-5]. Congenital absence of the appendix has been reported in 1/100,000 operations performed for suspected appendicitis with possible causes including congenital agenesis, congenital atresia, rudimentary appendix resembling a tubercle, and auto-amputation following torsion or infection [6].

Following an initial growth period during early infancy up to approximately 3 years the appendix achieves its adult proportions and does not continue to grow throughout childhood. Mean lengths for the group to be 3.97cms (\pm 1.61 cms), in those under 3 years,

6.63cms (\pm 1.53cms) in ages 3-9, 6.37 cms (\pm 2.13cms) in ages 9-13 and 6.88 cms (\pm 1.82cms) in ages greater than 13 years [7]. These values combined with no other reports in the literature suggest that our patient's small appendix falls well outside the typical range.

Some studies have sought to determine if appendiceal length correlates with increased risk of appendicitis. One study showed that appendiceal lengths of 4-10cms were more frequently complicated by acute appendicitis with >10cms and <4cms less prone to appendicitis [8]. The idea that a short appendix may be less prone to appendicitis has been supported by studies looking at stump appendicitis after appendectomy. The exact incidence of stump appendicitis is unknown however some studies quote an incidence of 1 in 50,000 cases [9,10]. Other studies suggest that although stump appendicitis may not be that common, if it does develop it can present more frequently with perforation [11-13].

Currently there is no standard approach for the management of stump appendicitis, some favoring completion appendectomy and others recommending non-operative treatment with occasional interval stump appendectomy [14]. However literature does suggest that leaving the appendix stump less than 5mm reduces the risk of stump appendicitis [9].

When encountering a short appendix or in the case of stump appendicitis basic steps should be taken to confirm that the appendix is in fact being removed in its entirety. The pelvic sidewall should be explored, the colon mobilized to ensure there is no retrocecal component, and an endloop may need to be used as opposed to a stapler in cases of extremely short appendices if a stapler is not able to be fired cleanly across the base of the caecum.

In this case due to the unusually short appendix, we did question intraoperatively whether we could be mistaken that the appendix could be so short however review of the literature and our gross specimen showing the entire appendix confirm the finding most likely due to agenesis or atresia.

Conclusion

There is a wide range of anatomical variation in appendiceal length reported in the literature despite the appendix achieving its adult proportions after approximately 3 years of age. In this 7 year old child, a 1cm appendix is well outside of the normal variation and such variation should be kept in mind when performing imaging studies and during surgery as it can have clinical implications. Additionally, although a short appendix may be less prone to appendicitis it may more frequently present with perforation and delays in diagnosis due to inability to visualize the appendix can result in increased operative difficulty and increased patient morbidity.

References

1. Rothrock SG, Pagane J. Acute appendicitis in children: emergency department diagnosis and management. *Ann Emerg Med* 2000; 36: 39-51.
2. Buschard K, Kjaeldgaard A. Investigation and analysis of the position, fixation, length and embryology of the vermiform appendix. *Acta Chir Scand*. 1973; 139: 293-298.
3. Park NH. Ultrasonography of normal and abnormal appendix in children. *Wjr*. 2011; 3: 85-91.
4. Collins dc. 71,000 human appendix specimens. A final report, summarizing forty years' study. *Am j proctol* 1963; 14: 265-281.

5. Alzaraa A, Chaudhry S. An unusually long appendix in a child: a case report. *Cases J.* 2009; 2: 7398.
6. Maitra TK, Roy S, Mondal SK, Mahjabin S. Absent Appendix. *Bangladesh Critical Care Journal.* 2013; 1: 109-110.
7. Searle AR, Ismail KA, MacGregor D, Hutson JM. Changes in the length and diameter of the normal appendix throughout childhood. *Journal of Pediatric Surgery* 2013;48:1535-1539.
8. Pickhardt PJ, Suhonen J, Lawrence EM, Muñoz del Rio A, Pooler BD. Appendiceal length as an independent risk factor for acute appendicitis. *Eur Radiol.* 2013; 23: 3311-3317.
9. Hendahewa R, Shekhar A, Ratnayake S. The dilemma of stump appendicitis -A case report and literature review. *International Journal of Surgery Case Reports.* 2015; 14: 101-103.
10. Mangi AA, Berger DL. Stump appendicitis. *Am Surg.* 2000; 66: 739-741.
11. Liang MK, Lo HG, Marks JL. Stump appendicitis: a comprehensive review of literature. *Am Surg.* 2006; 72: 162-166.
12. Hashmi KS, Wibberley H, Ahmed I, Soares L. Stump appendicitis: a relatively under-reported reality. *Case Reports.* 2013; 2013.
13. Leff DR, Sait MR, Hanief M, Salakianathan S, Darzi AW, Vashisht R. Inflammation of the residual appendix stump: a systematic review. *Colorectal Dis.* 2012; 14: 282-293.
14. Rios RE, Villanueva KMV, Stirparo JJ, Kane KE. Recurrent (stump) appendicitis: a case series. *Am J Emerg Med.* 2015; 33: 480.e1-e2.