

An Unusual Cause of Neonatal Intestinal
Obstruction: Left Paraduodenal Hernia

S Ammar*, M Jallouli, H Zitouni, M Ben Dhaou and R Mhiri

Department of Pediatric Surgery, Hedi Chaker Hospital, Tunisia

Article Information

Received date: Apr 01, 2016

Accepted date: May 13, 2016

Published date: May 16, 2016

*Corresponding author

Saloua Ammar, Department of pediatric surgery, Hedi Chaker Hospital, Tunisia,
Tel: 00 216 22 756065;
Fax: 00 216 74 241 384;
Email: salouaammar@gmail.com

Distributed under Creative Commons
CC-BY 4.0

Keywords Internal Hernia; Paraduodenal
Hernia; Intestinal Obstruction; Newborn

Abstract

Left paraduodenal hernia (LPDH) is a rare congenital anomaly usually diagnosed in adulthood. Less than 1% of all cases of small bowel obstruction are due to PDH. We present a case of LPDH in an 18-days-old female and emphasize on considering this uncommon diagnosis in newborns to prevent fatal complications.

Introduction

An Internal hernia (IH) is a protrusion of the bowel through a normal or abnormal orifice either the peritoneum or the mesentery [1]. Major types of IH are paraduodenal (53%), pericecal (13%), foramen of Winslow (8%), transmesenteric and transmesocolic (8%), intersigmoid (6%), and retroanastomotic (5%) [2]. Internal hernia account for 0,2 to 0,9% of all cases of intestinal obstruction [2,3]. A literary research on pubmed between 1980 and 2015 indicated less than 100 cases of intestinal obstruction secondary to left paraduodenal hernia LPDH [4]. The average age at diagnosis is 38.5years [3]. Few pediatric cases have been reported in the litterature [1,3,5] and, to the best of our knowledge, neonatal acute intestinal obstruction caused by a left paraduodenal hernia has not been described before.

Case Report

An 18-day-old female with no medical history presented at the emergency department with isolated alimentary vomiting that became bilious over the course of 3 hours. A physical examination revealed no sign of fever and a soft depressible abdomen without distension. Plain abdominal radiography showed a distended stomach without any hydroaeric levels, and abdominal sonography showed mesenteric vessels in the normal position without distension of the small bowel loops, no intussusception, and no intra-abdominal effusion. An upper gastrointestinal study was performed due to the lack of any indication of intra-abdominal catastrophe. This revealed that there was no flow of contrast after the third duodenum and that there was an unusual and suspicious structure located at the upper left quadrant of the abdomen. The patient's contrast enhancement was peripherally circumscribed and heterogeneous in the interior (figure.1).

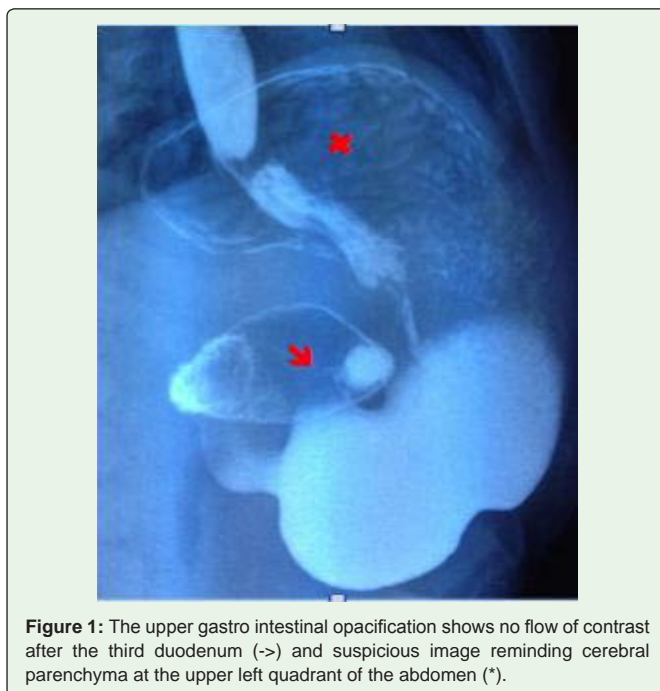


Figure 1: The upper gastro intestinal opacification shows no flow of contrast after the third duodenum (->) and suspicious image reminding cerebral parenchyma at the upper left quadrant of the abdomen (*).

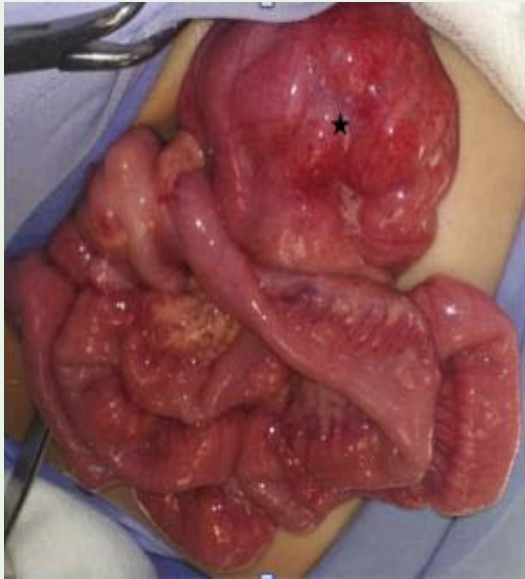

Figure 2: All jejunal loops were entrapped in a sac (*) situated on the left side of the fourth part of duodenum below the colon.

The patient underwent an exploratory laparotomy. Intraoperatively, a left paraduodenal hernia (PDH) was discovered with anomalous rotation (Figure 2). The initial adhesions were then liberated. The orifice of the herniated sac was found to be narrow, and the sac was divided to enlarge the opening before resection. The herniated bowel was healthy and there were no signs of ischemia; it was reduced and placed in the usual mesenteric position. The mesenteric defect was repaired and an appendectomy was performed. The patient recovered with no complications or further vomiting during a follow-up period of 2 years.

Discussion

IHs are uncommon hernias that result from an abnormal rotation of the midgut and variation in the peritoneal fixation. PDHs are the most common types of IH, accounting for between 30% and 50% of all cases [4]. They usually occur in adulthood and have non-specific clinical symptoms. PDHs range from being completely asymptomatic to chronic or acute, and can cause partial or complete small bowel obstruction. Small bowel loops may become entrapped within the herniated sac. The severity depends on the duration and reducibility of the hernia and the presence or absence of incarceration and strangulation [5,6]. PDH are associated with intestinal ischemia in 20% of cases [7]. The mortality for acute presentation ranges from 20% to 50% [1,7]. A diagnosis of PDH is imperative to avoid such complications.

The clinical diagnosis of PDH is often difficult; however, imaging studies could play an important role. X-rays may show a clustering of the small bowel loops in the upper left quadrant [8], while barium contrast studies may reveal small bowel encapsulation, dilated loops

within the upper quadrant of the abdomen, or a delayed flow of contrast at the point of obstruction [9]. In our case, no flow of contrast was detected after the third duodenum. At the same time, there was an unusual and suspicious object located at the upper left quadrant of the abdomen, which reminded us of the cerebral parenchyma. This object corresponded to a herniated sac containing clustered small bowel loops. Such findings should, therefore, draw attention to this unusual diagnosis. The differential diagnoses in this case were duodenal diaphragm, intestinal volvulus, or an obstruction of the small bowel intestine caused by extrinsic duodenal and loop compression.

In our case, a computed tomography (CT) scan was not requested, but CT images may show a cluster of dilated small bowel loops between the pancreatic body and the stomach to the left of the ligament of Treitz. There is usually a mass effect associated with the displacement of the posterior wall of the stomach, duodenojejunal flexure, and transverse colon [3].

Treatment for PDH is surgical and requires reduction of the hernia and closure of the defect. Intestinal malrotation must be treated at the same time. Bowel resection may also be needed in the presence of ischemia. Surgical approaches include exploratory laparotomy or laparoscopic repair; laparoscopic repair is recommended when strangulation or perforation is not suspected [4].

To conclude, PDH is an uncommon cause of neonatal small bowel obstruction, and it is imperative to diagnose this condition early. Surgery is the main treatment modality to prevent small bowel necrosis, which is associated with a fatal outcome.

References

1. Nam SH, Kim WK, Kim JS, Kim KH, Park SJ. Laparoscopic treatment of left paraduodenal hernia in two cases of children. *Int J Surg Case Rep.* 2012; 3: 199-202.
2. Akyildiz H, Artis T, Sozuer E, Akcan A, Kucuk C, Sensoy E, et al. Internal hernia: Complex diagnostic and therapeutic problem. *Int J Surg.* 2009; 7: 334-337.
3. Tainaka T, Ikegami R, Watanabe Y. Left paraduodenal hernia leading to protein-losing enteropathy in childhood. *J Pediatr Surg.* 2005; 40: 21-23.
4. Kabbani D, Salem A, Holloway DK. Paraduodenal herniation. An internal herniation in a virgin abdomen. *Int J Surg Case Rep.* 2014; 5: 1148-1150.
5. Hirata K, Kawahara H, Shiono N, Nishihara M, Kubota A, Nakayama M, et al. Mesenteric hernia causing bowel obstruction in very low-birthweight infants. *Pediatr Int.* 2015; 57: 161-163.
6. Blachar A, Federle MP. Internal hernia an increasingly common cause of small bowel obstruction. *Semin Ultrasound CT MR.* 2002; 23: 174-183.
7. Teng BP, Yamout SZ. Left paraduodenal hernia causing small bowel obstruction in an adolescent patient. *J Pediatr Surg.* 2009; 44: 2417-2419.
8. Kuzinkovas V, Haghighi K, Singhal R, Andrews NJ. Paraduodenal hernia: a rare cause of abdominal pain. *Can J Surg.* 2008; 51: 127-128.
9. Tong RSK, Sengupta S, Tjandra JJ. Left paraduodenal hernia: case report and review of the literature. *ANZ J Surg.* 2002; 72: 69-71.