

Accessory Urethra, Accessory Phallus
and Accessory Scrotum; Varied Clinical
ScenariosMohammed Joudi Aboud^{1*}¹Consultant pediatric Surgery, The Maternity and Child Teaching Hospital, Iraq

Article Information

Received date: Dec 15, 2016

Accepted date: Dec 28, 2016

Published date: Dec 30, 2016

*Corresponding author

Mohammed Joudi Aboud, Consultant pediatric Surgery, The Maternity and Child Teaching Hospital, Al Qadisiya, Iraq, Email: mohammedabud@yahoo.com

Distributed under Creative Commons CC-BY 4.0

Keywords Accessory; urethra; phallus; scrotum; Scenarios

Abstract

Introduction: We presented 4 cases managed and operated with varied clinical scenarios; accessory urethra, accessory phallus and accessory scrotum, the study encountered these rare anomalies describing our findings for both anatomical and morphological variations.

Methods: All studied cases were operated in single pediatric surgery unit. All workup was done on basis of clinical presentation accordingly. All patients arranged for chromosomal karyotyping and evaluation of SRY and ATL1 gene loci on X and Y chromosome respectively using polymerase chain reaction amplification PCR. All sites excised sent for histopathology.

Results: Case 1: An 8-months old infant was evaluated for a history of purulent discharge from the opening of the sinus in the midline pre pubic area on the dorsal radix of the penis. Case 2: A 3- days old baby was presented with a mass in the gluteal region with bisexual ambiguity. On evaluation, both vaginal structure and welldeveloped phallus (small penis attached parasitic twin caudally) were present. Case 3: A 4-months old male infant presented with caudal mass (cystic perineal structure) grossly resembling testicle with well prominent phallus covering the anal opening. Case 4: A 2-year old male baby presented with a neighboring ipsilateral bulging peduncular perineal mass resembling phallus measuring 4.7 cm in length and 1.3 cm in width with narrow meatus and a history of dripping urine from this phallus like.

Conclusion: Crucial workup must be submitted including clinical, radiological, chromosomal karyotyping and cytogenetic study to asses and resolve such scenarios.

Introduction

The male genitourinary system developed in complex process. Different anomalies of the male urethra exist, either as isolated or in combination with other disorders as syndrome manifestations [1]. Congenital anomalies of the urethra in boys usually involve anatomic abnormalities of the penis and vice versa [2]. These anomalies presented with various clinical expressions. Anatomic variations have been identified in literatures including, the accessory urethra, epispadic, hypospadic, normotopic or perineoanal [3]. Accessory phallic urethra has previously been described and may involve various genitourinary and anorectal malformations. Congenital prepubic sinus CPS is extremely rare despite the urethral duplication is a more often reported anomaly. The most important difference in these anomalies is that the CPS is not communicating with the urinary tract [4]. Congenital anomalies of the scrotum are uncommon, four categories of scrotal anomalies were reported in literatures, including penoscrotal transposition, bifid scrotum, ectopic scrotum, and accessory scrotum [5,6]. Among them, the accessory scrotums are extremely rare anomalies.

Aim

We here present 4 cases managed and operated in single pediatric surgery unit with varied clinical scenarios; accessory urethra, accessory phallus and accessory scrotum, the study encountered these rare anomalies describing our finding for both anatomical and morphological variations.

Materials and Methods

We here present 4 cases of accessory urethra (3 of them with accessory phallus) with varied clinical morphology forms, one case with congenital pre pubic sinus and 3 cases of parasitic a cardiac caudal twinning, were operated in single pediatric surgery unit at the Maternity and Child Teaching Hospital, Al Qadisiya, Iraq, from 2007 to 2015. All evaluated retrospectively with respect to age, clinical manifestations and management approach. All initial radiological assessment sonography (U/S) for any associated renal anomalies, sinogram, urethrography and Computerized Tomography Scan (CTS) with Magnetic Resonance Imaging (MRI) to evaluate neighboring structures, and any additional abnormalities in the spine or pelvic cavity, all workup was done on basis of clinical presentation accordingly. Diagnosis in all patients was set according to the appearance of external genitalia, cytogenetic analysis, and hormonal status. Ascertainment of the gonadal sex was made

based on the inability to determine the sex of one patient on a physical examination. All patients arranged for chromosomal karyotyping and evaluation of SRY and ATL1 gene loci on X and Y chromosome respectively using polymerase chain reaction amplification PCR. All sites excised sent for histopathology. Written informed consent was obtained from all the parents for publication or presentation of these data with accompanying images. The study was approved and authorized by the ethical committee at Al Qadisiya Health Office, the Ministry of Health, Iraq.

Results

Case 1

A 8-months old infant was evaluated for a history of purulent discharge from the opening of the sinus in the midline pre pubic area on the dorsal radix of the penis (Figure 1). History of twice medical consultation for abdominal screaming, vomiting with Urinary Tract Infection (UTI). Physical and laboratory findings were normal. Left renal ectopia (pelvic) was noticed by US study. Sino gram (conversely fistula graphy is useful for observing the extent of the lesion and its

communication with the urinary system) and urethrogram were conducted simultaneously and it there was no relationship between the urinary tract and the sinus, in our case showed a prepubic sinus superficial to the pubis. Surgical exploration was done, about 3.5-4 cm-long sinus apparently ending as a fibrous tract at the anterior surface of the pubic symphysis (Figure 1, A-G). Histopathology revealed the sinus was lined with stratified squamous epithelium, pseudo and stratified columnar epithelium, accessory urethra was submitted accordingly.

Case 2

A 3-days old baby a product of caesarian section for consanguineous parent was presented with a mass in the gluteal region with bisexual ambiguity. On evaluation, omphalocele with anorectal malformation and bladder exstrophy (cloacal variant), both vaginal structure and well developed phallus (small penis attached parasitic twin caudally) were present, expressing white color discharge when squeezed. Asymmetrical shape of both buttocks on the posterior view when the neonate was upright. The skin fold of the left inner thigh had an asymmetrical lateral displacement due to

Table 1: clinical and karyotype findings of the 4 cases presented in our study.

Case	Type of anomaly	Age of presentation	Phenotype	Karyotype and cytogenetic analysis	Associated anomalies
1	congenital prepubic sinus, accessory urethra	8 months	male	46XY, SRY positive	left renal ectopia (pelvic)
2	caudal twinning with accessory phallus and urethra	3 days	bisexual ambiguity	46XX, SRY negative, ATL1 positive	ARM, cloaca, caudal a cardiac parasitic twin, omphalocele minor, atrial septal defect
3	accessory phallus and scrotum	4 months	male	46XY, SRY positive	right renal duplication (2 ureters with right vesicoureteral reflex)
4	Accessory phallus and urethra	2 years	male	46XY, SRY positive	Anterior ectopic anus, subcoronoal hypospadias, left retractile testicle

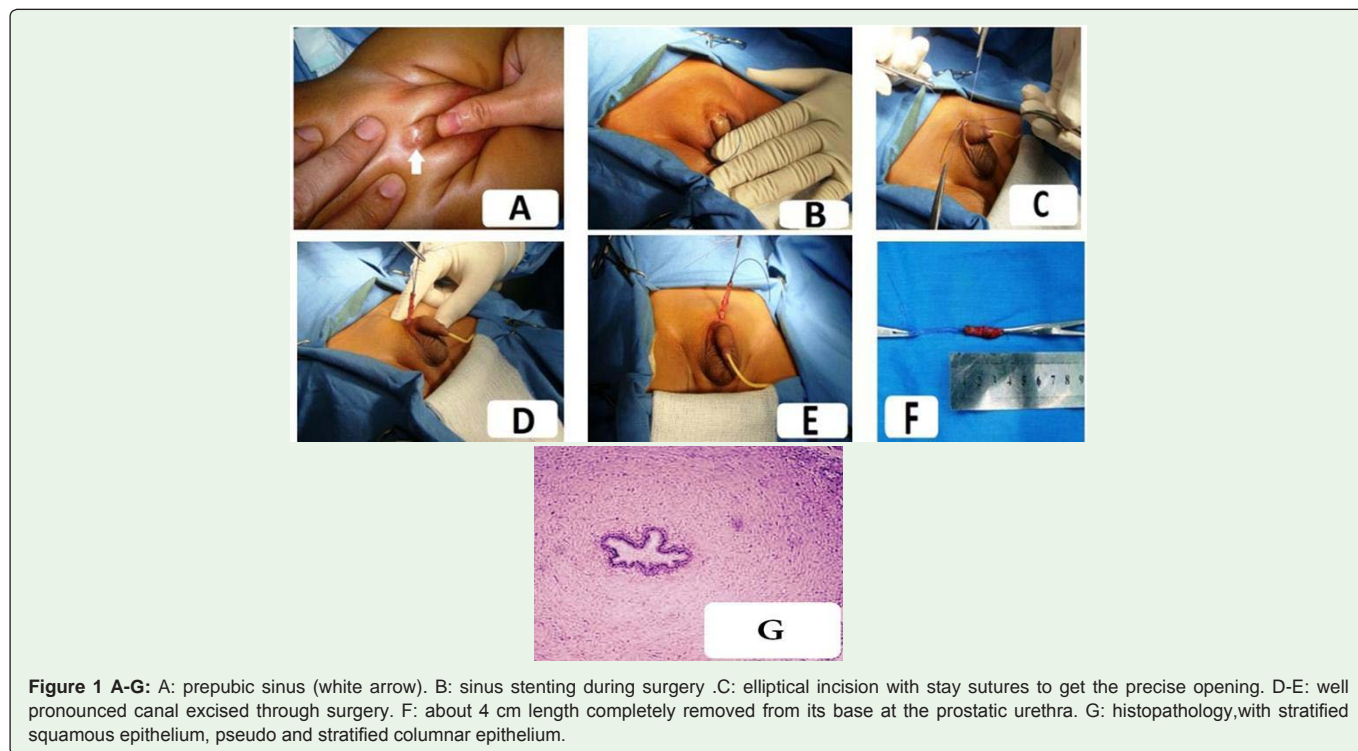


Figure 1 A-G: A: prepubic sinus (white arrow). B: sinus stenting during surgery .C: elliptical incision with stay sutures to get the precise opening. D-E: well pronounced canal excised through surgery. F: about 4 cm length completely removed from its base at the prostatic urethra. G: histopathology,with stratified squamous epithelium, pseudo and stratified columnar epithelium.

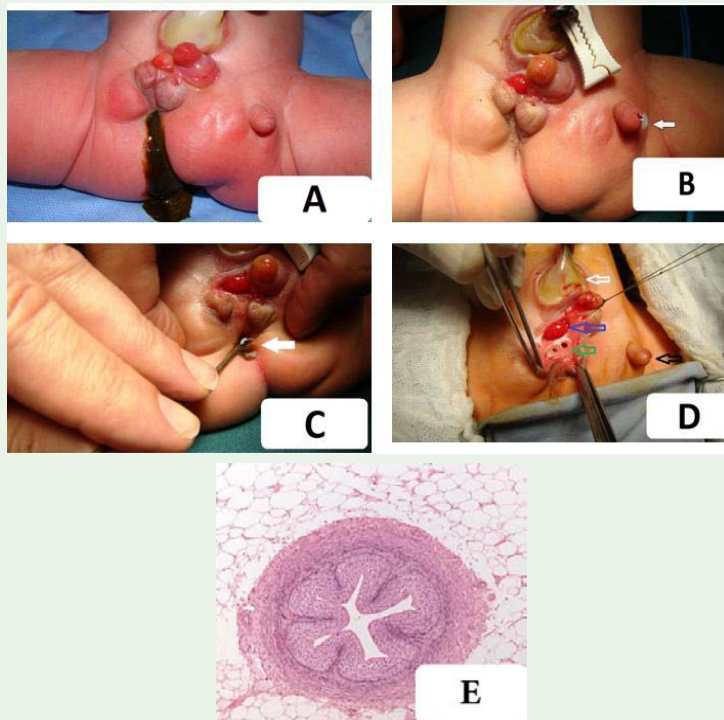


Figure 2 A-E: 46XX female, SRY negative with cloacal exstrophy, caudal twinning: A: associated ARM. B: accessory phallus shown with dripping of whitish discharge (white arrow).C: ARM, anal opening through a cloacal anomaly (white arrow). D: omphalocele, bladder exstrophy and vaginal opening created within the exstrophy variant (white, blue and green arrows respectively). E: histopathology, a centrally located rudimentary urethra within the excised parasitic lump lined by stratified columnar epithelium.

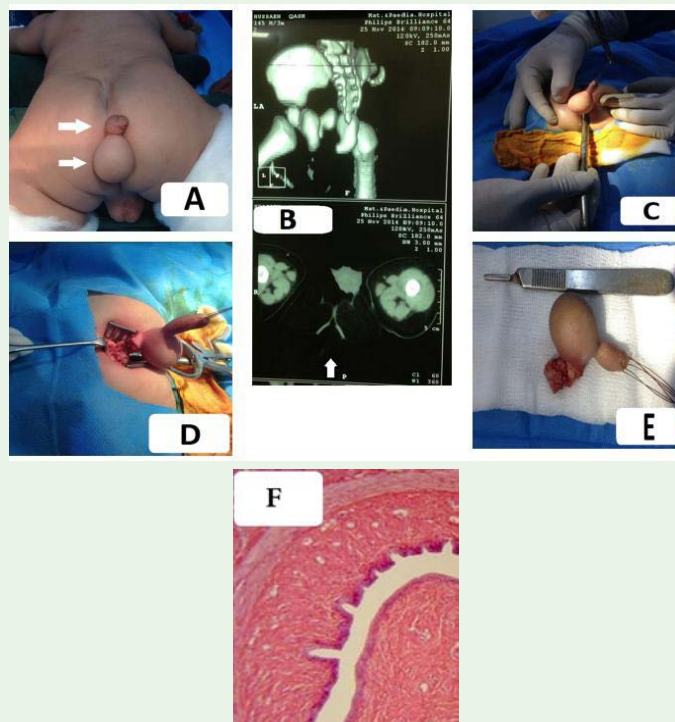


Figure 3 A-F: A: accessory phallus and scrotum covering anal opening. B: CTS have shown the caudal mass attachment to the perineal site (white arrow).C: anal opening beneath the mass. D-E: accessory phallus with scrotal like mass excised with the stalk attached to the coccygeal part. F: histopathology epidermis, dermis with sebaceous glands, sweat glands, multiple vascular channels and a centrally located rudimentary urethra.

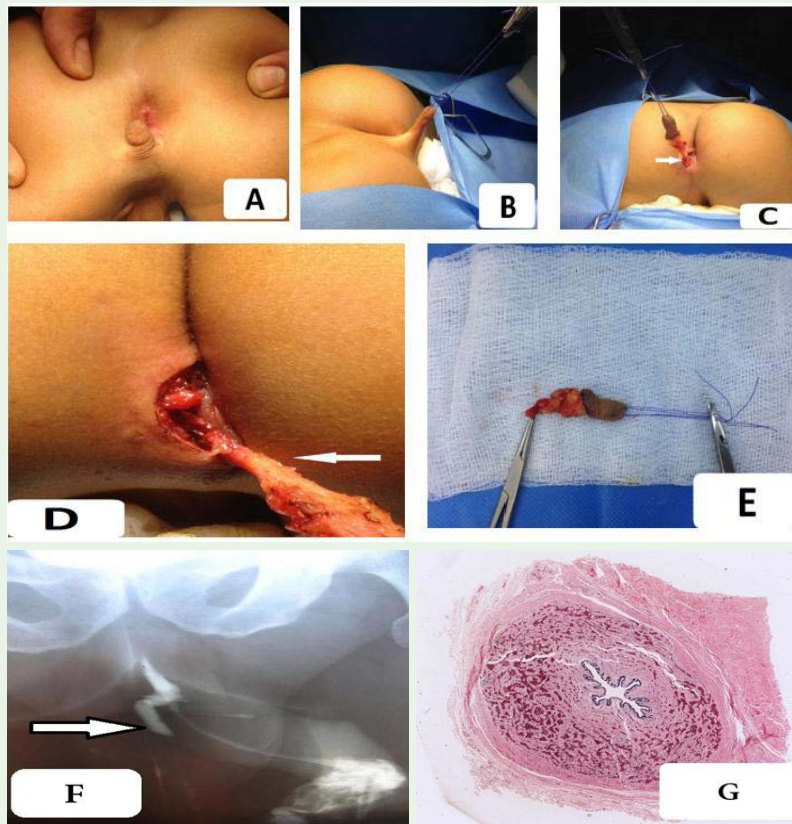


Figure 4 A-G: A: Accessory phalluses within the perineal part near the anal opening. B-C: about 4 cm external length and 5-6 cm sinus extended deeply (white arrows). D: sinus attached at its base with the native membranous urethra. F: fistulogram through accessory phallus stenting revealed obvious connection with the native prostatic urethra (white arrow). G: histopathology, large areas of stroma and cavernosum like vascular spaces surrounding the urethra lined by the transitional epithelium.

the perineal mass. Karyotype study revealed 46XX with negative SRY. This baby underwent surgical correction on 3rd day admission when fecal diversion using the sigmoid colon was constructed, at age of 6 months anoplasty and perineal mass was excised during one surgical session (Figure 2, A-E). Histopathology results showed transitional epithelium with variable amount of smooth muscle with evidence of testicular tissue (thick collagenous capsule on the outside, abundant of seminiferous tubules) and a centrally located rudimentary urethra within the excised parasitic lump lined by stratified columnar epithelium.

Case 3

A 4-months old male infant presented with caudal mass (cystic perineal structure) grossly resembling testis with well prominent phallus covering the anal opening. He is a first baby (a product of caesarian section) to close relative parent, the mother presented 5 years history of primary infertility, the pregnancy supported in early trimester with Gestanon tab. He has normal external male genitalia with bilateral normotopic testis. Surgery done at age of 5-month through a jack-knife position with excision of the whole mass (Figure 3, A-F). Histopathology revealed a parasitic testicular and phallic tissue like structures with epidermis, dermis with sebaceous glands, sweat glands, multiple vascular channels and a centrally located rudimentary urethra.

Case 4

A 2-year old male baby was consulted our outpatient clinic service with a sub coronal hypospadias, left retractile testicle, right hemiscrotum was normotopic and contained a normal testis with a neighboring ipsilateral bulging peduncular perineal mass resembling phallus measuring 4.7 cm in length and 1.3 cm in width with narrow meatus, there was history of dripping urine voiding from this phallus. Anal opening was anteriorly placed. Surgery done through a prone jack knife position, the accessory phallus was excised, well developed stalk (urethra like) connected with the prostatic urethra of the native phallus (Figure 4, A-G). Histopathology revealed a collection of the bundles of smooth muscles interspersed with large areas of stroma and cavernosum like vascular spaces surrounding the urethra lined by the transitional epithelium.

Discussion

Urethral duplication, CPS, accessory urethra, accessory phallus and accessory scrotum are rare anomalies with few cases reported to date, usually seen in males and often associated with genitourinary and gastro-intestinal anomalies [7]. Embryogenesis of such anomalies are not well understood and various hypothesis exist. The commonly quoted and accepted hypothesis for complete urethral duplication is that of Patten and Barry and is supposed to result from an abnormal relationship between the lateral folds of the genital tubercle and the

ventral end of the cloacal membrane [8,9]. Despite that all subtypes of urethral duplication need more embryological explanation. Regarding our first case with CPS, all such presentations were interpreted as a dorsal urethral duplication (Stephens Type 3), as no connections with the urinary system were detected. Soares et al. reported two patients with congenital prepubic sinus [10,11]. Because the histopathological examination demonstrated that the sinus was lined with stratified squamous epithelium in both cases, they advocated that the etiology of this entity is the midline defect which attributes the origin of the defect to a deficient cloacal membrane replacement by the lateral mesodermal folds as a bladder exstrophy variant. A complete excision of the sinus is required, as it may become symptomatic and potentially malignant later in life. Like our surgical approach, these lesions can be easily and completely treated by simple excisions.

Embryological background of our second case may arise from failure of fusion of mesodermal bands or growth of mesoderm around 2 urethral anlagen, duplication of cloacal membrane and defective mesenchymal proliferation around the cloacal membrane could explain the clinical presentations of our baby [12,13]. This is very rare anomaly with few cases reported to date. Superior vesicle fissure with diphallos urethra (in our case this associated caudal a parasitic twin) and ectopic bowel is a rare malformation which requires complete excision of accessory penis and correction of associated anomalies. VanderPutte found in his histopathological study of penis like structures and megalourethra in nonvirilized female fetuses and a newborn, these phallic structures had female features (clitoris like) with regard to the histogenesis of the corpora cavernosa and glans, as the fascia, septum, periurethral glands and penile raphe were absent. He explained his description for such a structure as a penis like clitoris, with the presence of a central urogenital canal (phallic urethra) as an essential morphological difference in comparison to the true enlarged clitoris [14-16].

In our third case, the presence of periurethral glands differentiates it from a penis like clitoris with testicular tissue encountered the accessory scrotum and the histological features confirmed it to be a true phallus with accessory testis. This finding with the presentation and histopathology background of the 4th case with accessory phallus may be happened belong Vilanova and Raventos description, both announced that pseudodiphallus is a normal penis associated with an indication or a rudiment of an atrophic penis existing independently of the normal penis [17-19]. Accessory pseudo scrotum and pseudodiphallus is a very rare anomaly. It could be present as a single isolated anomaly or with other congenital anomalies such as intestinal anomalies: imperforate anus, esophageal atresia, exstrophy of the bladder, vertebral anomalies, cloacal exstrophy, and scrotal anomalies [20-21].

There are some limitations to our study because of the rarity of such anomalies. Only 4 patients were identified over the 8-years period of this study. Our review was limited to those cases documented at our single center.

Conclusion

Despite of advances in knowledge and science, still few anomalies cannot be hypothesized as regards their embryogenesis. Our cases may enhance many crucial steps towards understanding and searching how these anomalies are affected and created, by signals

from the environment or genetic processing and the endocrine system during genitourinary development. Crucial workup must be submitted including clinical, radiological, chromosomal karyotyping and cytogenetic study to assess and resolve such scenarios.

Acknowledgement

The author expresses sincere gratitude to all the Pediatric Surgery Unit staff at the Maternity and Child Teaching Hospital, Al Qadisiya, Iraq, for their assistance. Thanks also go to Dr. Manal Mohammed Kadhim (assistant professor, clinical immunology) and Medical Microbiology and Clinical Immunology laboratory staff at the College of Medicine, Al Qadisiya University for their efforts to obtain the cytogenetic results and all colleagues in the radiology unit.

References

1. Woodhouse CR, Williams DI. Duplications of the lower urinary tract in children. *Br J Urol.* 1979; 51: 481-487.
2. Hynes PJ, Fraher JP. The development of the male genitourinary system: II. The origin and formation of the urethral plate. *Br J Plast Surg.* 2004; 57: 112-121.
3. Nasir AA, Abdur-Rahman LO, Olaoye I, Oyinloye AO, Bamigbola KT, Adeniran JO. Congenital prepubic sinus: a variant of epispadiac dorsal urethral duplication. *J Pediatr Urol.* 2013; 9: e82-85.
4. Karnak I, Senocak ME, Büyükpamukçu N, Hiçsönmez A. Rare congenital abnormalities of the anterior urethra. *Pediatr Surg Int.* 1997; 12: 407-409.
5. Bagul Abhay S, Sarathi Vijaya, Bokade CM. Urogenital sinus developmental anomaly with phallus and accessory phallic urethra presented as disorder of sex differentiation in female. *J Neonatal Surg.* 2014; 3: 15.
6. Mauch TJ, Albertine KH. Urorectal septum malformation sequence: insights into pathogenesis. *Anat Rec.* 2002; 268: 405-410.
7. Hollowel JG Jr, Witherington R, Ballagas AJ, Burt JN. Embryologic considerations of diphallos and associated anomalies. *J Urol.* 1977; 117: 728-732.
8. Park WH, Choi SO. An unusual urachal sinus with external opening in the midline suprapubic area. *J Pediatr Surg.* 2003; 38: E18-20.
9. Salih Somuncu, Fatma Caglayan, Murat Cakmak and Sevgi Ulusoy. Embryologic Preputial Sinus Remnant Mimicking Urethral Duplication. *Indian J Pediatr.* 2006; 73: 227-228.
10. Soares-Oliveira M, Juliá V, Aparicio LG, Morales L. Congenital prepubic sinus. *J Pediatr Surg.* 2002; 37: 1225-1227.
11. Chao MH, Chuang CJ, Chen KC, Chu CC, Chu JM. Unusual epithelium in a subpubic sinus. *Pediatr Surg Int.* 2002; 18: 494-495.
12. Effmann EL, Lebowitz RL, Colodny AH. Duplication of the urethra. *Radiology.* 1976; 119: 179-185.
13. Salle JL, Sibai H, Rosenstein D, Brzezinski AE, Corcos J. Urethral duplication in the male: review of 16 cases. *The Journal of urology.* 2002; 163:1936-1940.
14. Van der Putte SC. Penis like clitorises with megalourethras in nonvirilized female fetuses and a newborn. A histopathologic study and its bearing on their pathogenesis. *J Pediatr Surg.* 2009; 44: 2223-2229.
15. Chu SM1, Ming YC, Chao HC, Luo CC. An accessory labioscrotal fold associated with anorectal malformation in female neonates. *J Pediatr Surg.* 2009; 44: E17-19.
16. Macarthur M, Mahomed A. Rare association of female pseudohermaphroditism, phallic urethra, and posterior cloaca. *J Pediatr Surg.* 2006; 41: 576-579.
17. Vilanova X, Raventos A. Pseudodiphallia, a rare anomaly. *J Urol.* 1954; 71: 338-346.

18. Braga LH, Whelan K, DeMaria J, Pippi-Salle JL. Newborn with persistent cloaca presenting with accessory phallic urethra and ambiguous genitalia. *Urology*. 2011; 78: 680-683.
19. Stephens FD. Abnormal embryology-cloacal dysgenesis. In: *Congenital malformations of the urinary tract*. New York: Praeger Scientific. 1983; 22.
20. Gyftopoulos K1=, Wolffebuttel KP, Nijman RJ. Clinical and embryologic aspects of penile duplication and associated anomalies. *Urology*. 2002; 60: 675-679.
21. Ito M, Hashizume K, Kanamori Y. New phenotype of accessory scrotum with perineal lipoblastoma: coexistence of midperineal and lateral accessory scrotums. *Int J Urol*. 2004; 11: 125-127.