

Thoracoscopic Repair of Recurrent Tracheo-Esophageal Fistula (TEF) Following Failed Primary Open Repair for Congenital Esophageal Atresia with TEF

Tse-Yu Chen¹, Sheng-Yang Huang^{1,2}, Hou-Chuan Chen¹ and Chia-Man Chou^{1,2*}

¹Department of Surgery, Taichung Veterans General Hospital, R.O.C, Taiwan

²College of Medicine, National Yang-Ming University, R.O.C, Taiwan

Article Information

Received date: Mar 14, 2017

Accepted date: Apr 11, 2017

Published date: Apr 13, 2017

*Corresponding author

Chia-Man Chou, Division of Pediatric Surgery, Department of Surgery, Taichung Veterans General Hospital, National Yang-Ming University, No. 1650, Sec. 4, Taiwan Boulevard, Taichung 40705, Taiwan, R.O.C; Tel: +886-4-23592525; ext.5182; Fax: +886-4-23741323; Email: cmchou@vghtc.gov.tw

Distributed under Creative Commons CC-BY 4.0

Keywords Recurrent tracheo-Esophageal Fistula (TEF); Thoracoscopic repair

Abstract

Thoracoscopic repair in Esophageal Atresia (EA) with or without a Tracheo-Esophageal Fistula (TEF) has been proven an effective and safe technique with minimal complications compared to open thoracotomy, such as chest wall deformities, scoliosis...etc. We present a case of recurrent TEF after open repair of EA with distal TEF that was successfully repaired by Thoracoscopic surgery.

Introduction

Tracheo-Esophageal Fistula (TEF) is a congenital disease that can be treated with thoracotomy, Thoracoscopy, or an endoscopic approach [1,2]. The recurrence rate of TEF following repair of Esophageal Atresia (EA) with a TEF is 5%-10% and can be difficult to manage [3].

Case Report

A 4-month-old female infant was admitted to the outpatient clinic and presented with vomiting and poor feeding for weeks. She was born at 35 weeks of gestation with a birth weight of 1900 g to a secundigravida. Neither antenatal anomaly nor perinatal insult was noted. She underwent open repair for EA with TEF in a local hospital when she was 2 days old. After the operation, she tolerated oral feeding well without easy choking or vomiting and was discharged 1 month later. She had been well until feeding problems developed approximately 2 months after the operation. Post-operative esophageal stricture was highly suspected, and she was admitted to our ward.

Upon physical examination, right posterolateral thoracotomy scar, soft abdomen, normal bowel sounds, and clear breathing sounds were noted. Esophagography showed normal contrast passage to stomach, but contrast media leakage to the trachea was found [Figure 1 (a)]. Panendoscopy

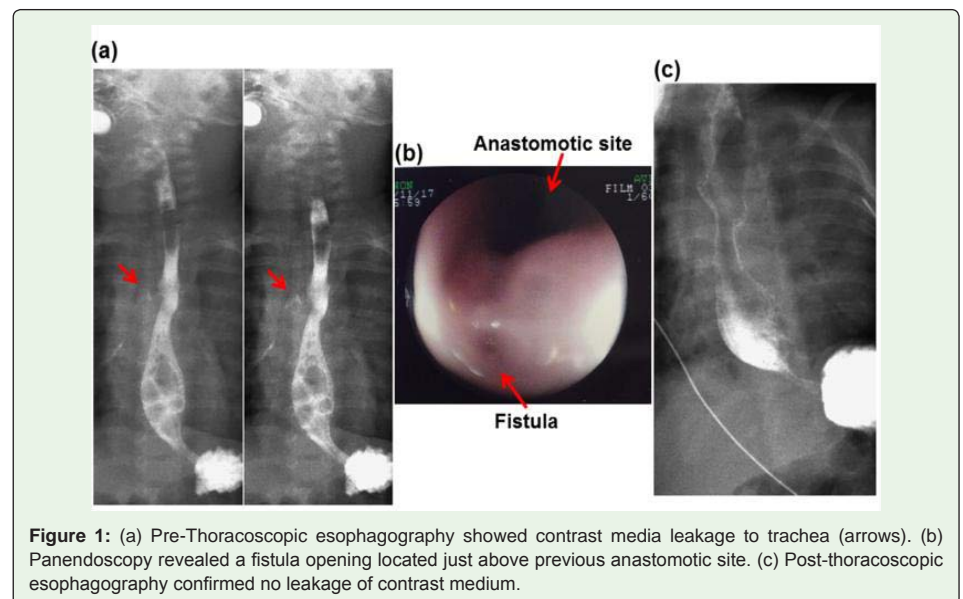
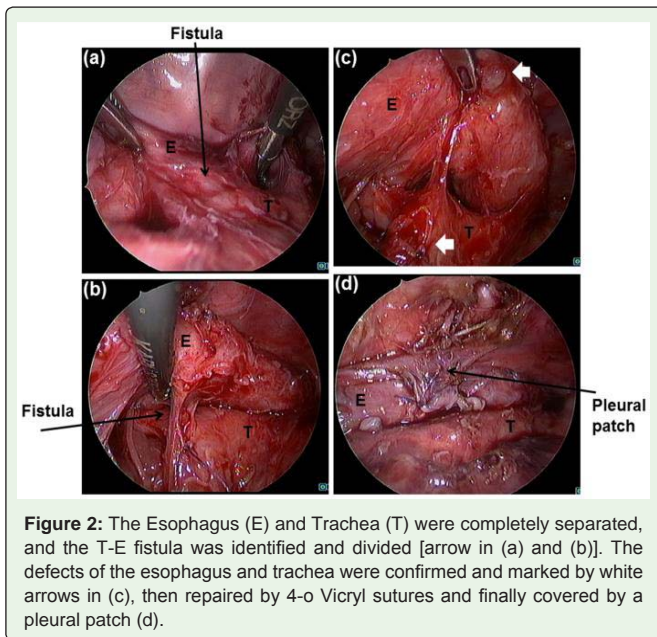


Figure 1: (a) Pre-Thoracoscopic esophagography showed contrast media leakage to trachea (arrows). (b) Panendoscopy revealed a fistula opening located just above previous anastomotic site. (c) Post-thoracoscopic esophagography confirmed no leakage of contrast medium.



confirmed the diagnosis of a recurrent TEF at the carina level above previous anastomotic site [Figure 1 (b)]. She received Thoracoscopic repair of the recurrent TEF. The operation was performed under general anesthesia with tracheal intubation and a bronchial blocker. She was placed in a 45° prone position, and three ports were used. A 5 mm camera port was inserted below the scapular tip at the posterior axillary line, and two 3 mm working ports were inserted above and below the first port in the mid-axillary line. The operative photos of Thoracoscopic surgery are shown in Figure 2. Orogastric tube feeding was initiated on the 2nd Post-Operative Day (POD 2), followed by oral feeding on POD 11. Esophagography performed on POD 11 showed no leakage of contrast medium [Figure 1 (c)]. The patient was discharged on POD 15.

Discussion

Diagnosis and management of recurrent TEF may be difficult and complex. Moreover, most children have respiratory and/or feeding problems that lead to the diagnosis.³ Prematurely born children (< gestation age 35.4 weeks) and those with low birth weight (5th-10th percentile of estimated birth weight), tracheal repair, leaking after primary repair, or missing primary repairs may develop recurrent or residual TEF [3,4].

The optimal approach for repairing recurrent TEF remains unclear; however, some have considered open surgery the standard management [4]; moreover, increasing evidence supports endoscopic procedures to be safe and effective for managing recurrent TEF, with a 60%-90% success rate with at least two attempts [3]. Thoracoscopic repair of recurrent TEF, although rarely mentioned in the current literature, can be a viable approach. Being minimally invasive, Thoracoscopic repair of TEF provides comparable perioperative outcomes to open surgery, as well as low surgical trauma and improved cosmetics. Furthermore, it provides excellent anatomical visualization compared with the limited operative window in an open surgery [1,2,5]. However, it is rarely mentioned in the treatment of recurrent cases. As a result, further studies are needed to establish the safety and efficacy of Thoracoscopic repair of TEF for treating recurrent TEF.

Conclusion

We successfully repaired a case of recurrent TEF through Thoracoscopic surgery after a failed primary open repair. Thoracoscopic repair for failed primary repairs of congenital TEF is not a standard technique; however, our experience demonstrated that Thoracoscopic repair could be a safe and effective alternative.

References

1. Borruto FA, Impellizzeri P, Montalto AS, Antonuccio P, Santacaterina E, Scalfari G, et al. Thoracoscopy versus thoracotomy for esophageal atresia and tracheoesophageal fistula repair: review of the literature and meta-analysis. *Eur J Pediatr Surg.* 2012; 22: 415-419.
2. Dingemann C, Ure BM. Minimally invasive repair of esophageal atresia: an update. *Eur J Pediatr Surg.* 2013; 23: 198-203.
3. Smithers CJ, Hamilton TE, Manfredi MA, Rhein L, Ngo P, Gallagher D, et al. Categorization and repair of recurrent and acquired tracheoesophageal fistulae occurring after esophageal atresia repair. *J Pediatr Surg.* 2017; 52: 424-430.
4. Koivusalo AI, Pakarinen MP, Lindahl HG, Rintala RJ. Revisional surgery for recurrent tracheoesophageal fistula and anastomotic complications after repair of esophageal atresia in 258 infants. *J Pediatr Surg.* 2015; 50: 250-254.
5. Rothenberg SS. Thoracoscopic repair of esophageal atresia and tracheoesophageal fistula in neonates: evolution of a technique. *J Laparoendosc Adv Surg Tech A.* 2012; 22: 195-199.