

# Atypical or Non typical appendicitis in children Appendicitis in Children. Chronic or Acute? The Role of Ultrasound. A Case Report

Constantinia Boursiani<sup>1</sup>, Georgios Charalampoulos<sup>1</sup>, Themistoklis Boursianis<sup>2</sup>, Ioannis Thanasis<sup>3</sup> and Georgios Karapostolakis<sup>4</sup>

<sup>1</sup>Department of Radiology, Radiologists private practice, P & A. Kyriakou Children Hospital, Greece

<sup>2</sup>Medical physicist Navy Hospital Athens, Greece

<sup>3</sup>gynecologist General Hospital Trikala, Greece

<sup>4</sup>Military Hospital Athens, Greece

## Article Information

Received date: Jun 07, 2017

Accepted date: Jun 27, 2017

Published date: Jul 03, 2017

## \*Corresponding author

Constantinia Boursiani, Department of Radiology, Radiologists private practice, P & A. Kyriakou Children Hospital, Kapodistriou 40a, Trikala Thessaly, 42100, Greece,  
Email: cboursiani@yahoo.com

Distributed under Creative Commons  
CC-BY 4.0

## Abstract

Chronic Appendicitis (CA) is still considered a controversial diagnosis. Although it should be included in the differential diagnosis of recurrent abdominal pain. It was initially reported by Crymble and Forsythe, who defined chronic appendicitis as a condition with one or more mild attacks of appendicitis occurring in a sequence that might include more severe attacks [1]. This definition has mildly changed over the years. In current practice, chronic appendicitis is best defined by clinical course and histological findings as a long-standing inflammation or fibrosis of the appendix that presents clinically as prolonged (> 48 hours) or intermittent abdominal pain. Ultrasound imaging has been widely used (using graded compression technique for appendix visualization) for the diagnosis and follow up of acute appendicitis [2-5]. But there are no definite sonographic criteria for chronic appendicitis. We present the case of a 9, 5-year-old girl with history of recurrent abdominal pain lasting one and a half month with co-existence of mesenteric adenitis, who eventually underwent appendectomy and histopathology revealed acute or chronic appendicitis.

## Case Report

A 9, 5-year-old female (1, 43 m height and 31 Kgs with BMI: ~15, 16) presented with history of intermittent diffuse abdominal pain lasting two weeks. The pain was reported to be continuous and also nocturnal without awakening her up, "6/10" in severity, sometimes sharp in nature, with no specific localization but radiating through the entire abdomen. No aggravating factors were reported. A relieving factor was the evacuation. A typical episode of the aforementioned pain was reported to last for about 2-4 hrs, sometimes associated with nausea, without chills or fever. The patient had about 3-4 episodes per day. Medical history revealed previous admission to emergency department one day after the first episode, and the ultrasound scans performed had no pathologic findings. Blood and urine laboratory studies were also normal. The patient was hospitalized for two days at the pediatric surgery department and treated with intravenous antibiotics and non-steroid anti-inflammatory drugs. Despite the treatment the abdominal pain was not relieved but she was discharged as no organic cause was found. At her presentation to my private practice the abdominal pain was reported to have similar characters as before. According to her mother she had never complained for any abdominal pain at all before. Laboratory tests (mainly inflammatory markers) were again normal. At initial presentation to my private practice the abdomen was soft on palpation with mild tenderness in the right lower quadrant without guarding. Bowel sounds were normal, and no palpable masses were found. A complete ultrasound examination of the abdomen and pelvis was performed using a 1-5MHz sector scan transducer. The bowel and mesentery were examined with a 4-12-MHz linear-array transducer using graded compression technique. Ultrasound examination revealed the presence of enlarged lymph nodes at the mesentery root and both (right and left) iliac fossae. The largest lymph node was located at the right iliac fossa with focal cortical hyperplasia (hypoechoic foci) measuring 1, 42X0, 95 cm with normal flow on Color Doppler. Appendix was depicted with remarkable curves and an anteroposterior diameter of 3mm to 5,7mm. It had normal mural thickness and normal multilamellated sonographic appearance, without periappendical echogenic regions or fluid presence. No evidence of mural hyperemia was found on color Doppler. The ultrasound findings were not indicative of acute appendicitis, with the exception of the presence of enlarged lymph node in the right iliac fossa. Additionally, blood tests for inflammatory markers were normal. The prevailing diagnosis was mesenteric adenitis and more profound in the right abdominal region. As appendicitis could not be definitely excluded the patient was given instructions to repeat the ultrasound examination if the pain aggravates and



Figure 1: The specimen of the excised appendix.

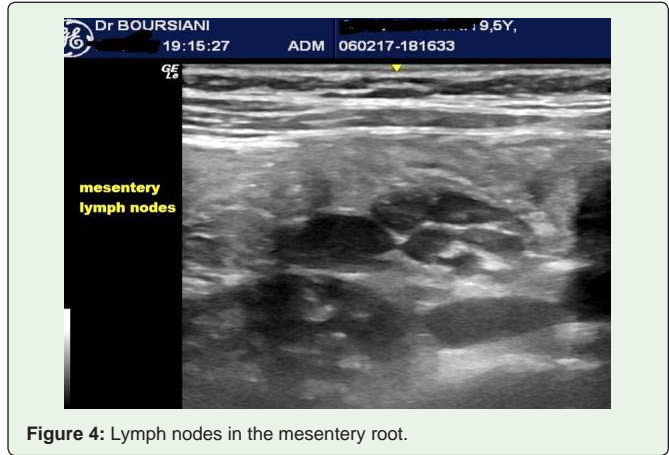


Figure 4: Lymph nodes in the mesentery root.

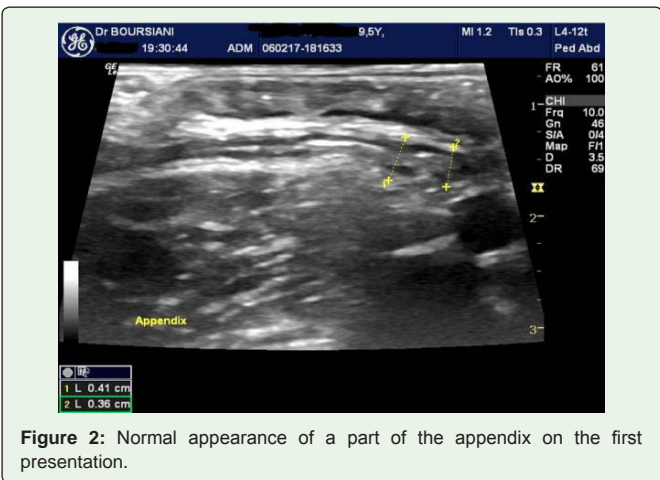


Figure 2: Normal appearance of a part of the appendix on the first presentation.

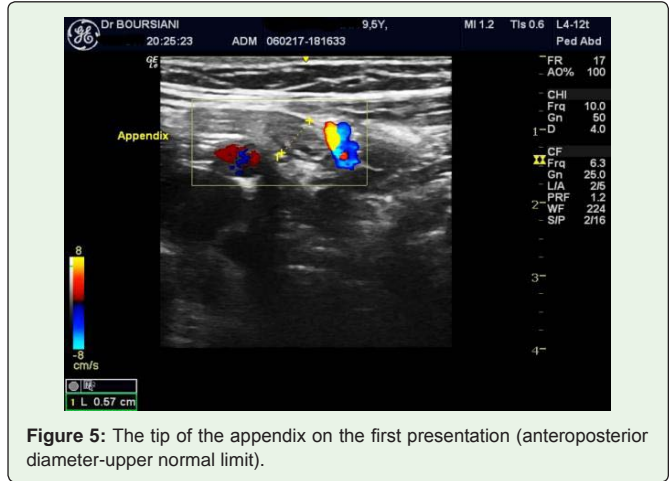


Figure 5: The tip of the appendix on the first presentation (anteroposterior diameter-upper normal limit).

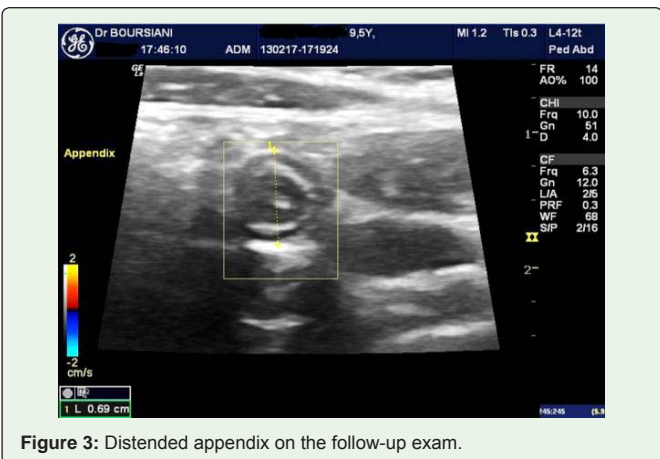


Figure 3: Distended appendix on the follow-up exam.

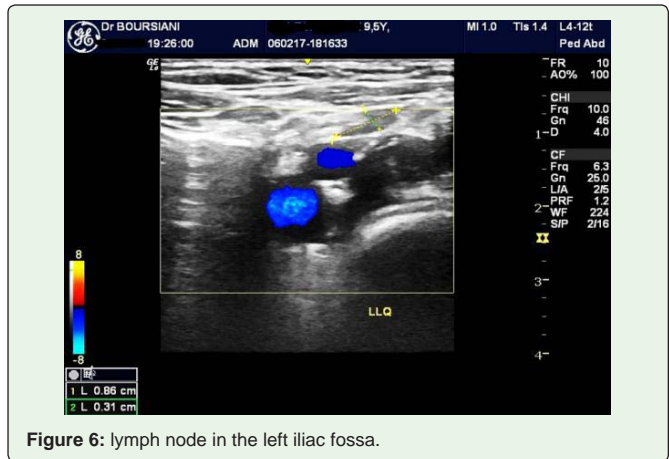


Figure 6: lymph node in the left iliac fossa.

if not to have a follow up ultrasound after 2 weeks, for mesenteric lymph adenopathy reevaluation. In the programmed follow-up examination the patient reported that the pain was almost the same, despite treatment with oral antibiotics and non-steroid anti-inflammatory drugs. Blood and urine tests were repeated and were again normal. Abdominal palpation revealed a slight tenderness at the right lower quadrant. Ultrasound examination revealed further enlargement of the lymph node in the right fossa and increase of

anteroposterior diameter of appendix (5, 7 mm to 6, 9 mm). Because of the moderate worsening of the above sonographic findings that favor appendicitis as a possible diagnosis, surgical evaluation was sought and surgeons from three different Pediatric Surgery Clinics proposed appendectomy. The surgical specimen was 10 cm length and 7 mm thick and pus was found inside the appendiceal lumen. The histological findings suggested chronic inflammation with superimposed signs of acute inflammation without evidence of

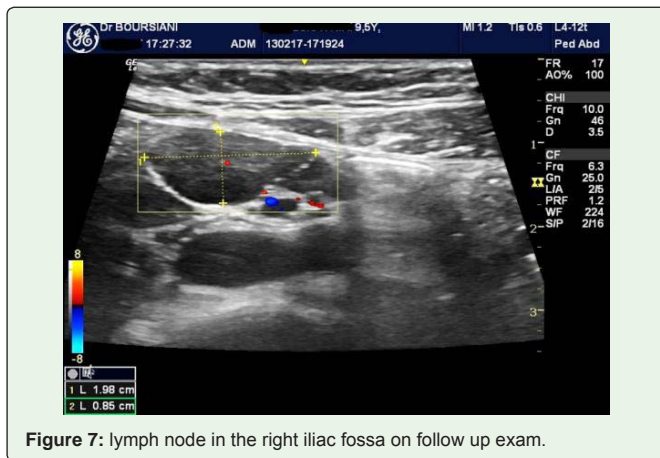


Figure 7: lymph node in the right iliac fossa on follow up exam.

Crohn's disease or malignancy. One month post appendectomy the pain had totally relieved. Three months post appendectomy the patient continues to be symptom-free. In the above case the role of the follow-up sonography was crucial and determined the decision to perform appendectomy (Figures 1-7).

## Discussion

### Clinical signs

In our case the patient had a prolonged subclinical course of appendicitis which never had typical symptoms of acute inflammation but it was a stable condition of inconvenience. The main and almost only symptom was recurrent abdominal pain. Abdominal pain in childhood is a very frequent symptom but the prevalence of recurrent abdominal pain in a population of schoolchildren was 10%, in Apley's original study [6,7]. In subsequent studies using his criteria the prevalence ranged from 11% to 45%. The width of this range is probably attributable to differences in age, geographical area and social factors and methodology. Not all the children with recurrent abdominal pain attend to a doctor and only when the pain impacts on the functioning of the child then medical help is sought [8].

### Pathophysiology

Chronic appendicitis occurs secondary to partial but persistent obstruction of the appendiceal lumen. The causes of intermittent or partial appendiceal obstruction include fecalith, tumors, lymphoid hyperplasia, foreign bodies, and appendiceal folding [9,10].

### Definition

Chronic appendicitis was first described in 1949 by Crymble and Forsythe and it is characterized by atypical recurrent abdominal pain, more often located in the right lower quadrant [1]. Because of its atypical clinical signs and course it is often misdiagnosed, especially in children. In our case the pain was never localized in right iliac fossa probably because of the fact that appendix was nearly 10 cm long and its tip was located in a higher level and more central than usual.

Over the years the definition of chronic appendicitis had only slightly changed and today is best defined as a long-standing inflammation or fibrosis of the appendix that presents clinically as prolonged (> 48 hours) or intermittent abdominal pain [11-14]. although there is a contemporary debate about the definition and

workup of this condition, histological findings can prove its existence except of the atypical clinical course [15]. It is reasonable by the definition of inflammation that if acute inflammation persists then chronic one will ensue.

### Incidence

A recent study conducted at the Theodor Bilharz Research Institute [16] includes retrospective analysis of the histopathological findings of 251 appendectomies specimens. The 251 appendectomies were performed after a diagnosis of acute appendicitis was made preoperatively. According to histopathology acute appendicitis was found in 135 patients (rate 54%), (acute on top of chronic appendicitis in 75 (rate 29%) and chronic appendicitis in 33 (rate 13%). Diagnosis was histologically proven in 243 cases; with negative appendectomy rate of 3.2%. Stroh et al [17], determined a 35% chronic appendicitis rate diagnosed histopathologically in their laparotomy series performed with the indication of abdominal pain, which is in accordance with the above study. But in another literature review [18], authors suggest that recurrent and chronic appendicitis are distinct disease processes from acute appendicitis, and occur with an incidence of approximately 10 per cent and 1 per cent, respectively.

### Ultrasound imaging

In our case the main sonographic finding at the initial presentation was the asymmetrically enlarged lymph node in the right lower quadrant. Besides its size, this lymph node had hypoechoic foci in its cortex. The other doubtful finding was the variable anteroposterior diameter of the appendix due to segmental inflammation. The appendix' s length was 10 cm. It is very difficult in ultrasonography to visualize the entire length of the appendix although inflammation facilitates appendix visualization. Follow-up sonogram after two weeks provided the evidence to reach the diagnosis of CA. In the comparison of the two examinations there was an aggravation of the imaging findings, although the patient was under medication with oral antibiotics and non steroid anti-inflammatory drugs. The subclinical course of appendicitis was attributed to the medication (oral antibiotics and non steroid anti-inflammatory drugs for two weeks), but the pain was not relieved. Histopathology revealed acute or chronic appendicitis. There are no formal diagnostic imaging criteria, or management algorithm of chronic appendicitis. In our case as limited sonographic findings of acute appendicitis existed it was challenging to reach a diagnosis of chronic appendicitis with ultrasonography. A typical finding is the loss of signature gut appearance of appendix's wall, if it is possible to visualize the entire length of the appendix. In our case we hadn't detected this finding. Shah et al [12]. present a case of chronic appendicitis that underwent CT examination. The CT-finding was an enlarged appendix with anteroposterior diameter of 10 mm. Consequently doing the correlation with ultrasonography another imaging finding was the distended lumen of appendix. Additionally another one is the presence of echogenic regions in locoregional fat. Edema and infiltration of inflammatory cells tend to increase the echogenicity of fat [10]. But further studies with large number of patients are needed to establish sonographic criteria for chronic appendicitis. In our case mild sonographic findings of acute appendicitis existed but could not be sufficient for reaching a diagnosis since blood tests for inflammation were normal and abdomen was soft on palpation. In the follow-up sonogram the main reason to support surgical treatment



was the aggravation of sonographic findings. Ultrasonography for abdominal pain evaluation in children has a great diagnostic value as it is easier to perform due to their smaller body. We can describe the sonographic principles for visualization of normal appendix and do the differential diagnosis of the abnormal as follows: [4,10].

1. Appendix has a typical multilamellated sonographic appearance, arising from its organized and highly stratified histology. It is compressible with no peristalsis. It has sharp and definite limits. Its anteroposterior diameter is up to 6mm. (according to some authors the upper limit is 7 mm). Its mural thickness is up to 3 mm
2. Mesenteric and omental fat are generally inconspicuous except when inflamed, so they appear echogenic.
3. In color Doppler hyperemia of both wall and adjacent mesentery can be evaluated. This is a notable marker of disease activity in inflammatory disease.
4. Real-time imaging is a unique strength of ultrasound, with direct performance of scanning in complicated cases, where supplementary evaluation of bowel's motility, compressibility after eating and drinking in a dynamic view can be assessed, focusing on the area of clinical concern.
5. Combination of convex, linear and transvaginal sector to collect as more information as possible.

## Conclusion

The role of ultrasound and the follow-up was determinant to reach the diagnosis of appendicitis in our case. The histological analysis revealed chronic inflammation with superimposed signs of acute inflammation. Ultrasound imaging for detecting acute appendicitis in children has an established value. The entity of chronic appendicitis although is still doubtful does exist and its sonographic appearance warrants further study so as to establish a management algorithm and diagnostic imaging criteria not only on ultrasonography but also on other imaging modalities of chronic and recurrent appendicitis.

## References

1. Crymble PT, Forsythe I. Chronic appendicitis in children. *Ulster Med J* 1949; 18:153-72.
2. Acute appendicitis: US evaluation using graded compression. *Puylaert JBCM*. 1986;158: 355-360.
3. Abu-Yousef MM, Bleichaer JJ, Maher JW, Urdaneta LF, Franken EA Jr, Metcalf AM et al. High resolution sonography of acute appendicitis. *AJR* 1987; 149: 53-58.
4. Rioux M. Sonographic detection of the normal and abnormal appendix. *American Journal of Roentgenology*. 1992; 158: 773-778.
5. Rosemary E. Schmidt, Diane S. Babcock, Michael K. Farrell. Use of Abdominal and Pelvic Ultrasound in the Evaluation of Chronic Abdominal Pain *Clinical Pediatrics*.1993.
6. Apley J, Naish N. Recurrent abdominal pain: A field survey of 1000 school children. *Arch Dis Child*. 1958; 33: 165-170.
7. Plunkett A. Beattie R M. Recurrent abdominal pain in childhood. *J R Soc Med*. 2005; 98: 101-106.
8. Van Winter JT, Wilkinson JM, Goerss MW, Davis PM. Chronic appendicitis: does it exist? *J Fam Pract* 1998; 46: 507-509.
9. Jiten P. Kothadia, Seymour Katz, Lev Ginzburg. Chronic appendicitis: uncommon cause of chronic abdominal pain. *Therap Adv Gastroenterol*. 2015; 8: 160-162.
10. Katherine E. Maturen, Ashish PW, Aya Kamaya, Jonathan R. Dillman, Ravi K. Kaza, Amit Pandya, et al. Ultrasound Imaging of Bowel Pathology: Technique and Keys to Diagnosis in the Acute Abdomen. *AJR*. 2011; 197:1067-1075.
11. David Kim, Sonia A. Butterworth, Ran D. Goldman. Chronic appendicitis in children. *Can Fam Physician*. 2016; 62: 304-305.
12. Shah SS, Gaffney RR, Dykes TM, Goldstein JP. Chronic appendicitis: an often forgotten cause of recurrent abdominal pain. *Am J Med*. 2013; 126: 7-8.
13. Mussack T, Schmidbauer S, Nerlich A, Schmidt W, Hallfeldt KK. Chronic appendicitis as an independent clinical entity. *Chirurg* 2002; 73: 710-715.
14. Mattei P, Sola JE, Yeo CJ. Chronic and recurrent appendicitis are uncommon entities often misdiagnosed. *J Am Col ISurg*. 1994; 178: 385-389.
15. Sarah Beck. DVM Acute and chronic inflammation.
16. HMohamed, Saied Hedy, Magid Mahmoud Nasr, Hussein Ezzat, et al. Histopathological findings of appendectomy: A retrospective clinicopathological analysis. *J. Egypt .Soc. Parasitol*. 2012; 42: 157-164.
17. Stroh C, Rauch J, Schramm H. Is there a chronic appendicitis in childhood? Analysis of pediatric surgical patients from 1993-1997 *ZentralblChir* 1999; 124:1098-102.
18. Hawes AS, Whalen GF. Recurrent and chronic appendicitis: the other inflammatory conditions of the appendix. *Am Surg*. 1994; 60: 217-219.